

# Open Carpal Tunnel Release

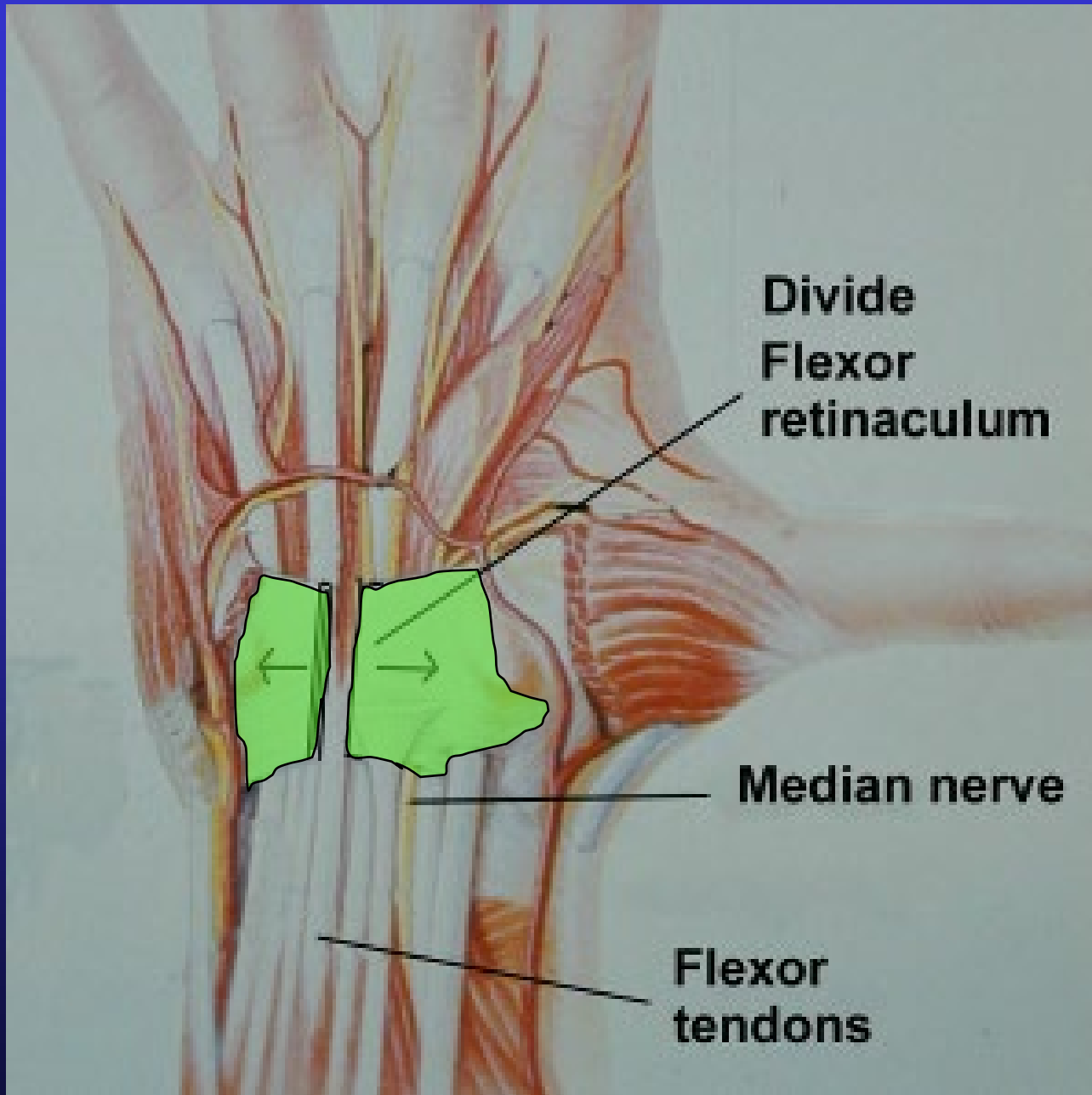
## Dr Stuart Myers

KAREENA  
PRIVATE HOSPITAL

Orthopaedic Hand Surgeon,  
Sydney Orthopaedic Specialists

[www.myhand.com.au](http://www.myhand.com.au)



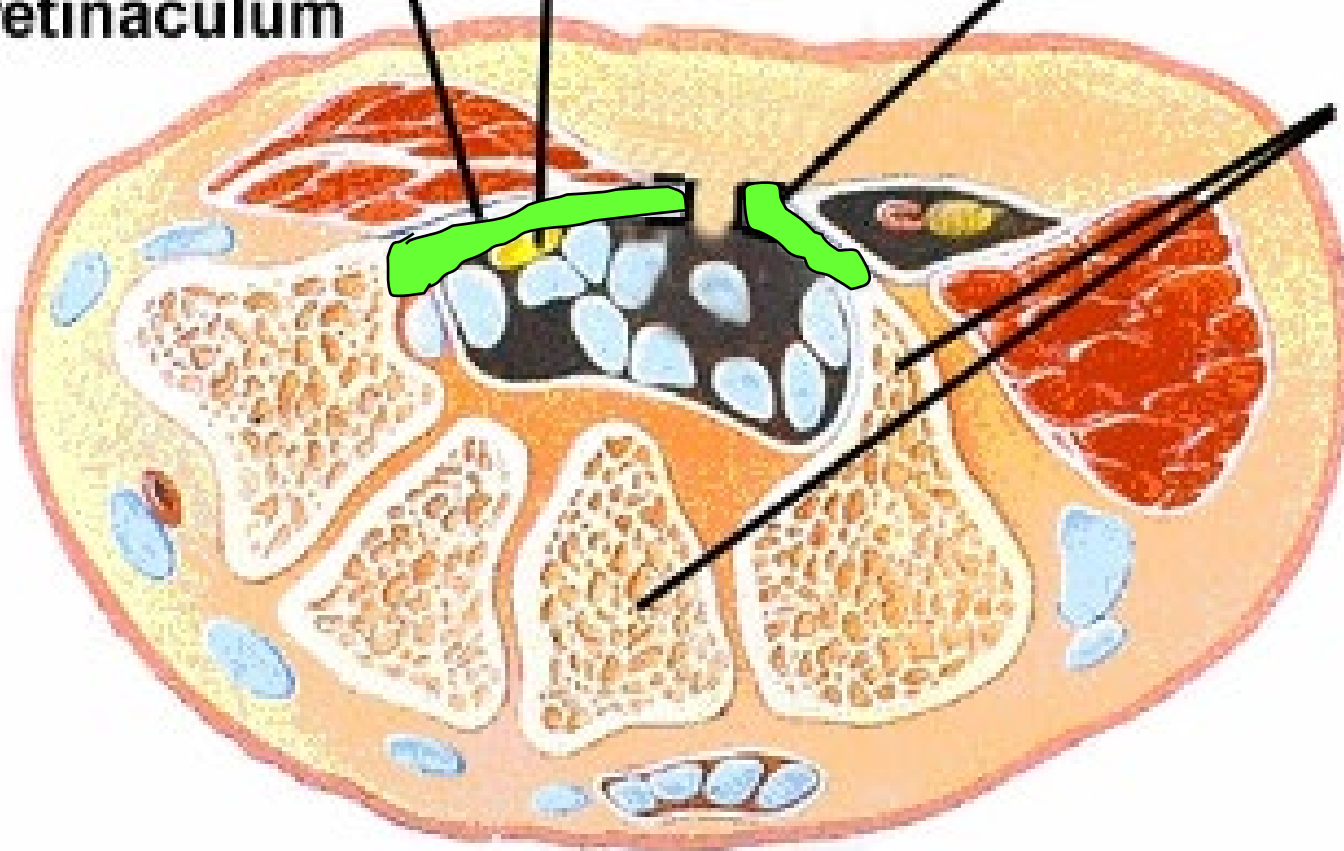


**Median  
nerve**

**Surgery**

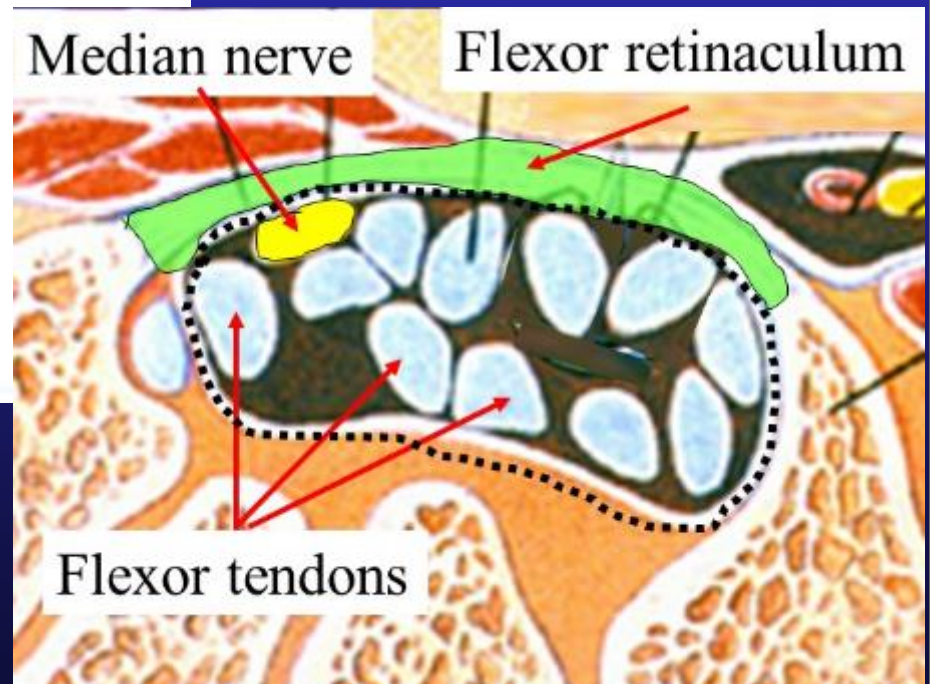
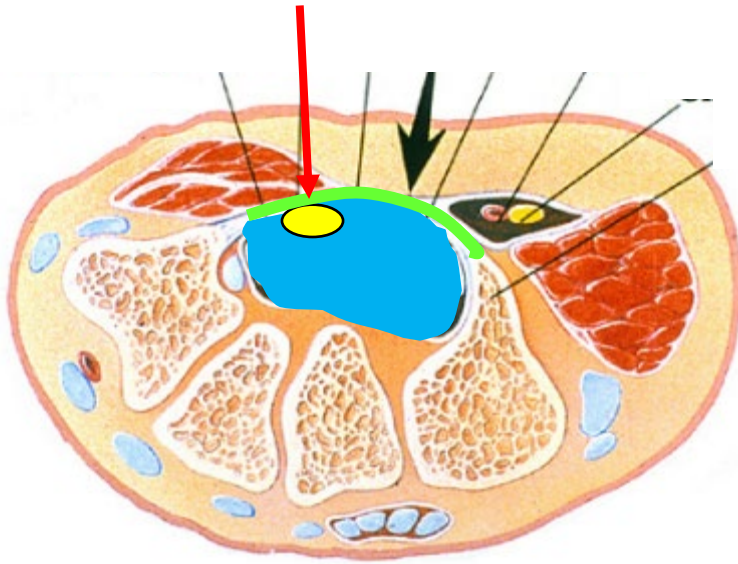
**Flexor  
retinaculum**

**Carpal  
bones**




# Carpal Tunnel

## Median Nerve



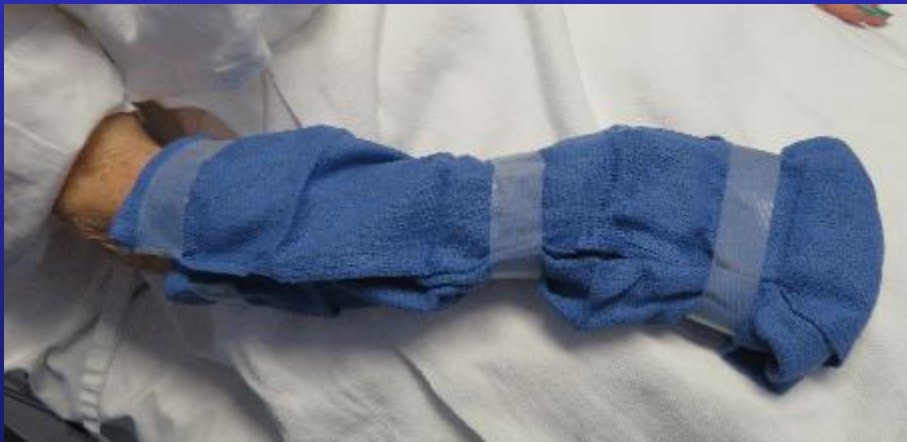# Indications for Open CTR

- Severe Carpal Tunnel symptoms failing other treatments
- $< 45^*$  Wrist Dorsiflexion
- Need for synovial biopsy or exploration of carpal tunnel
- Eg Ganglion, Synovectomy



“Dorsiflexion”

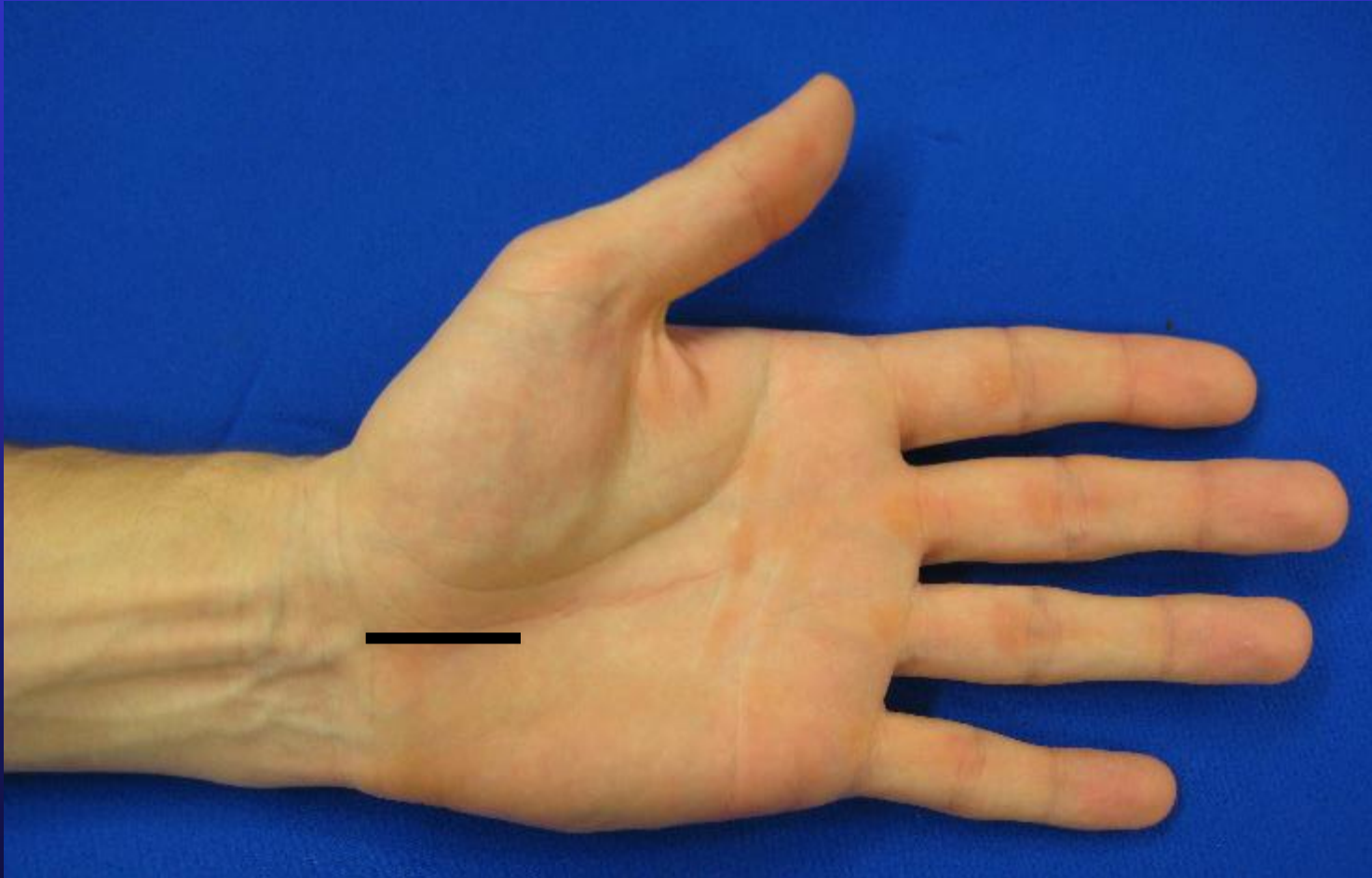
# Skin Preparation



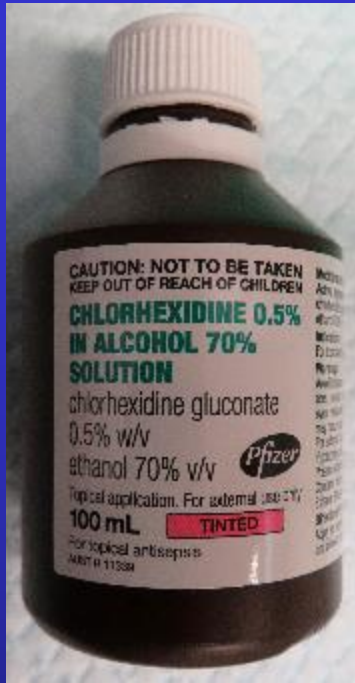
- Wash hands and clean under nails before coming to hospital
- Skin is cleaned on admission to hospital & wrapped in clean cloth



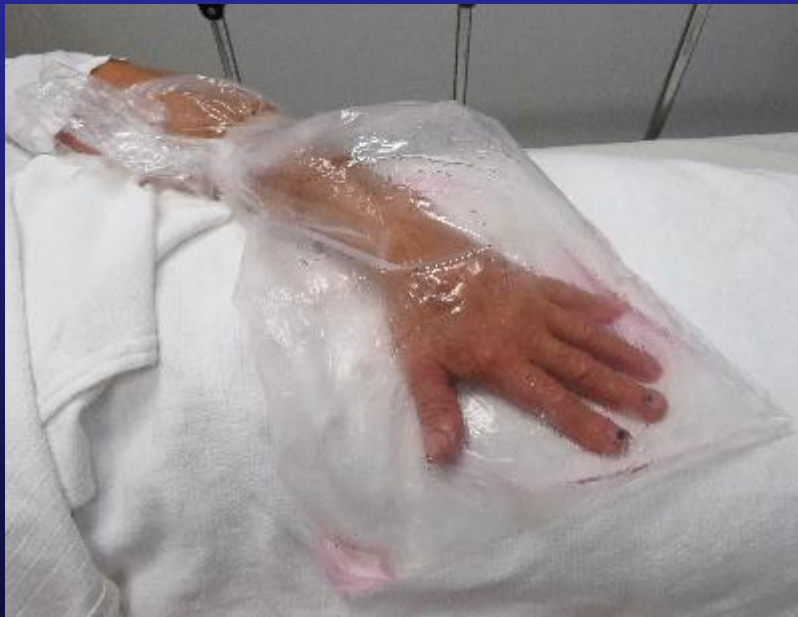# Skin marked



# Skin Preparation

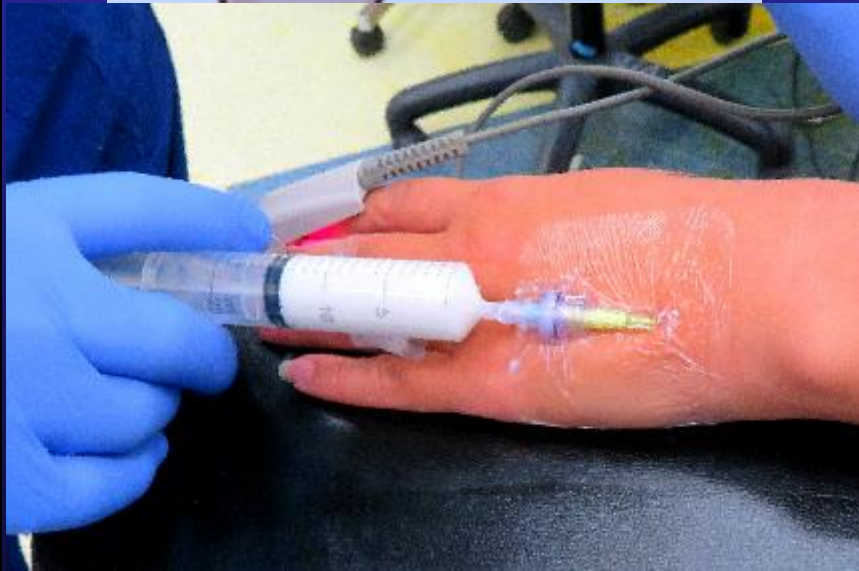
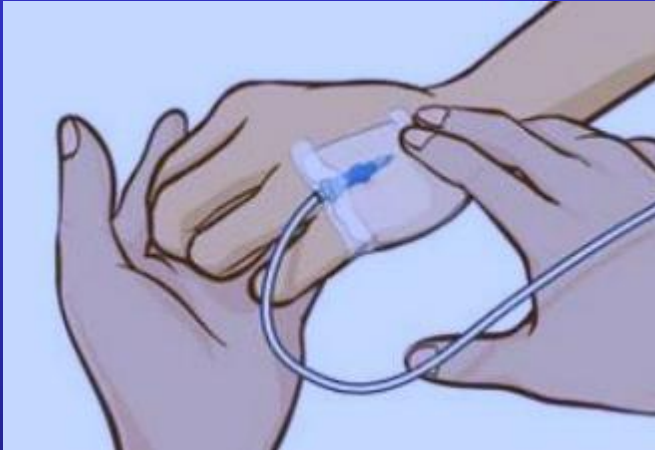
- Hand is marked
- Consent is checked
- Hand is placed in Alcohol based skin prep
- This is drying to the skin



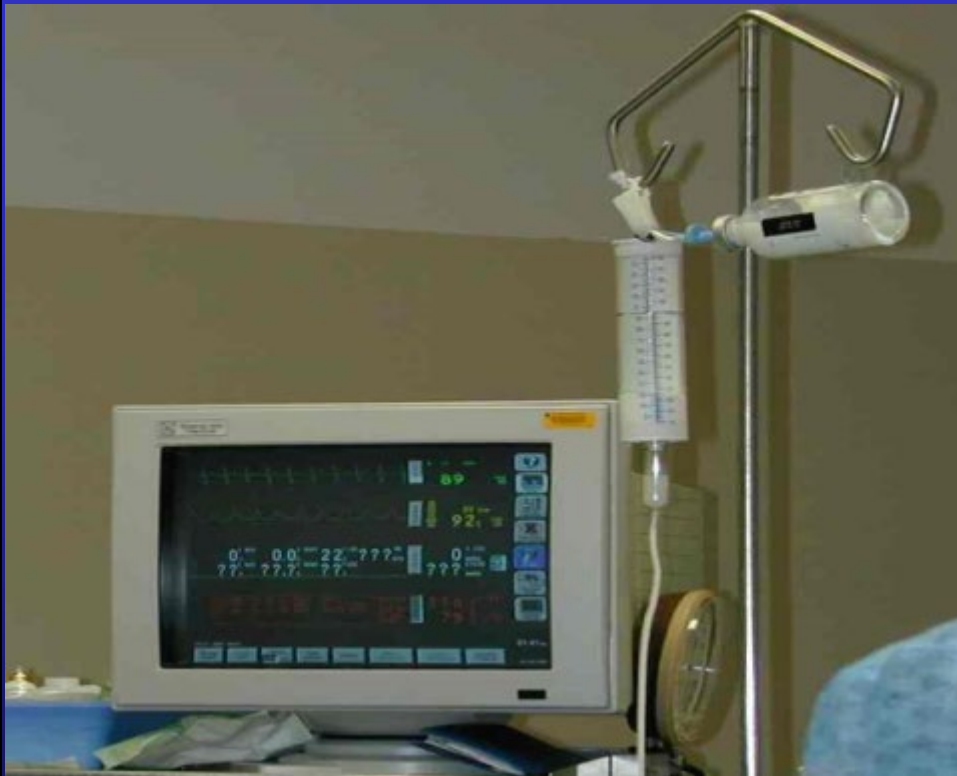

# Sedation or GA



- A small IV Canula is inserted by the Anaesthetist to administer the Sedation
- Most patients do not remember the procedure at all

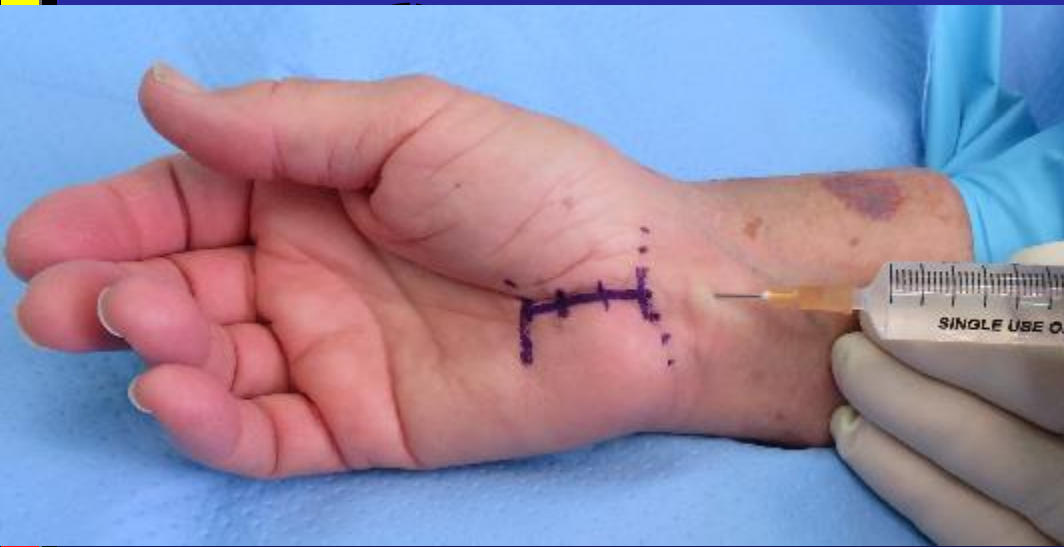# Sedation & Local Anaesthetic



- You will be very drowsy so that the Local anesthetic injections are painfree
- You will be waking by the end of the procedure

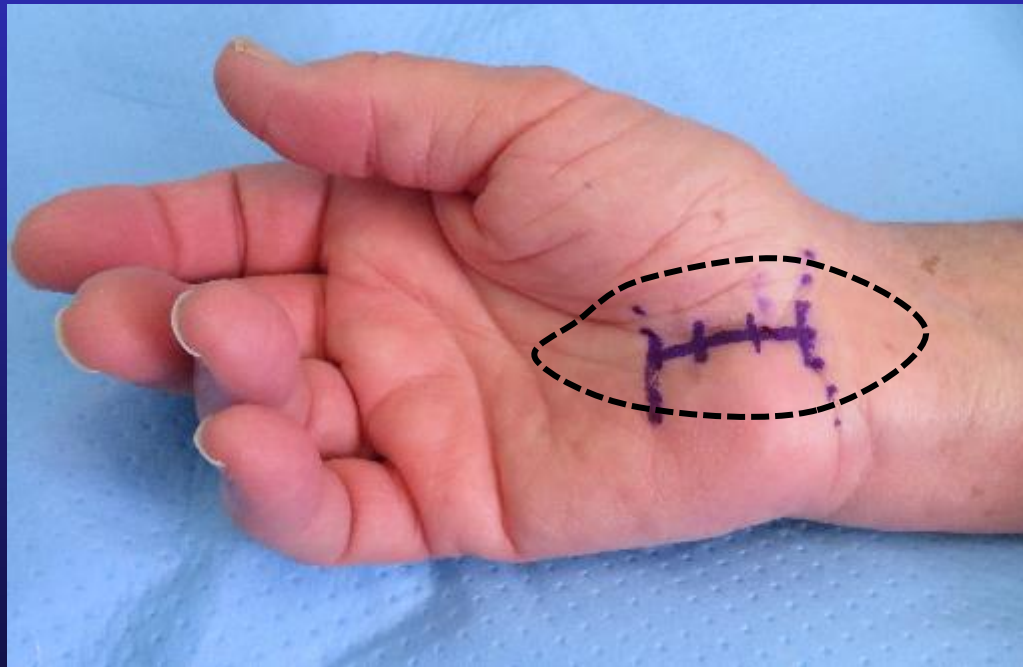
# Local anaesthetic

- 5 mls Lignocaine 2% with Adrenalin superficial to deep fascia



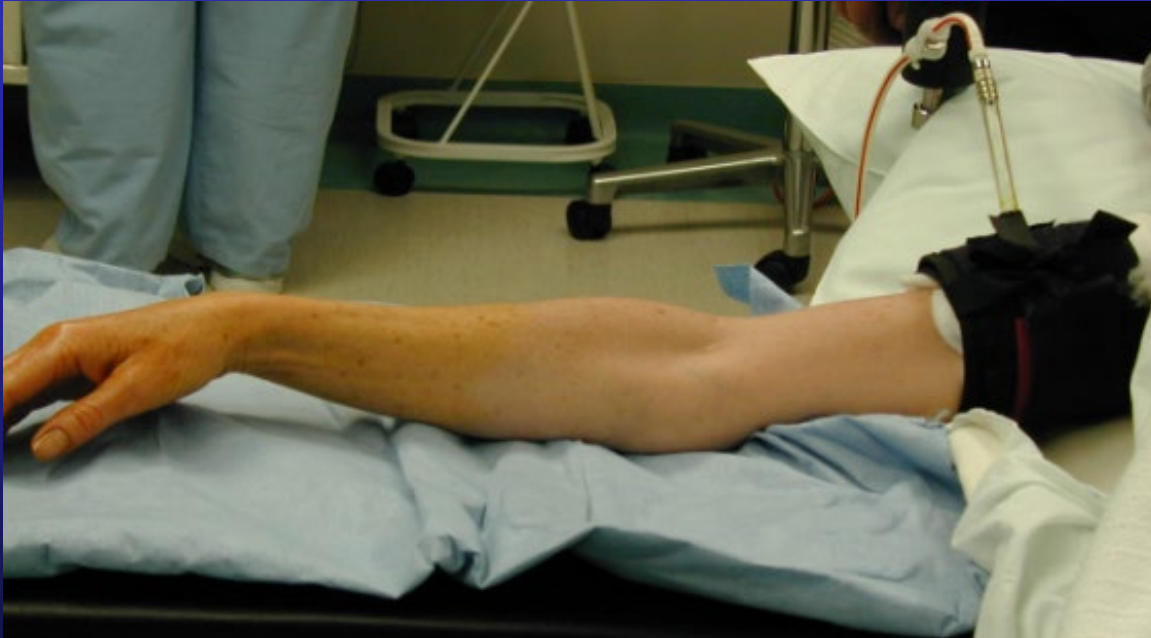2<sup>nd</sup> injection in palm

# Local anaesthetic



- Local infiltration of local Anaesthetic with Adrenaline
- Note blanching of skin from Adrenaline

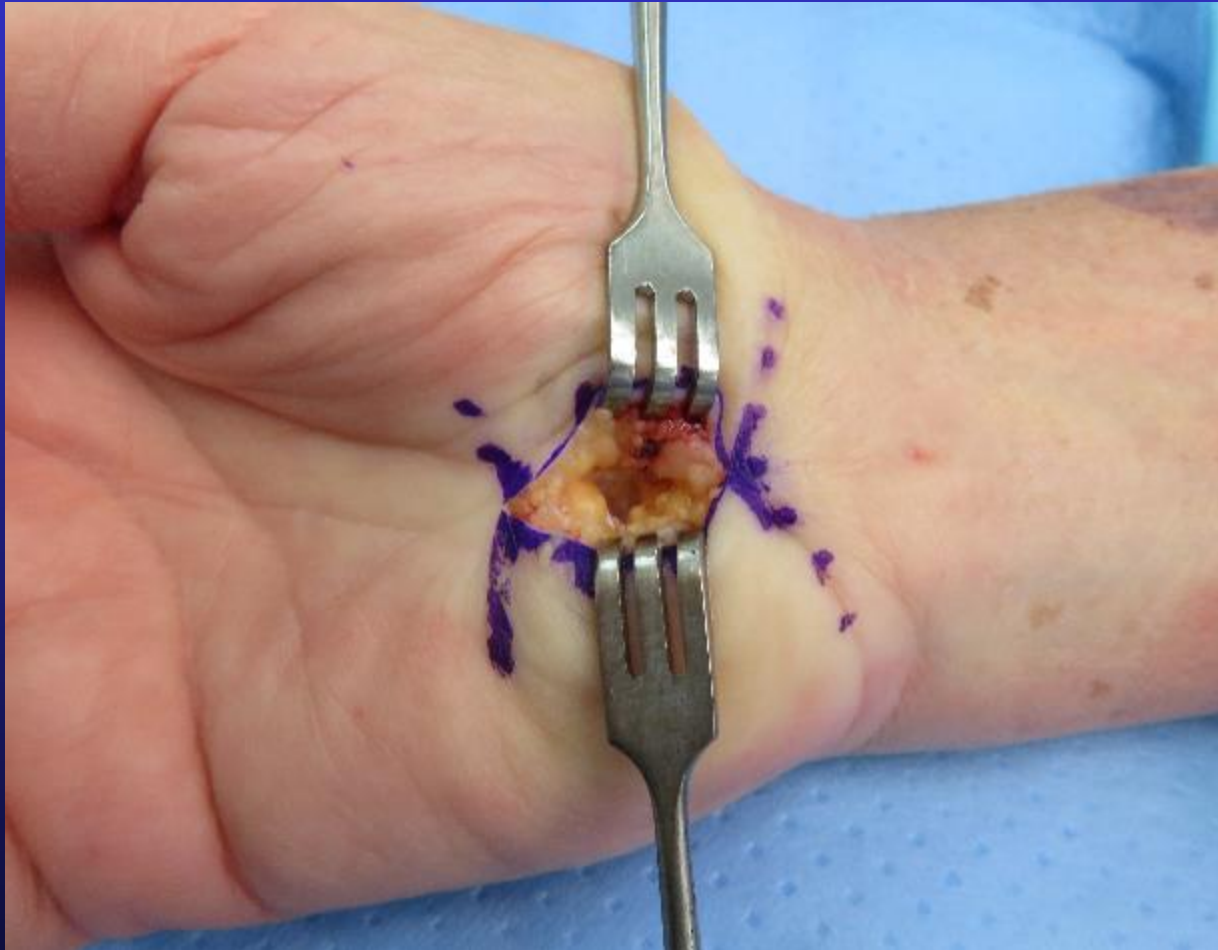# Tourniquet



- No bleeding during procedure
- Inflated during procedure

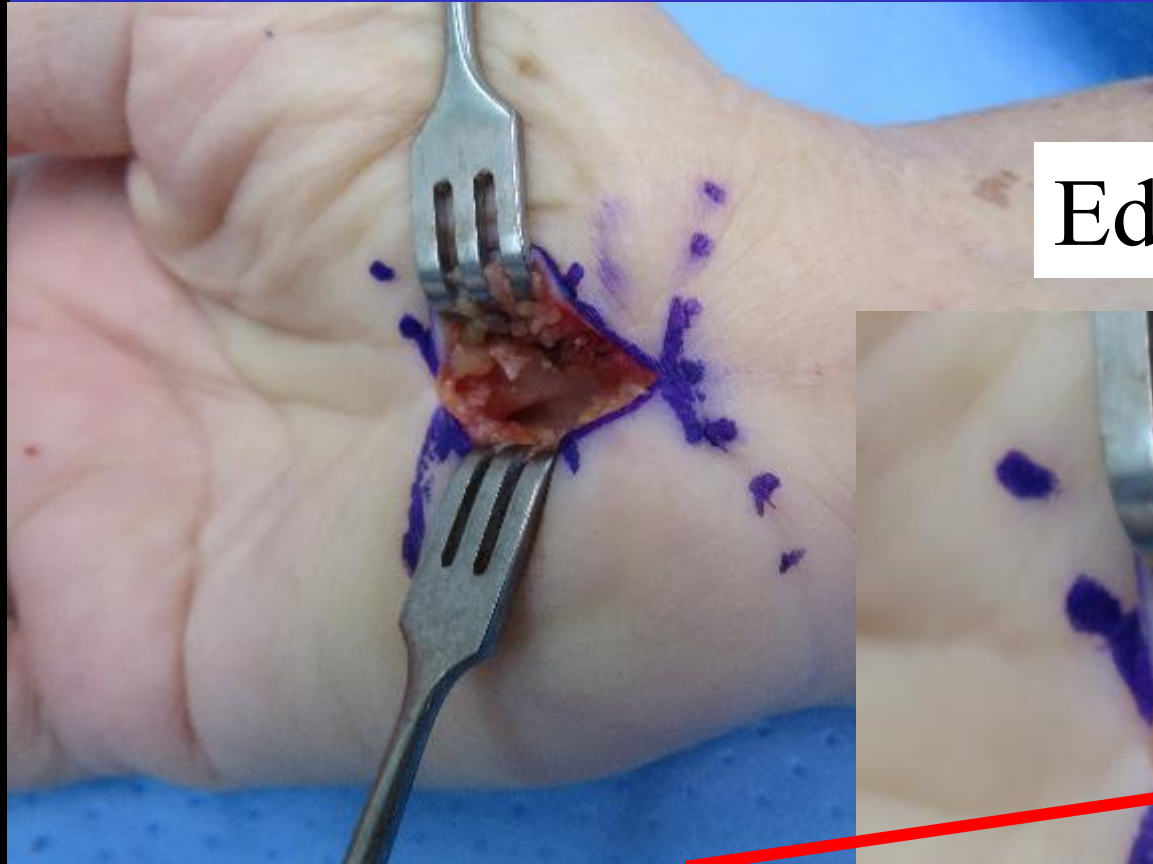


# Skin incision

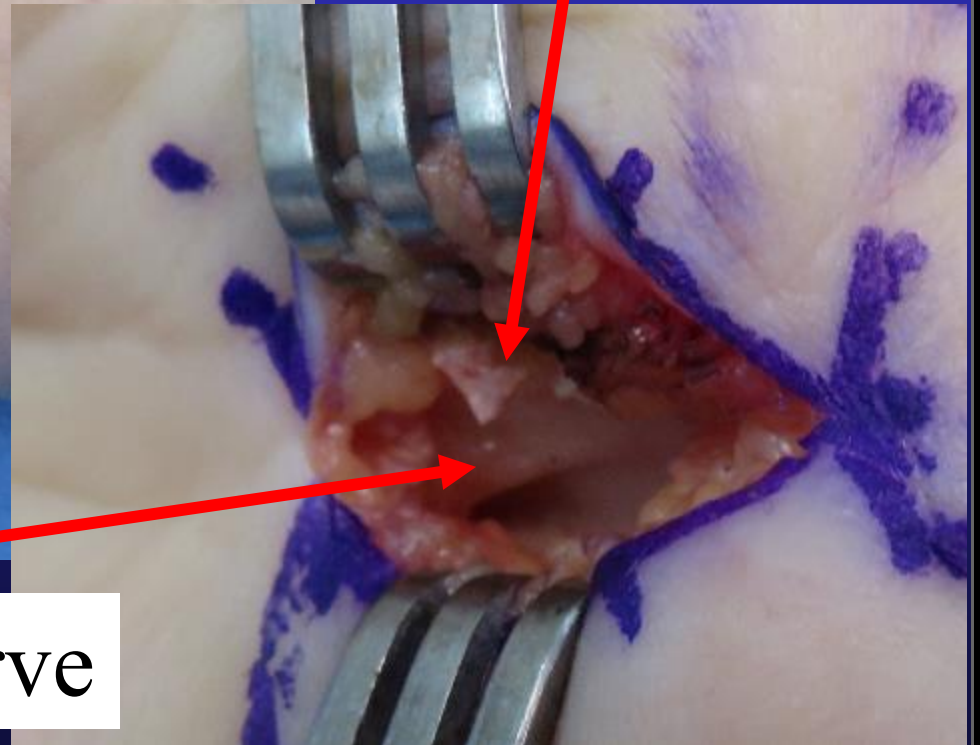




# Retinaculum divided

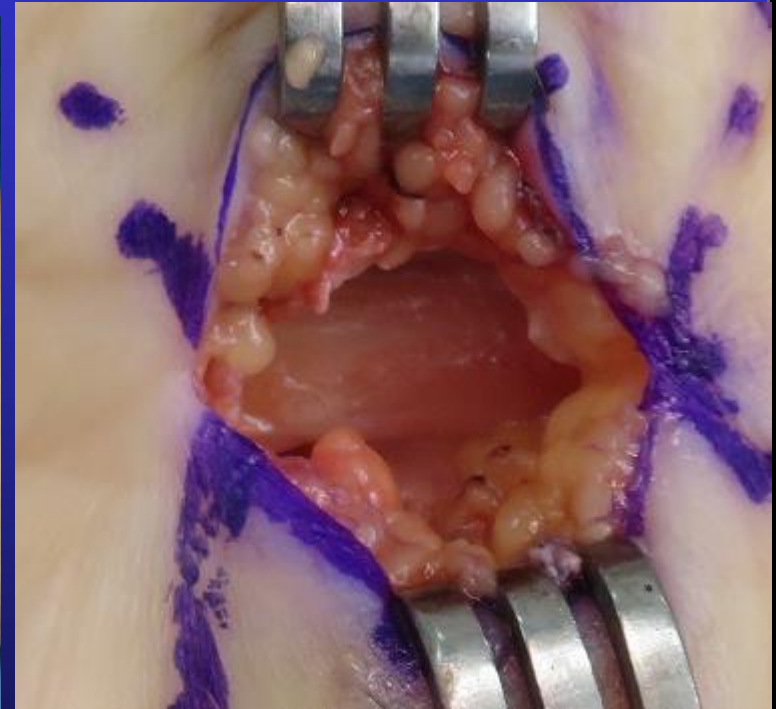
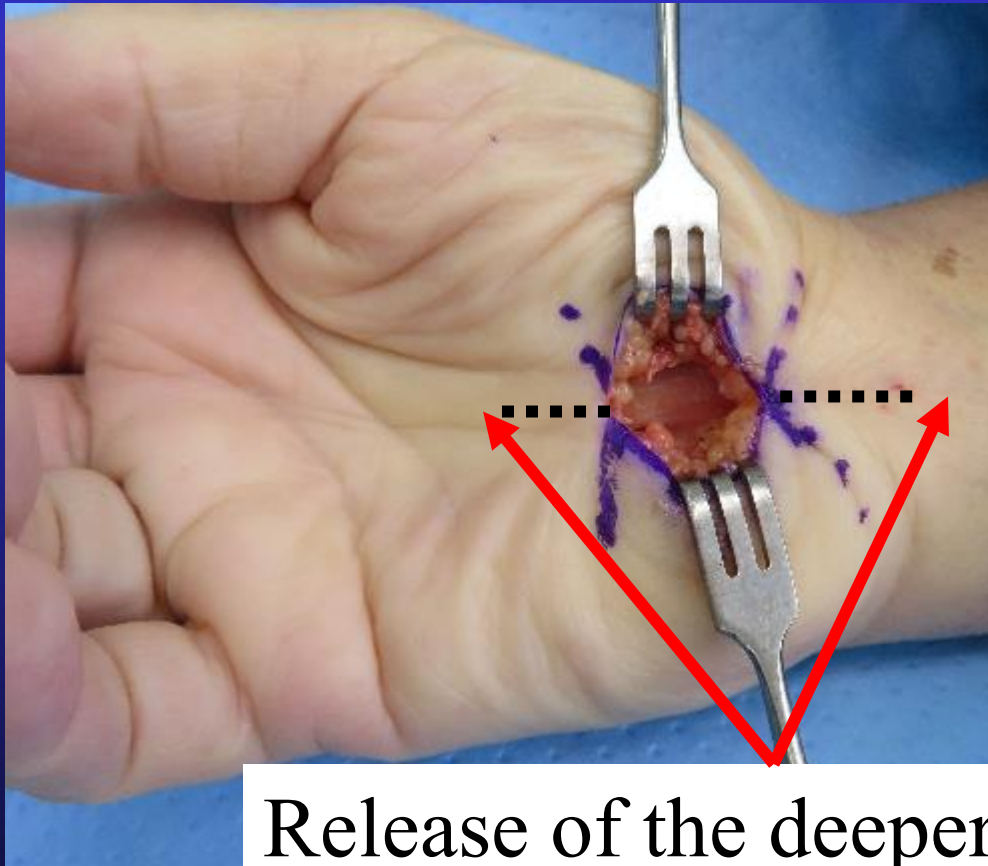


Edge Retinaculum



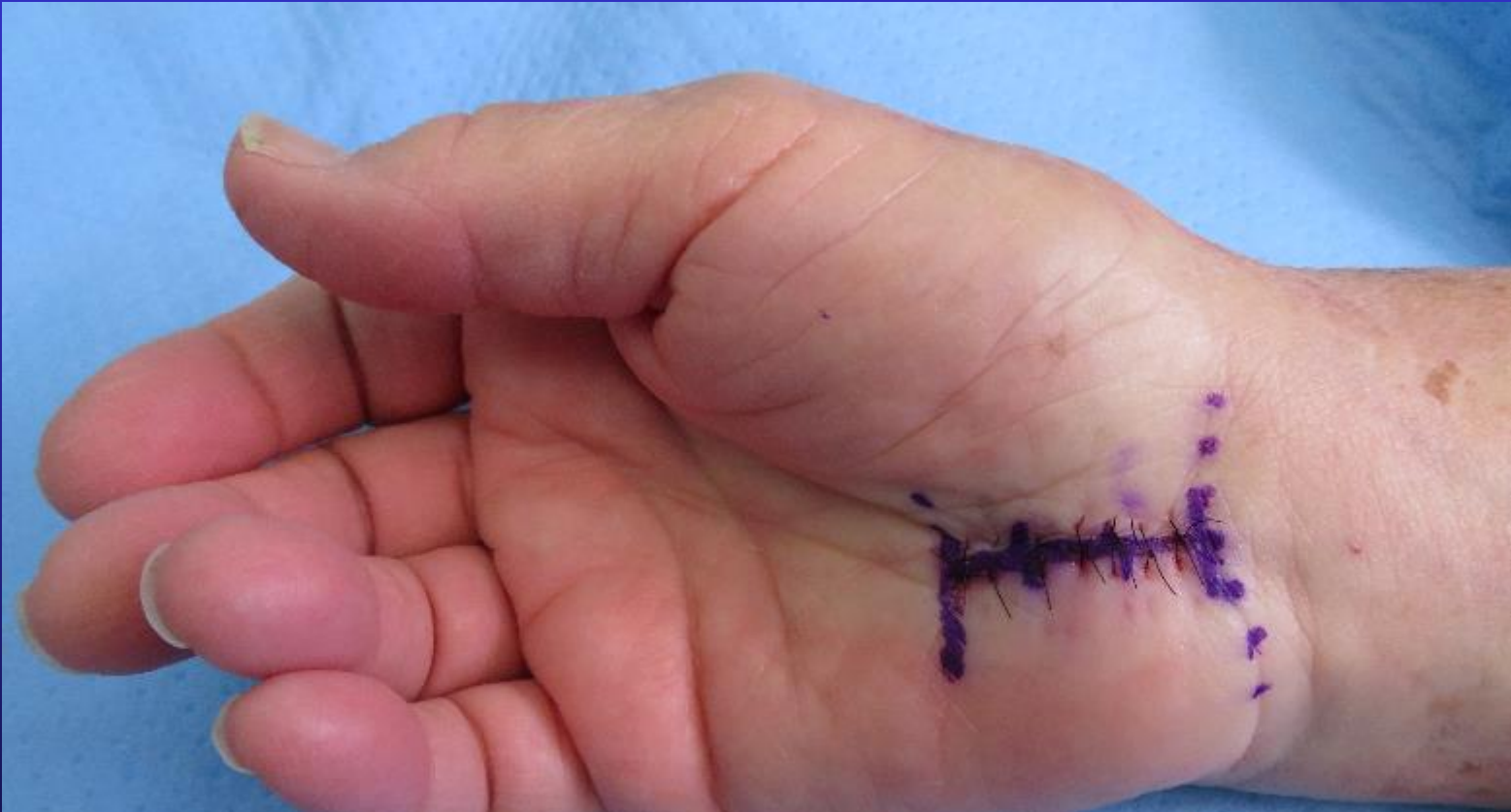Median Nerve

# Extent of Release



Release of the deeper tissues extends much further than the incision

# Sutures 50 Nylon



“50 Nylon” refers to the Gauge of the suture  
– not the number of sutures



# Crepe bandage for 2 days

