

Excision Dorsal Wrist Ganglion

Dr Stuart Myers

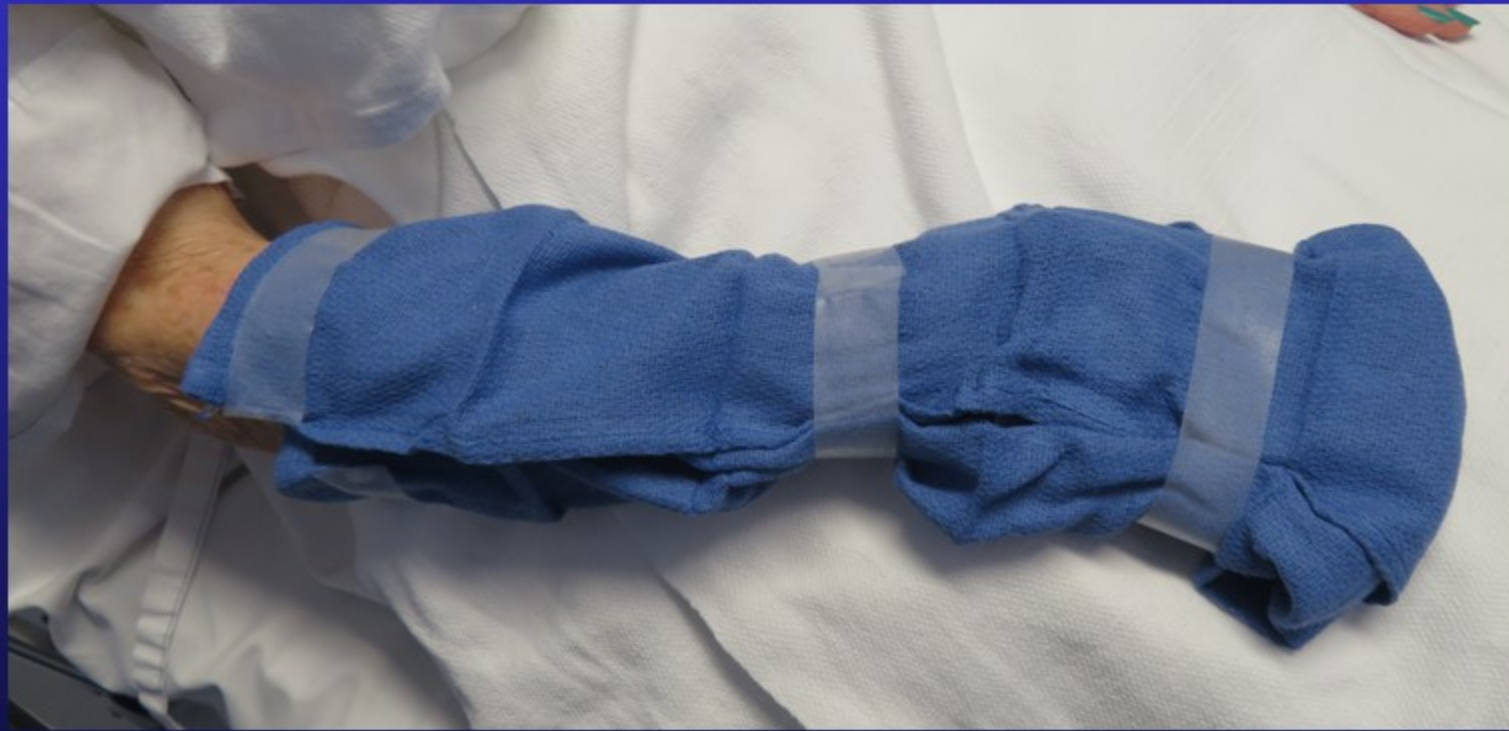Orthopaedic Hand Surgeon,
Sydney Orthopaedic Specialists

www.myhand.com.au



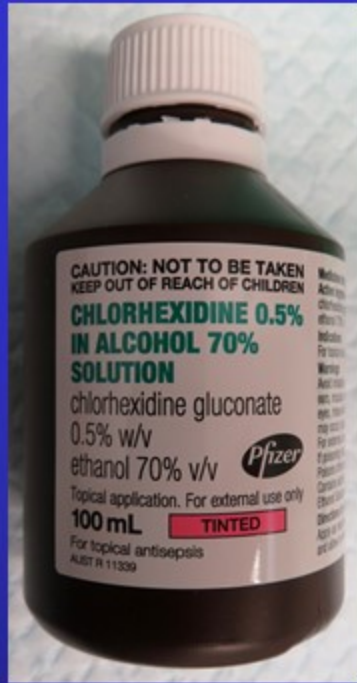
Skin Preparation

Wash hands and clean under nails before coming to hospital

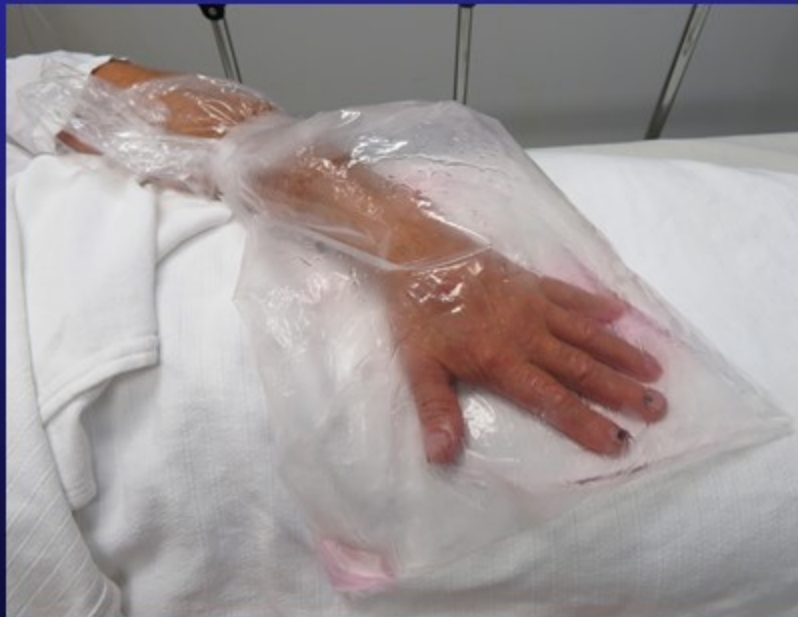

Skin is cleaned on admission & wrapped in clean cloth

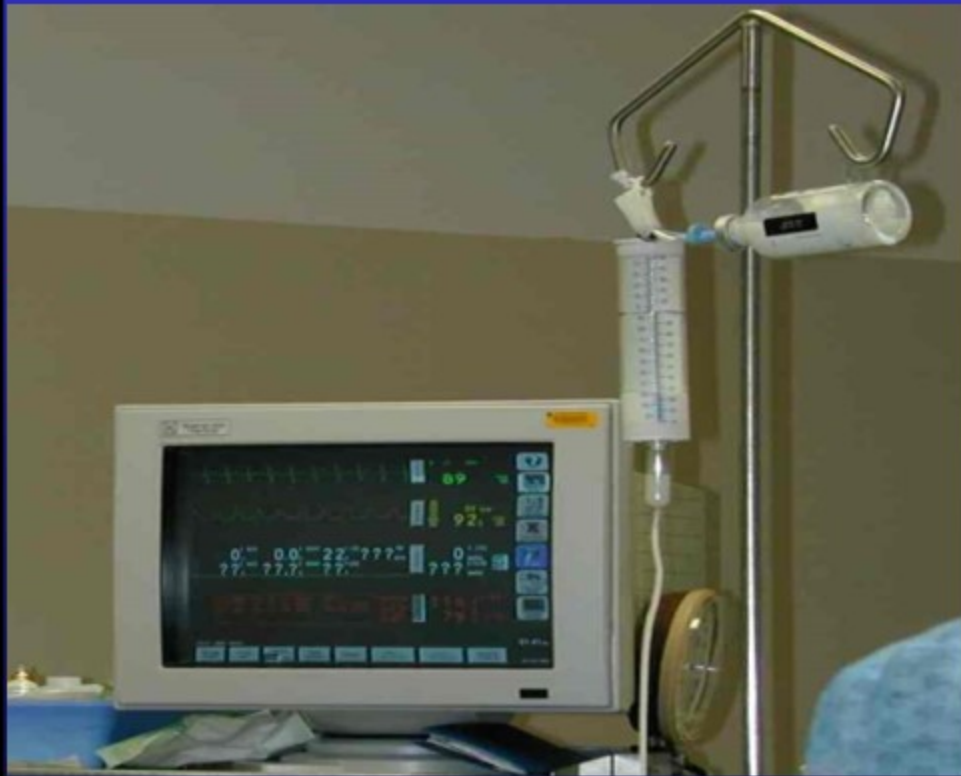Skin Preparation



- Hand is marked
- Consent is checked
- Hand is placed in Alcohol based skin prep
- This is drying to the skin

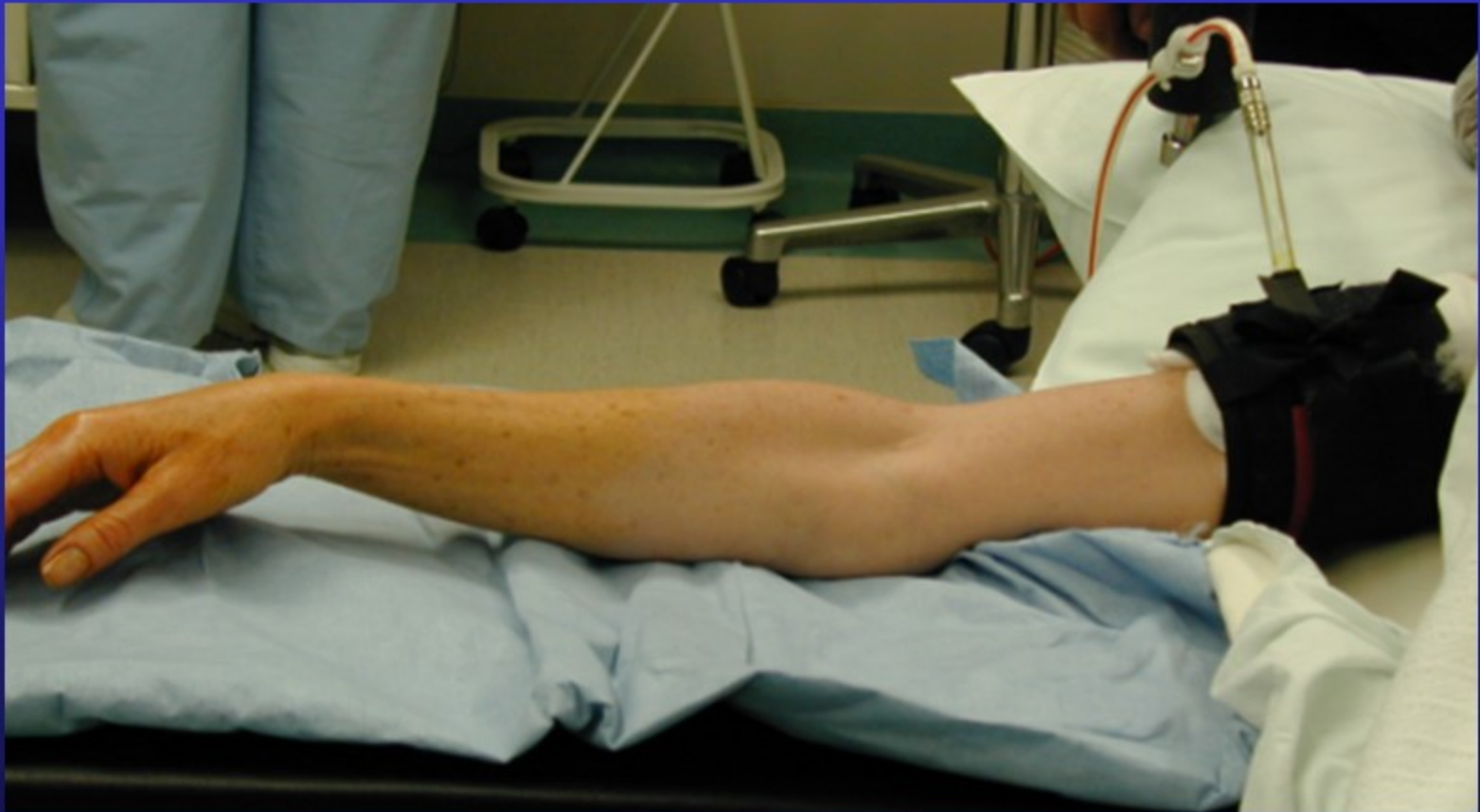

General Anaesthetic

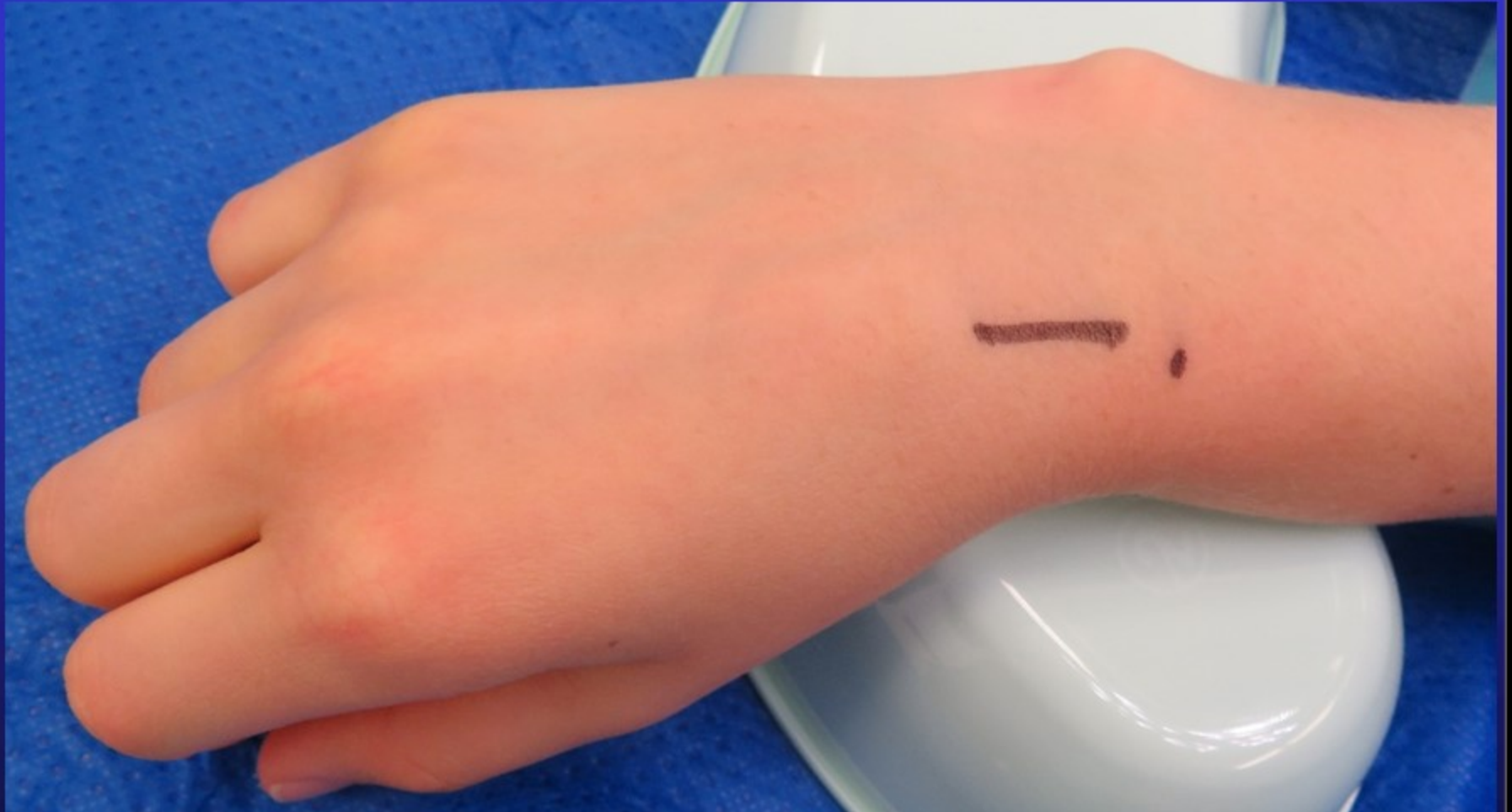


- The anaesthetist also inserts local anesthetic blocks in the forearm to reduce pain post surgery

Tourniquet



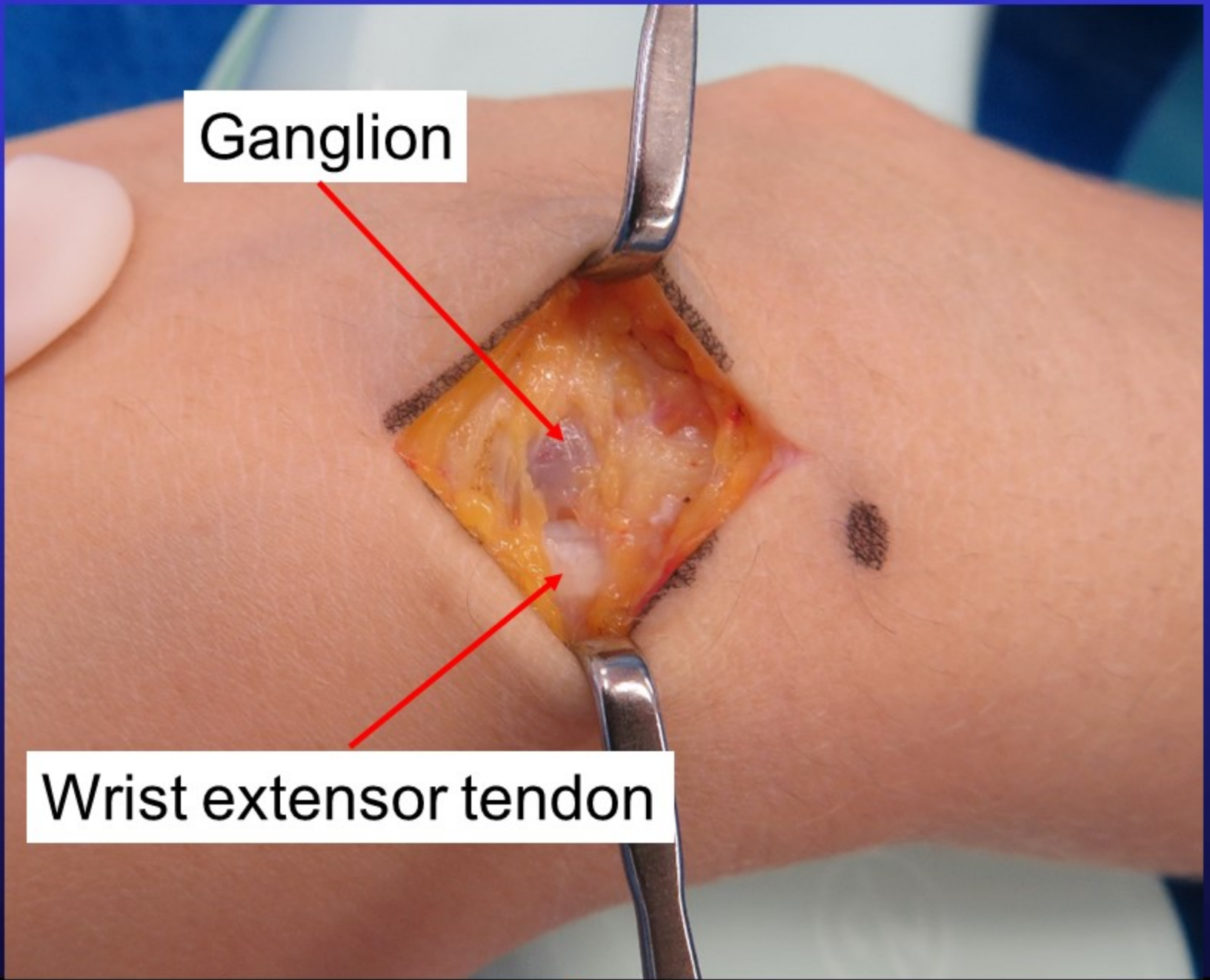
No bleeding during procedure



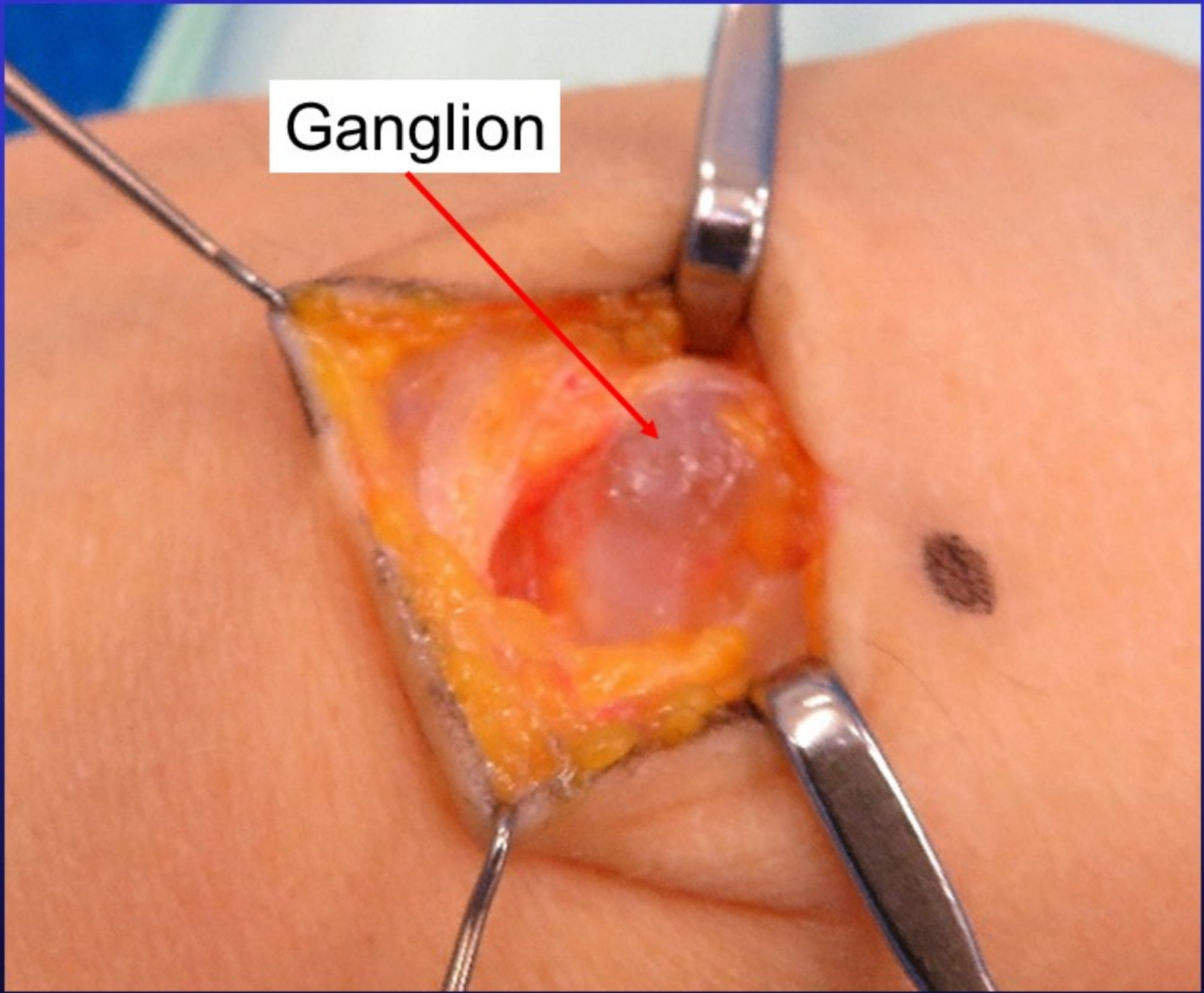
Skin incision marked before surgery

Ganglion

Wrist extensor tendon

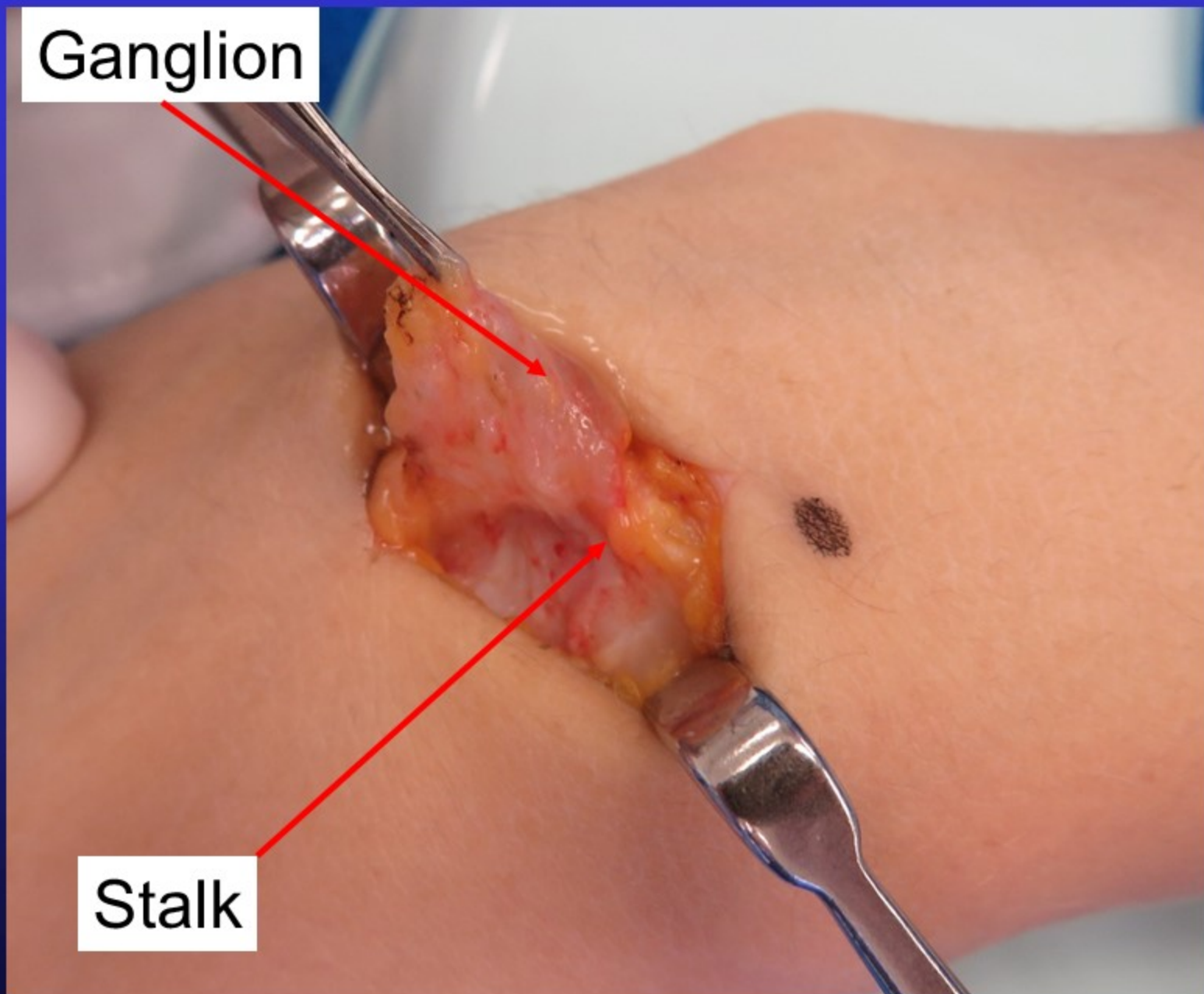


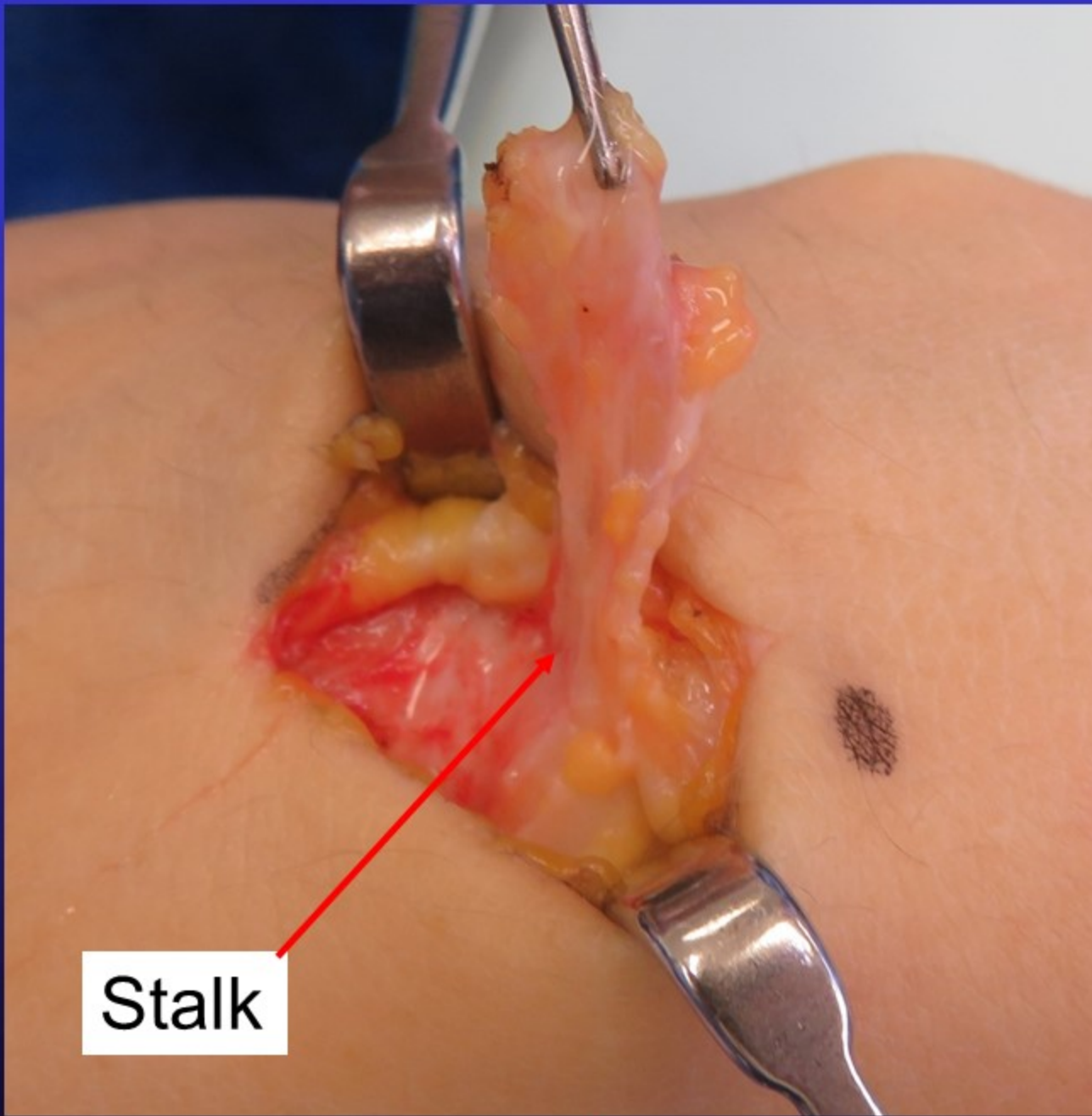
Ganglion



Ganglion

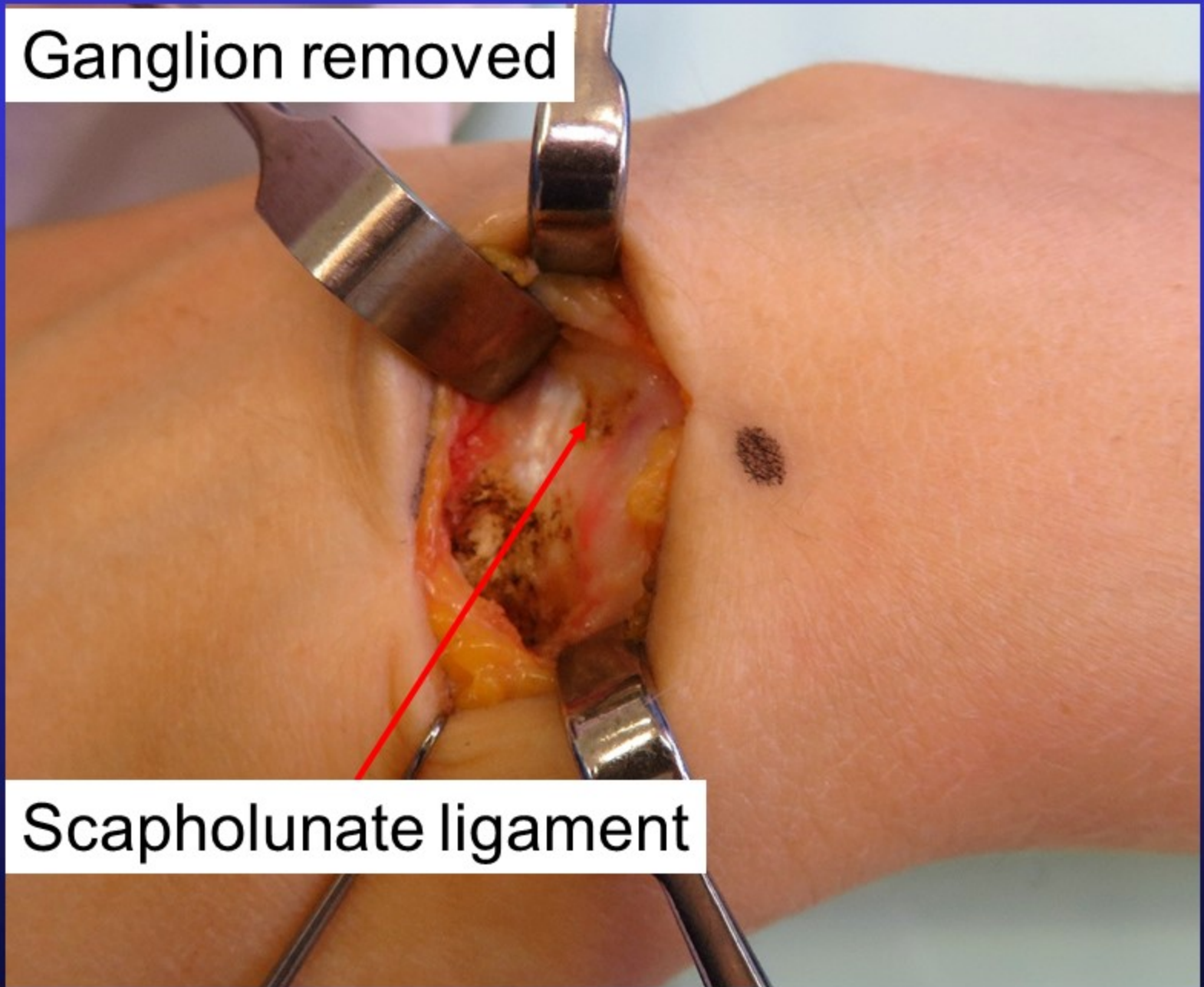
Stalk





Stalk

Ganglion removed

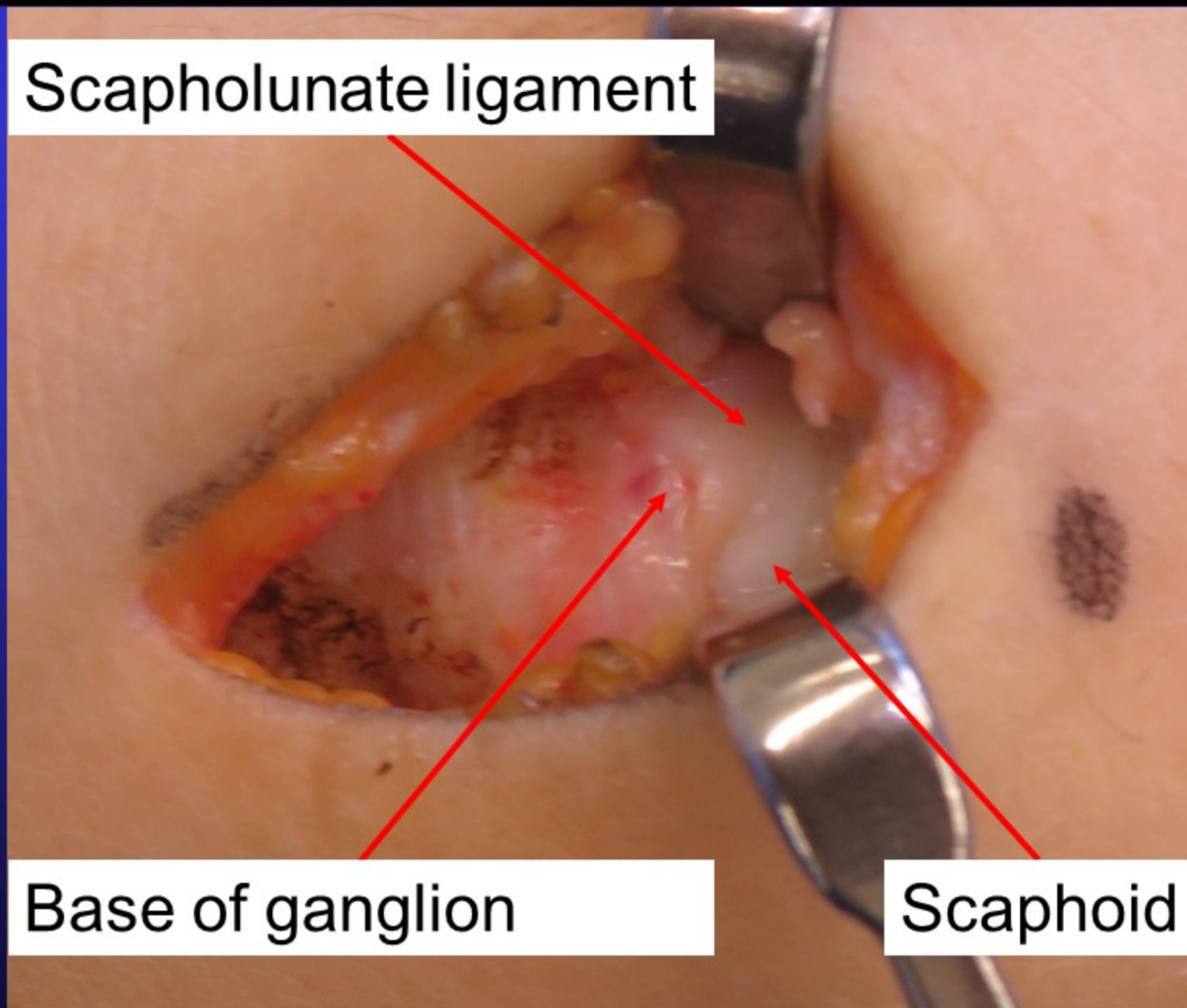


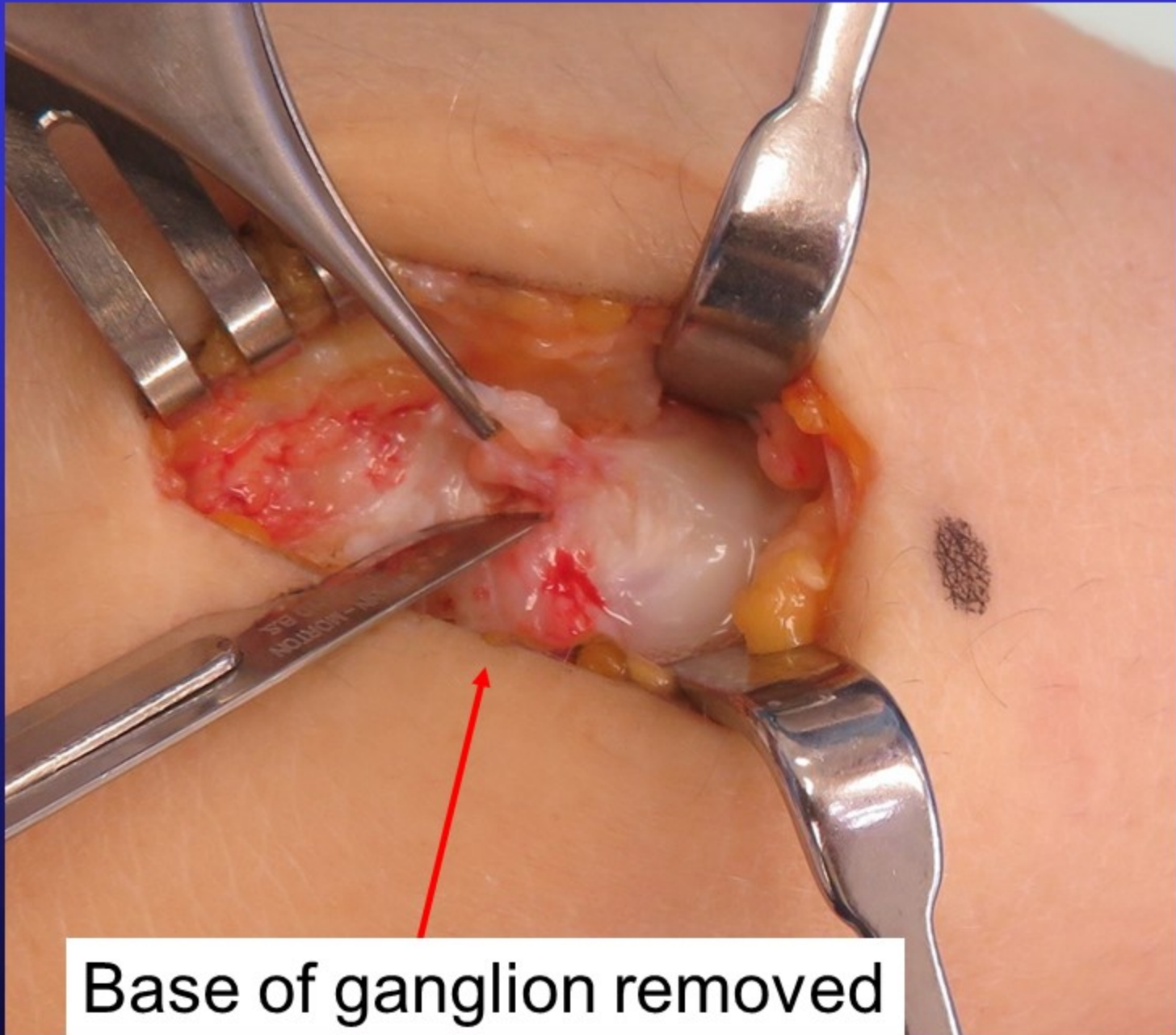
Scapholunate ligament

Scapholunate ligament

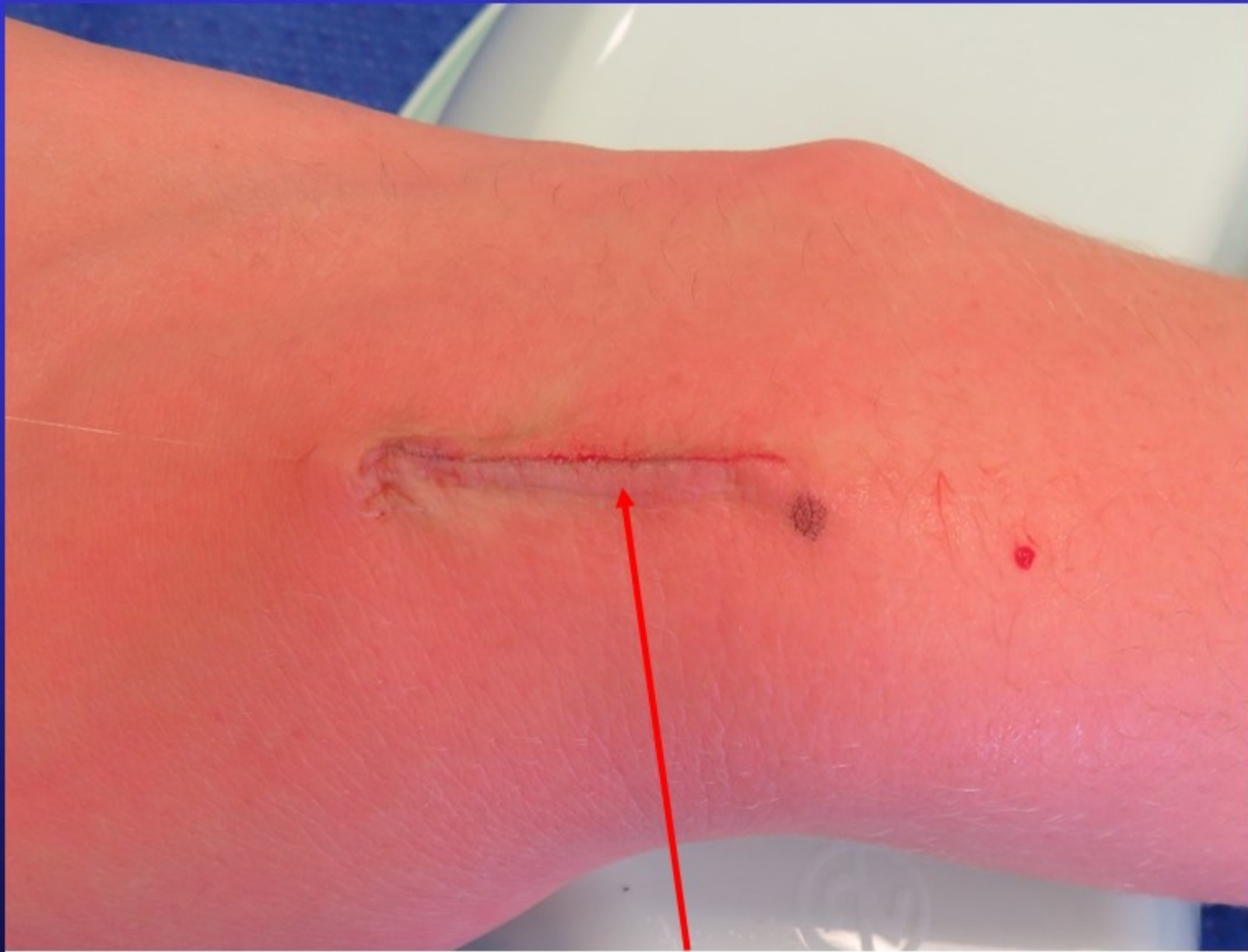
Base of ganglion

Scaphoid

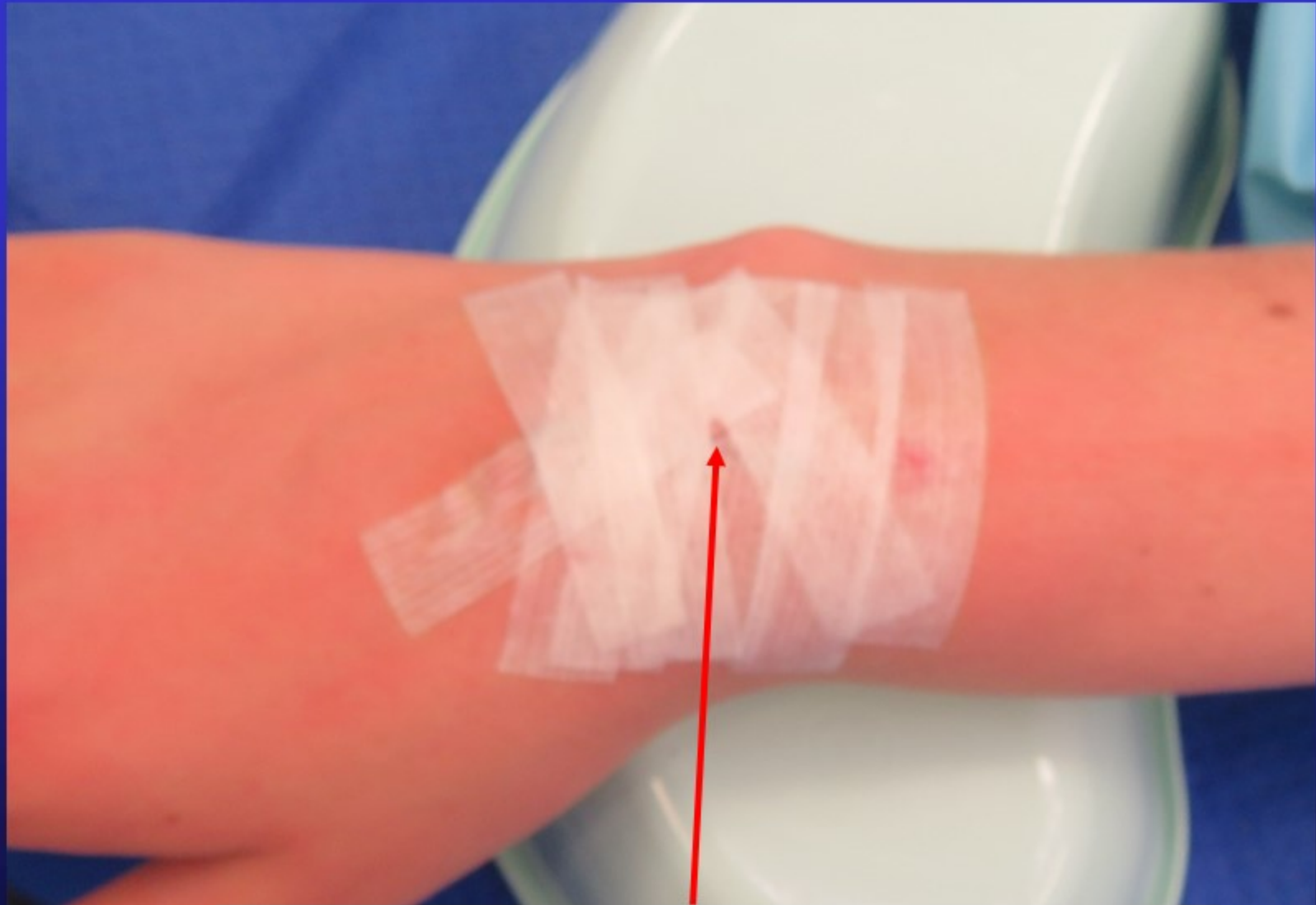




Base of ganglion removed

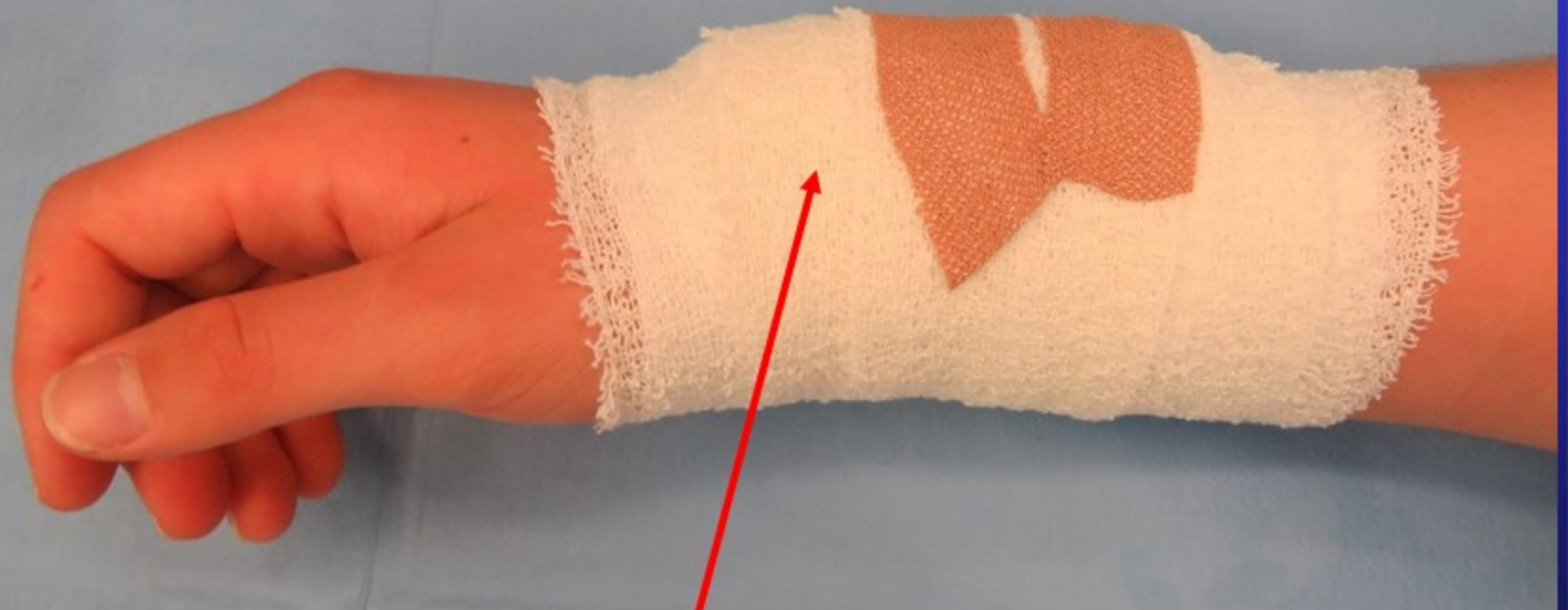

Wound closed with Monocryl buried suture



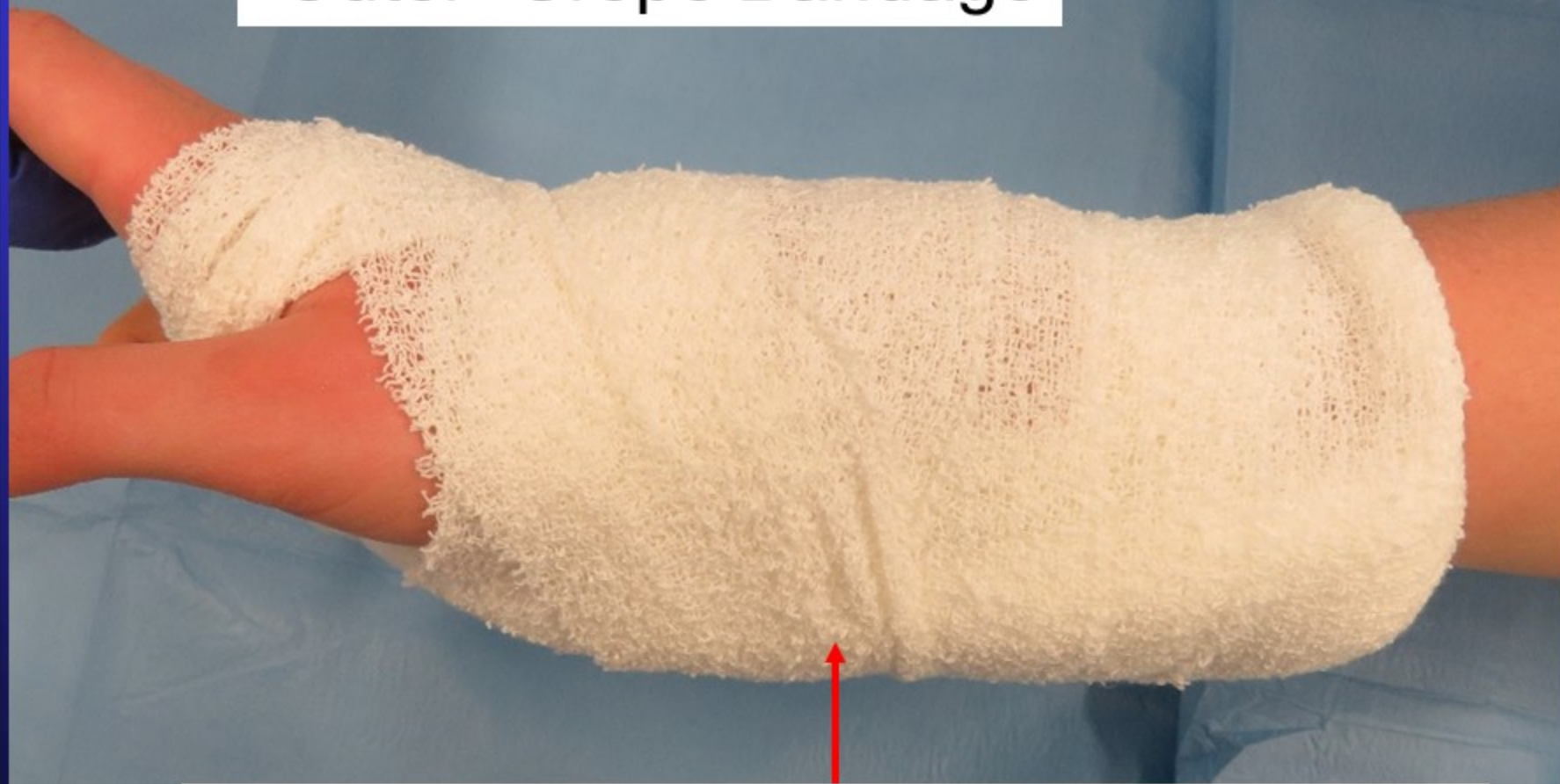Steristrips applied over wound

“Inner” Crepe Bandage



Dressing applied
– Leave intact & Dry for 10 days

“Outer” Crepe Bandage



Plaster slab – remove after 3 – 4 days

A nighttime photograph of a city skyline, likely Sydney, Australia, featuring several prominent skyscrapers illuminated with warm yellow and white lights. The buildings are reflected in the water in the foreground. A yellow rectangular box is overlaid on the lower left portion of the image, containing the website address. The text 'The End' is written in a large, white, serif font with a black outline in the bottom right corner.

www.myhand.com.au

The End