

EI to EPL tendon Transfer

Dr Stuart Myers

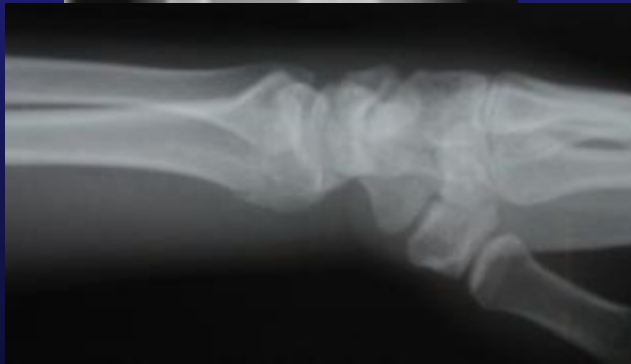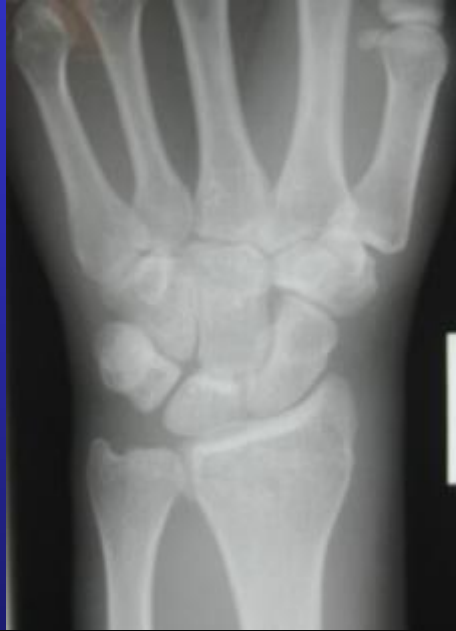KAREENA
PRIVATE HOSPITAL

Orthopaedic Hand Surgeon,
Sydney Orthopaedic Specialists

www.myhand.com.au

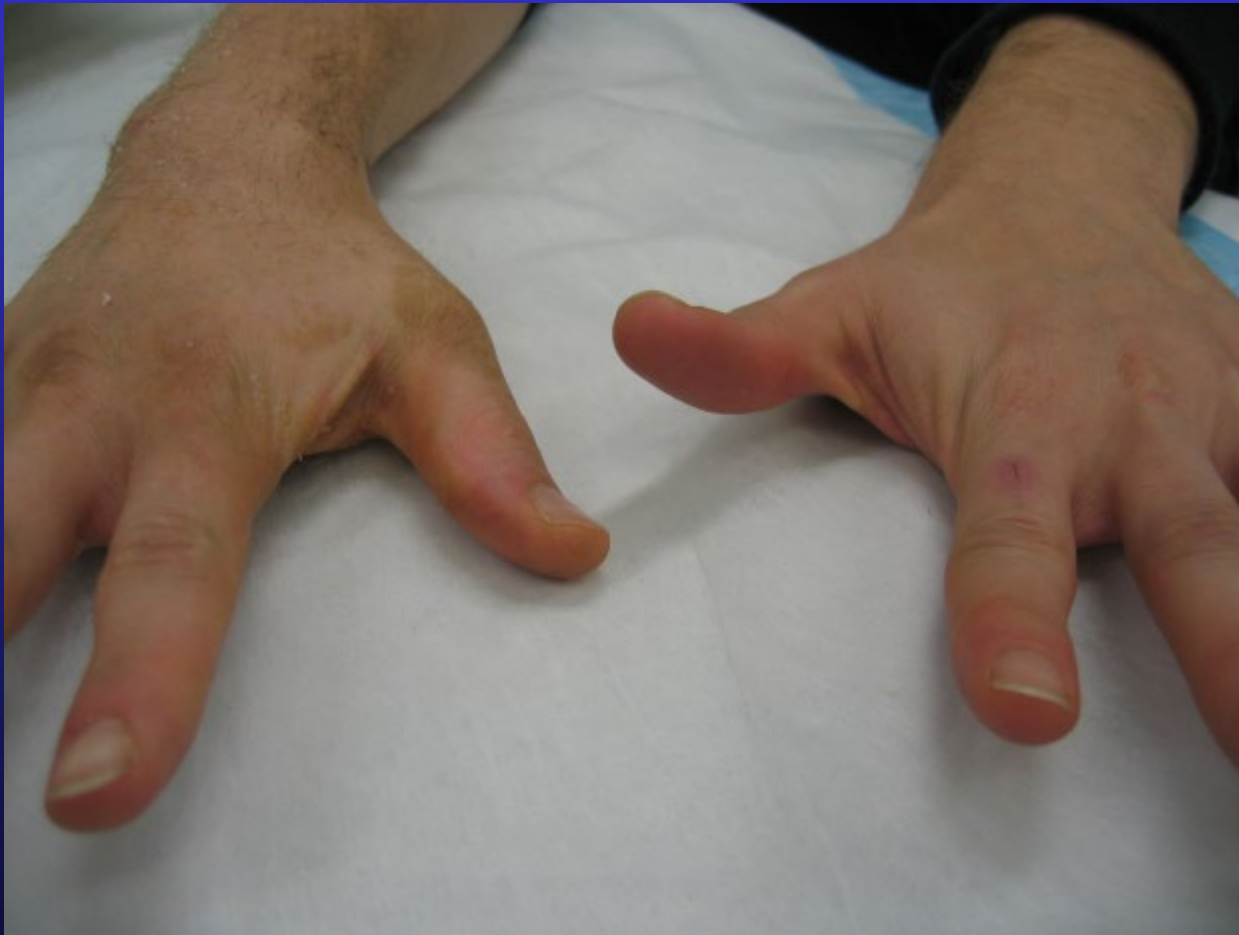

Post Undisplaced Colles

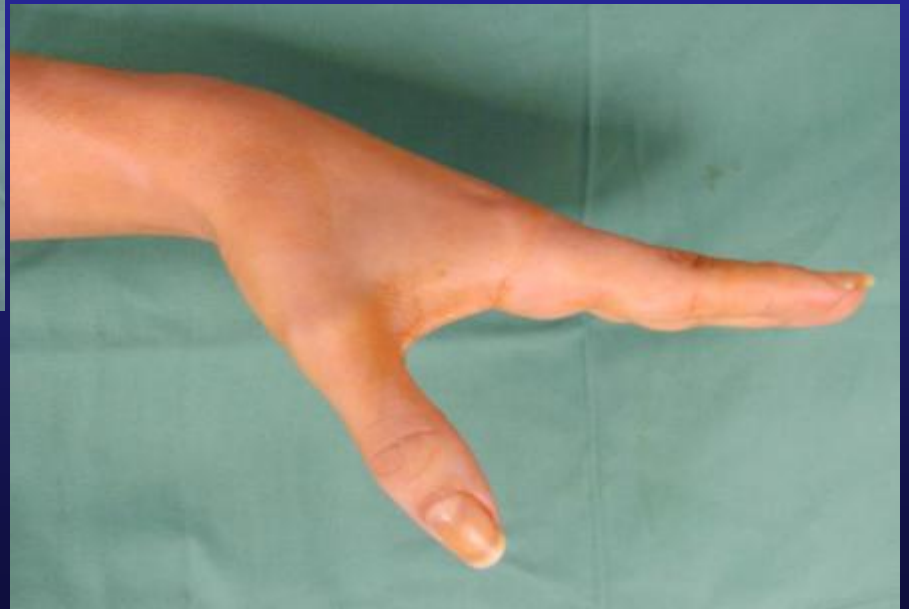
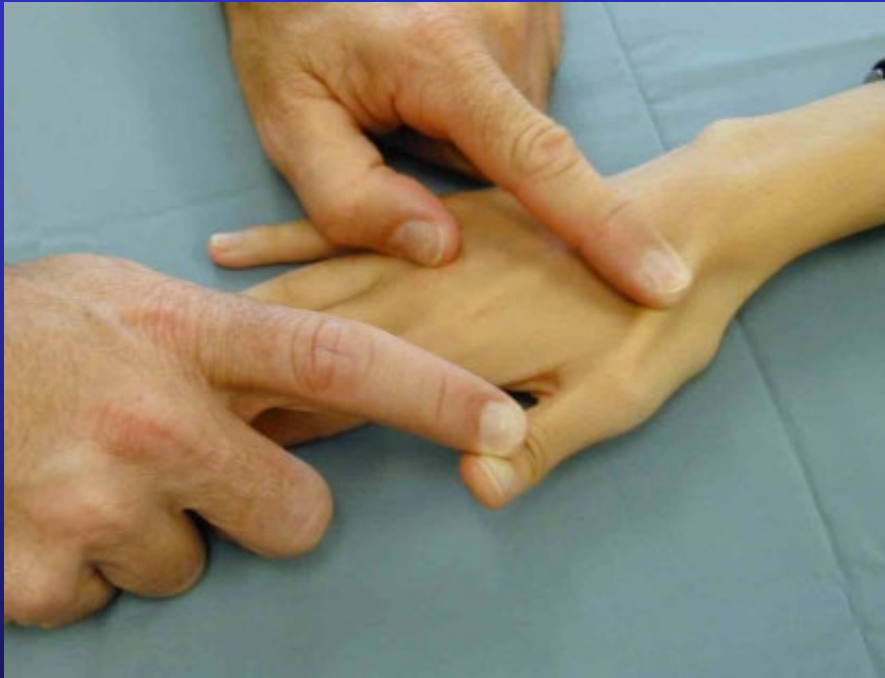
- Allow Fracture to heal
- Hand Therapy
 - Regain full ROM wrist
 - Maintain thumb range of motion

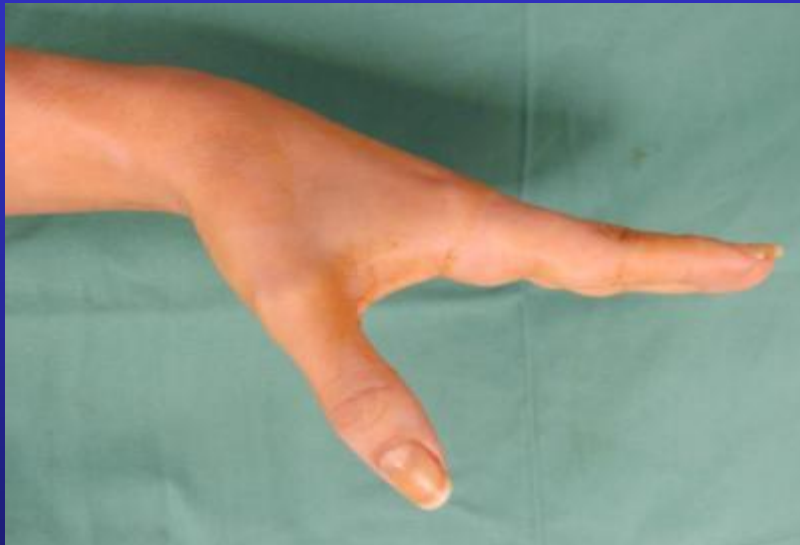Diagnosis



Testing EPL function



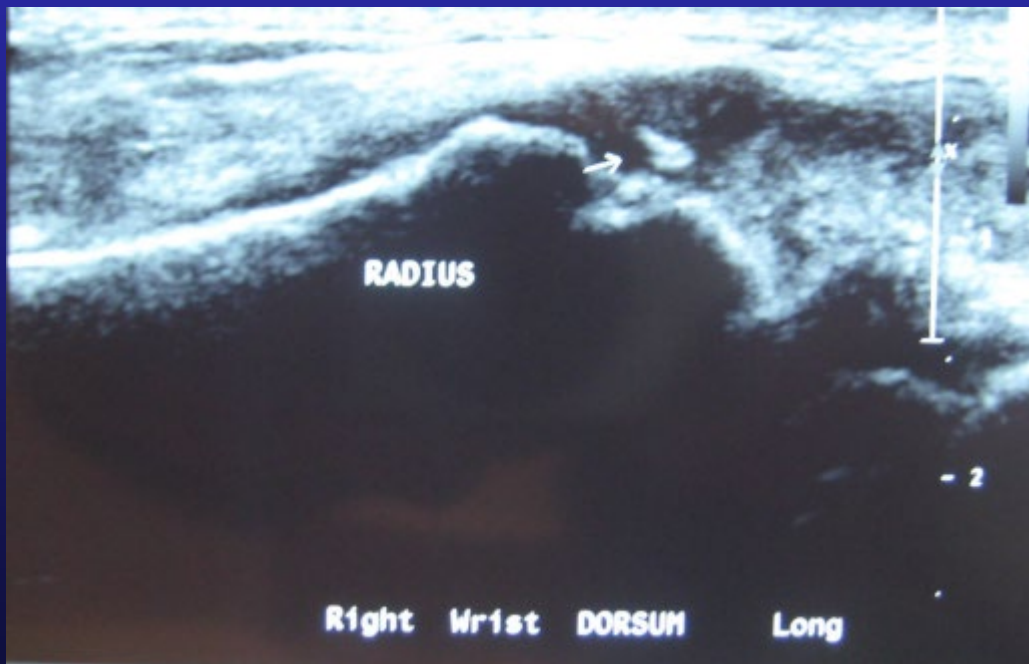Pre-op Check



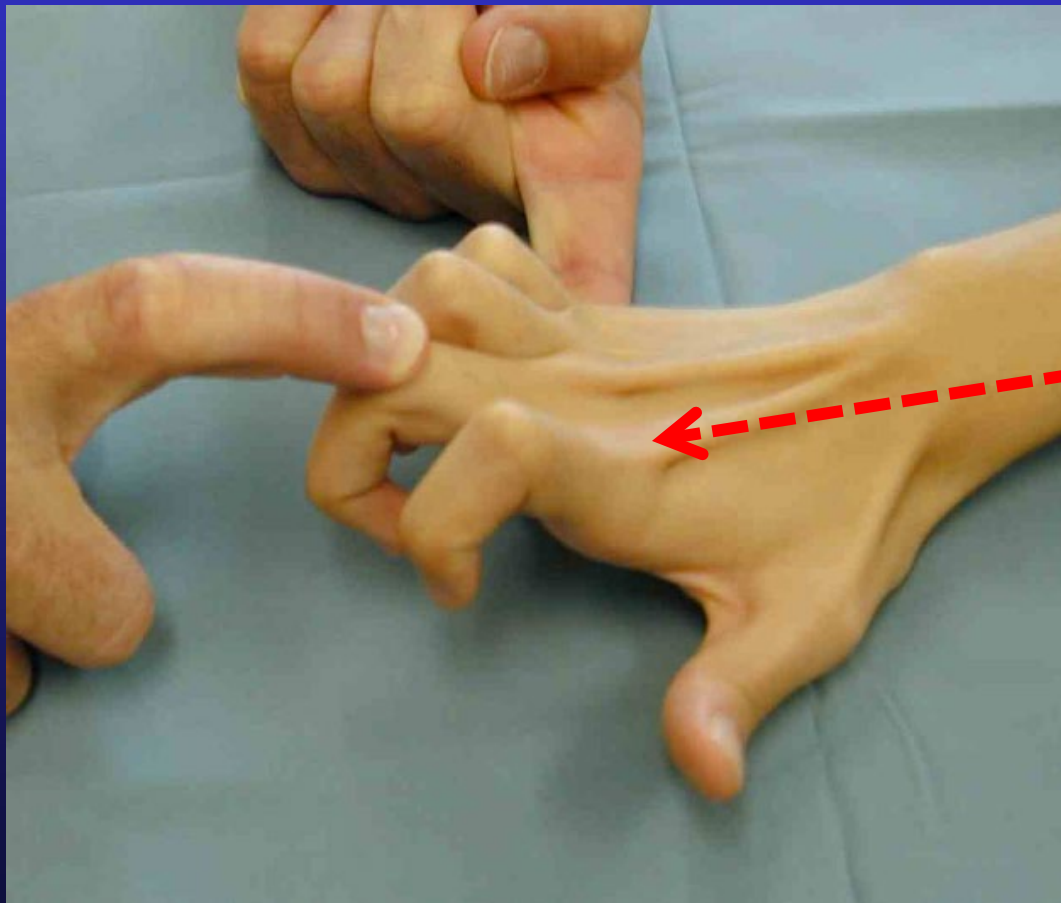
- Passive ROM
 - Thumb
 - Wrist
- Exclude Thumb OA
 - May become irritable after 6 weeks in a cast in retropulsion

Ultrasound wrist

- Ultrasound wrist after fracture if concern re bone spike - this may rupture tendon transfer

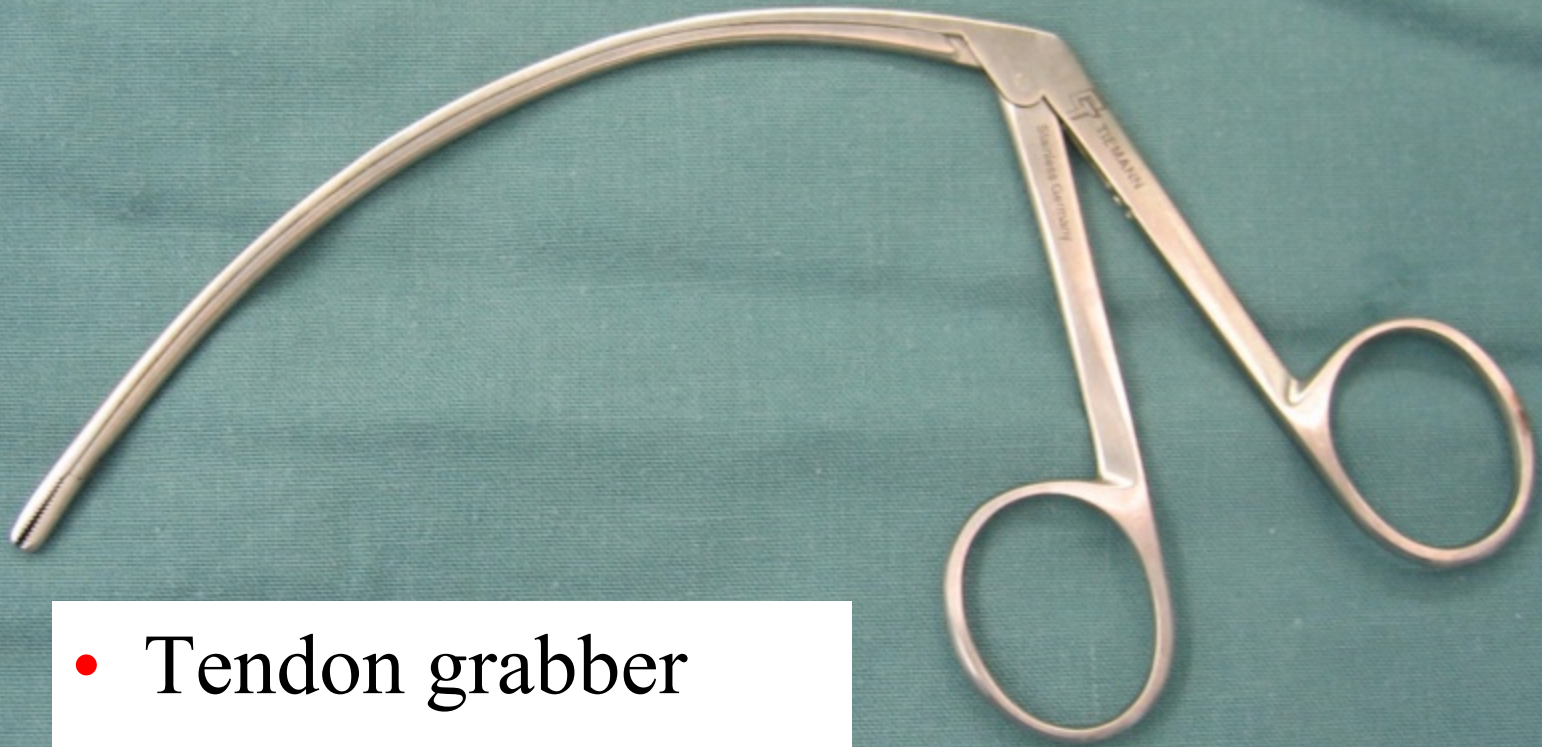


Pre-op Check



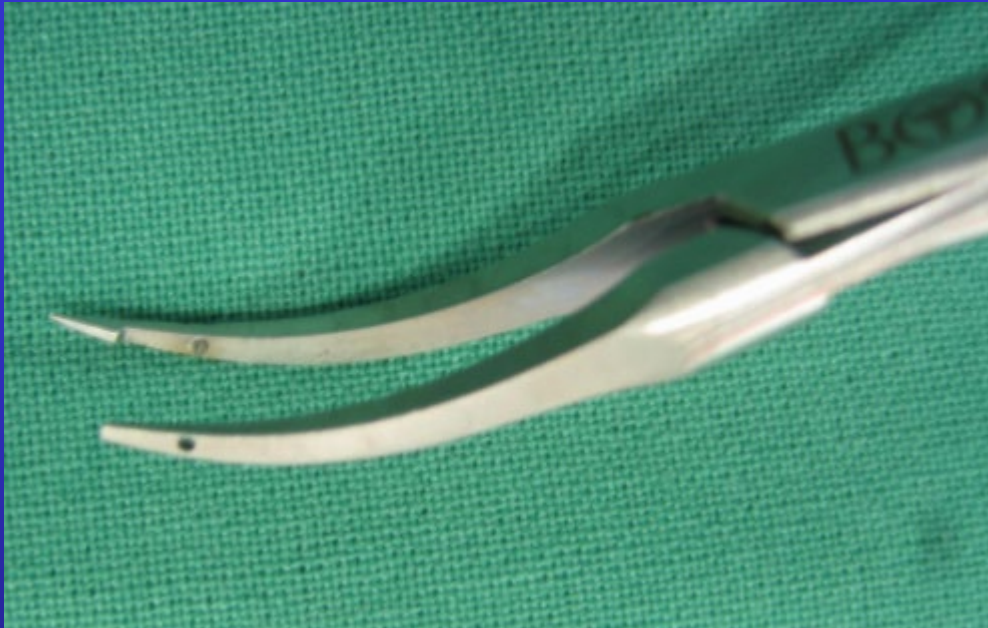- Check for 2 index extensor tendons
 - EI on the ulnar side and deeper

Essential Instruments

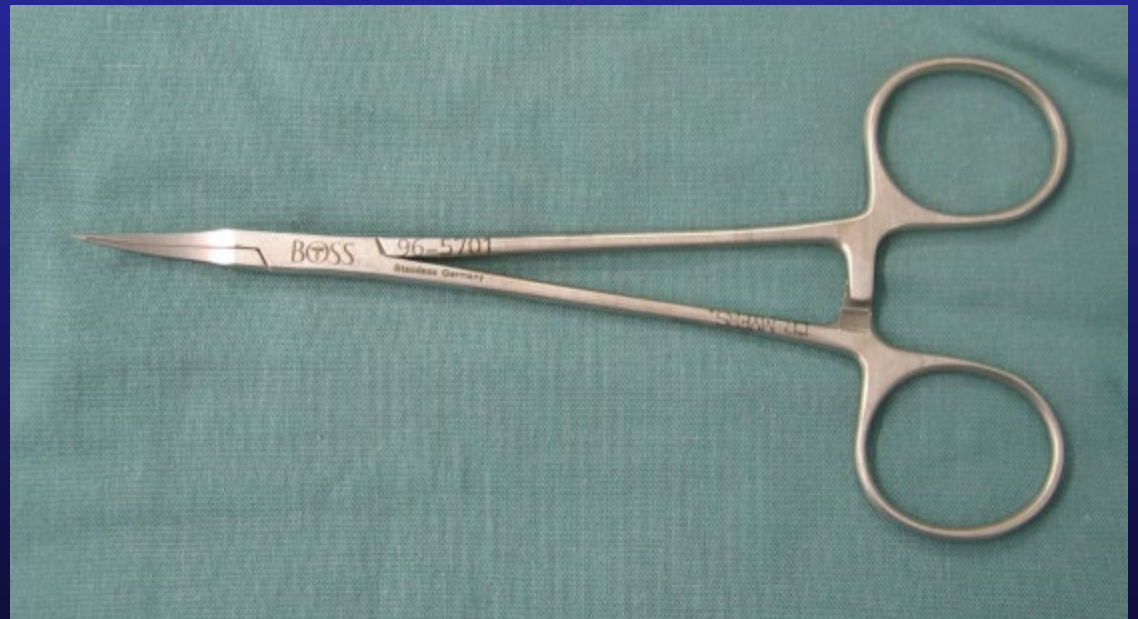

- Tendon grabber

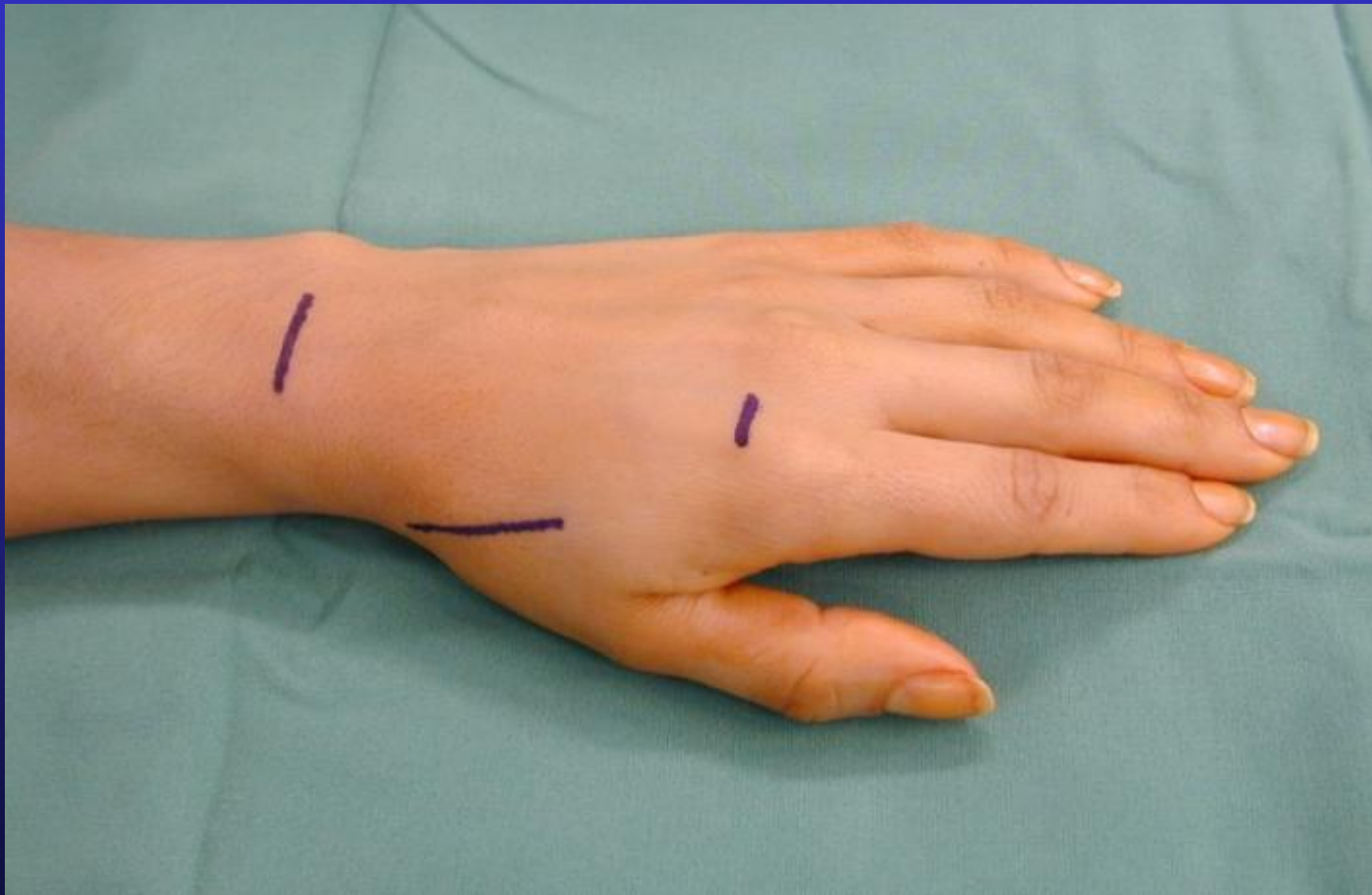
Essential Instruments



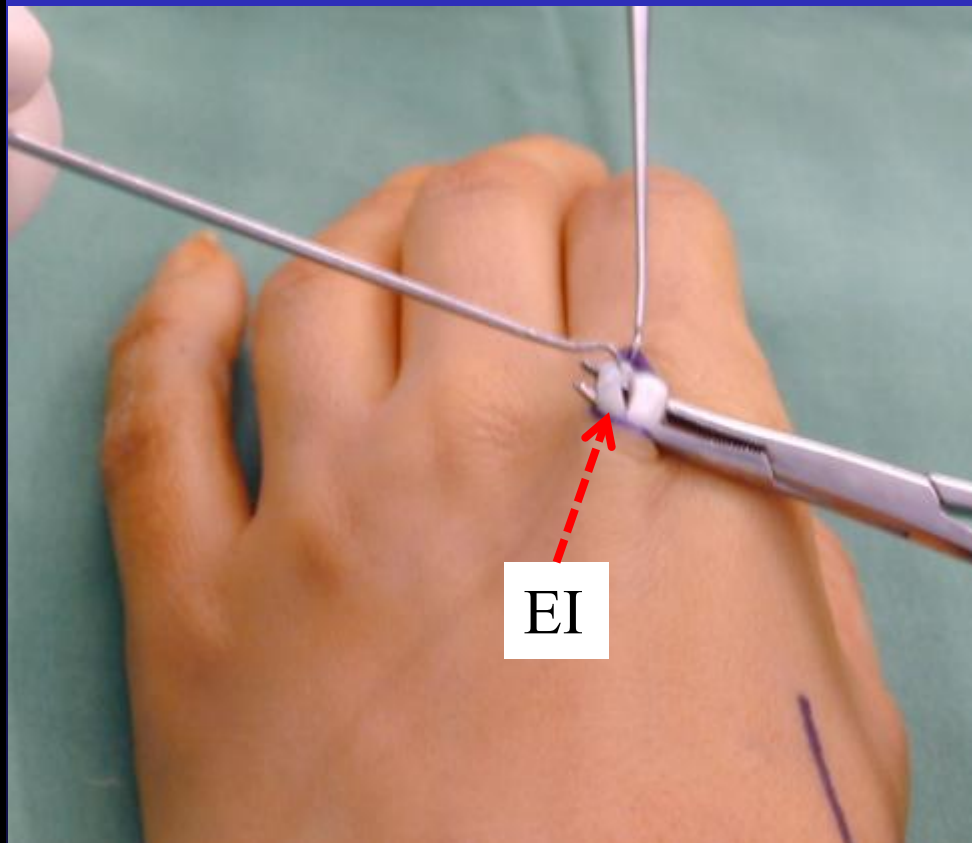
- Tendon passer



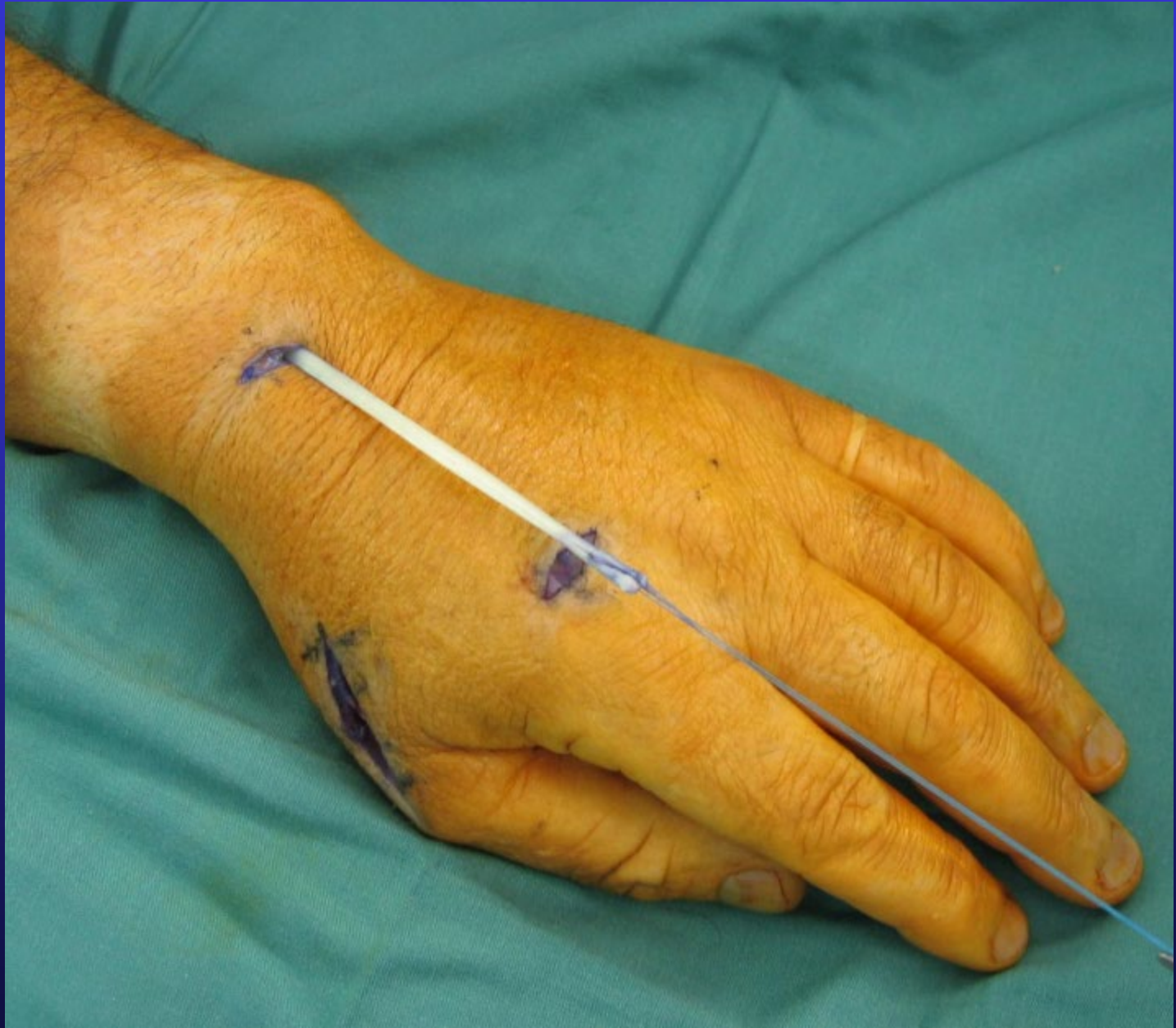Incisions



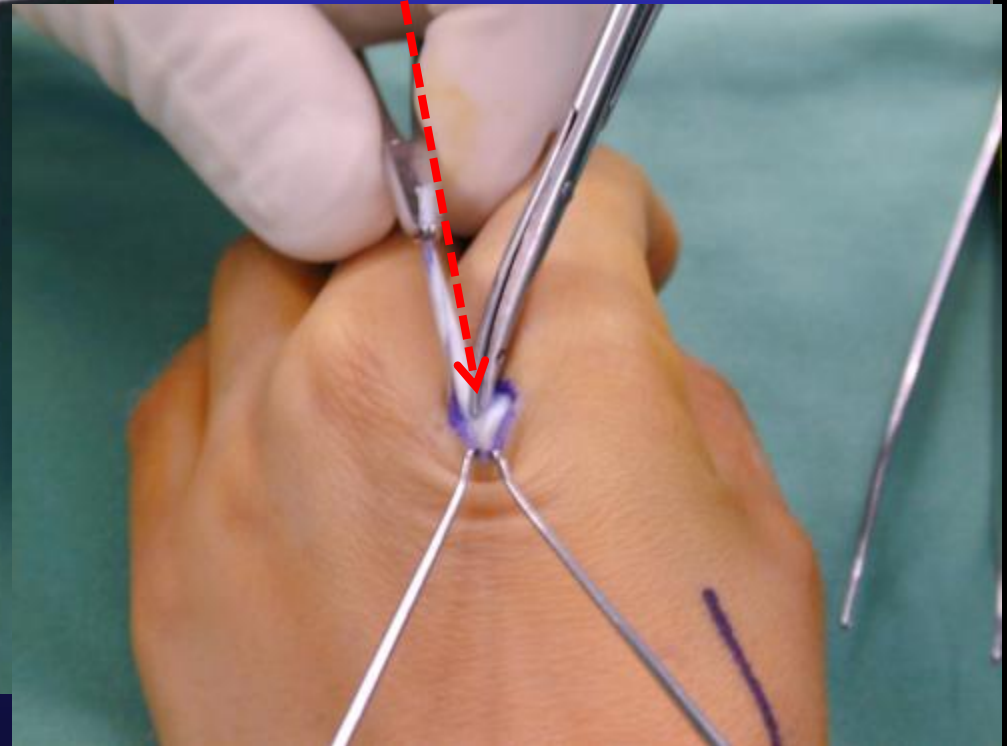
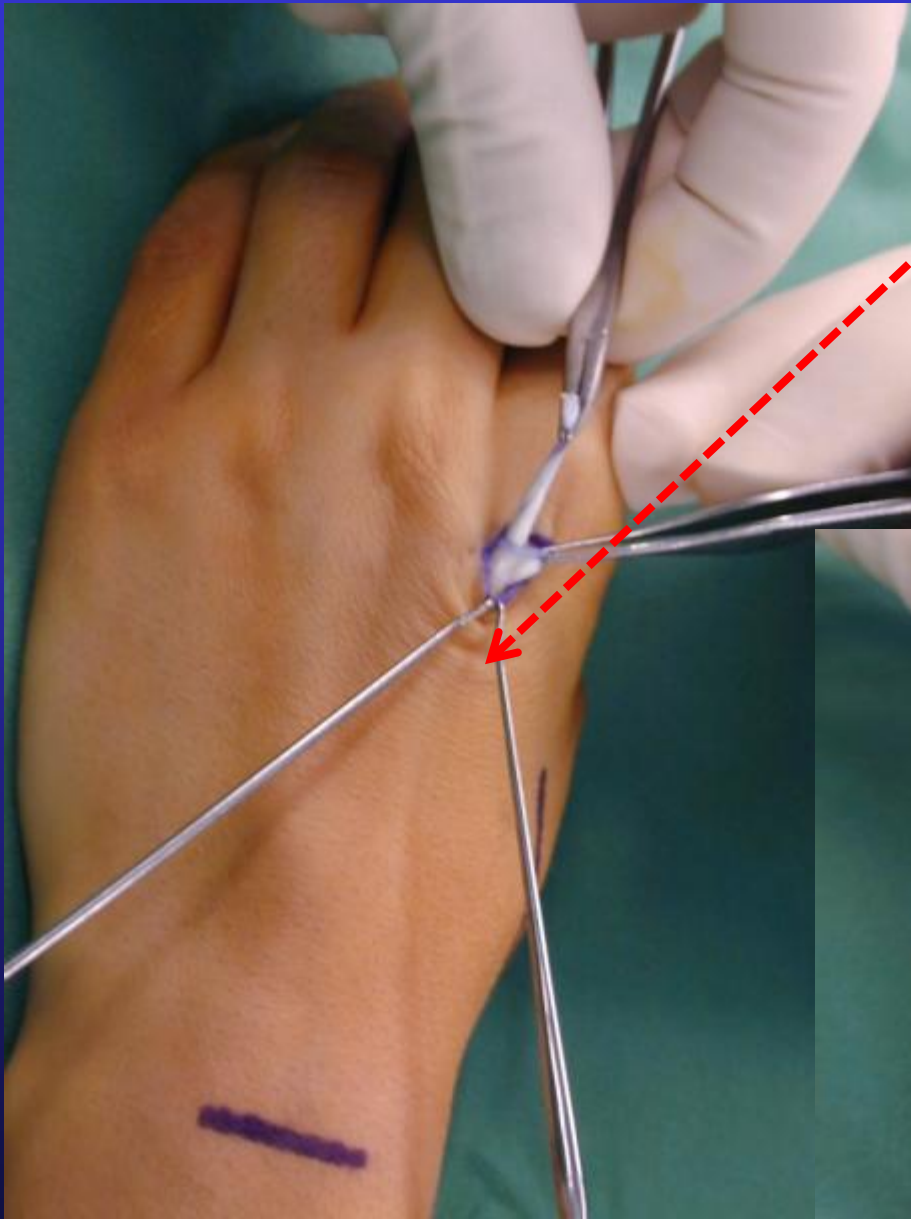
EI harvest

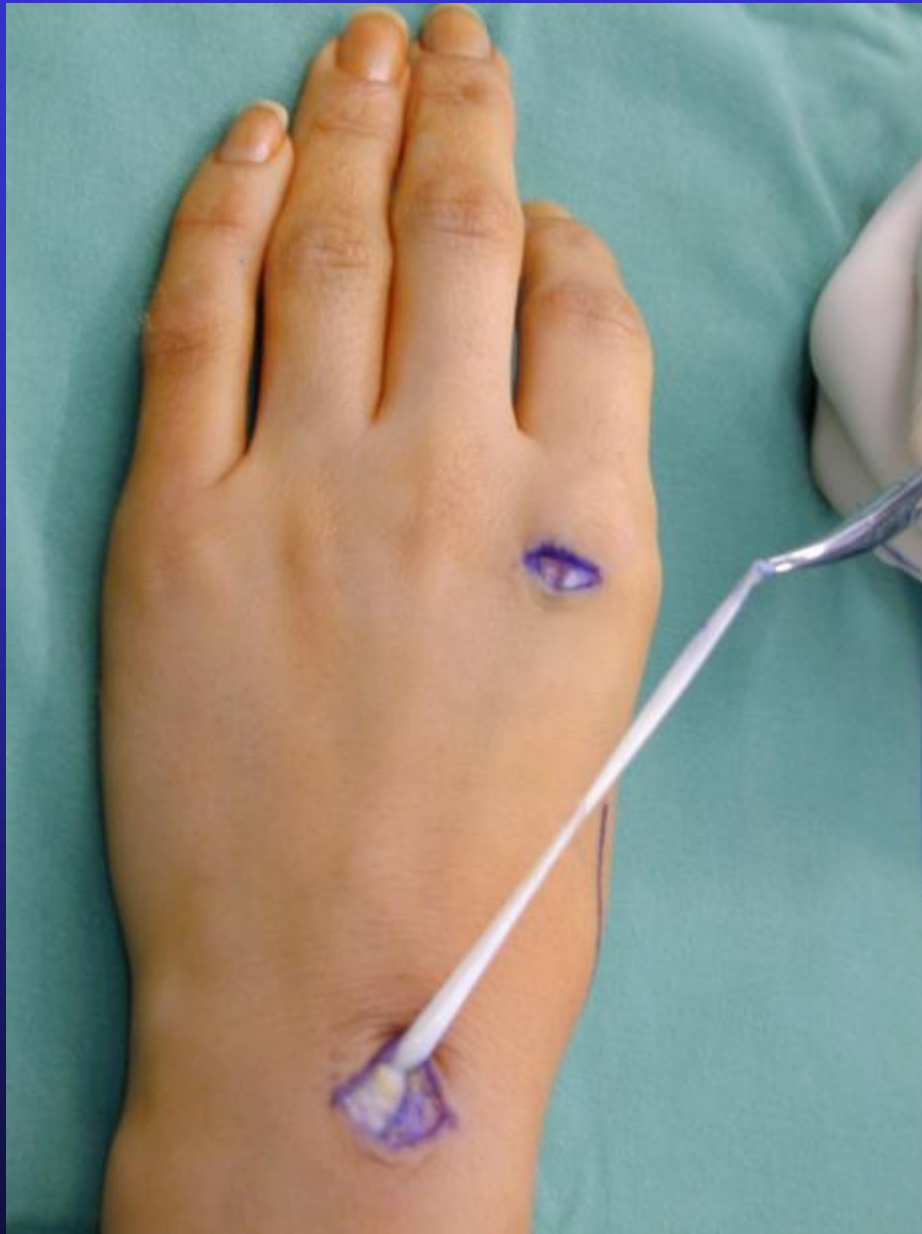

- Put a suture through end of EI in case it is difficult to retrieve in the proximal wrist wound
 - Often some fibrous septae which need to be released



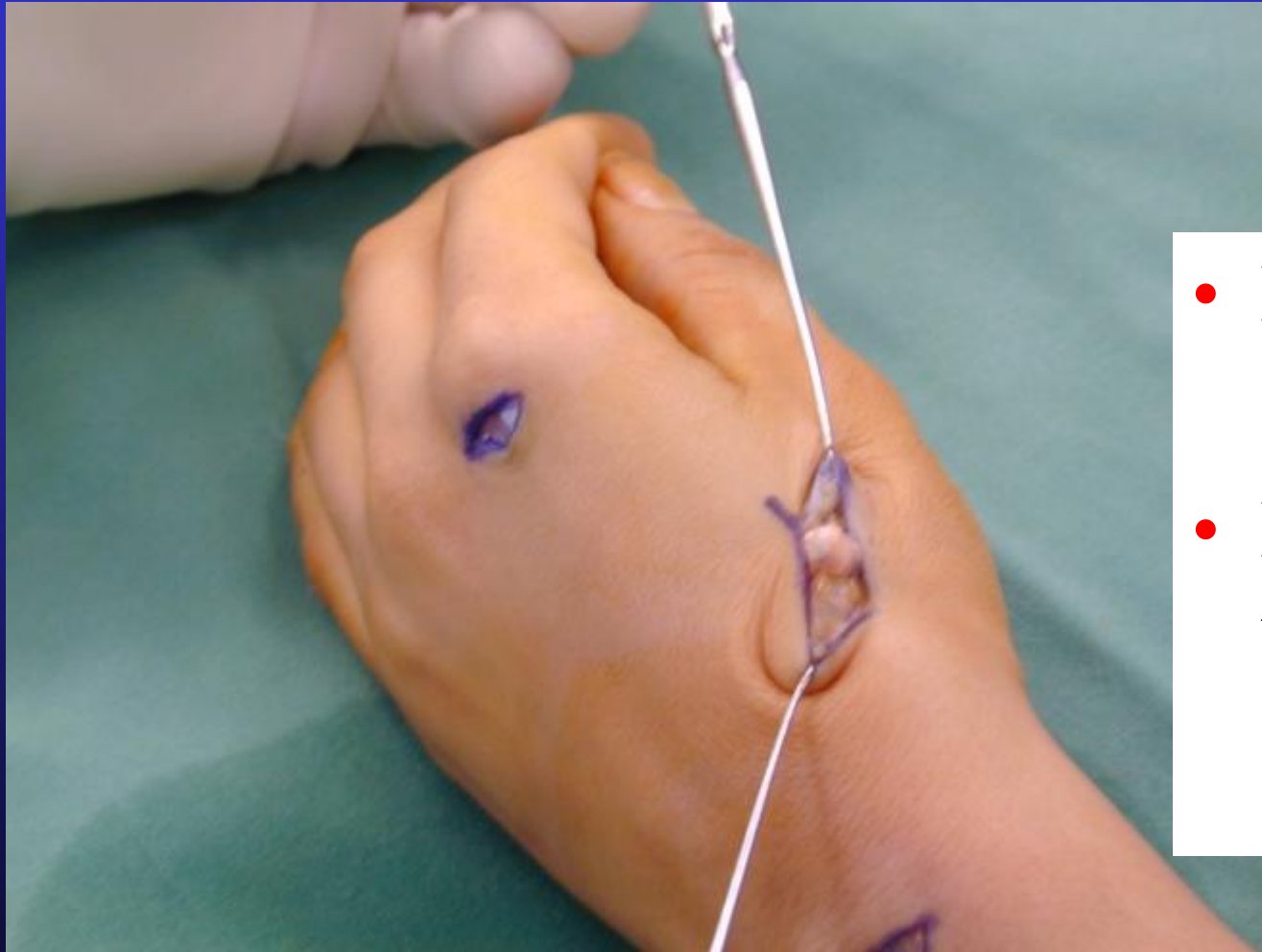
- Release fibrous septae





- Tendon retrieved proximally
- Wrap tendon in moist gauze to keep it off skin

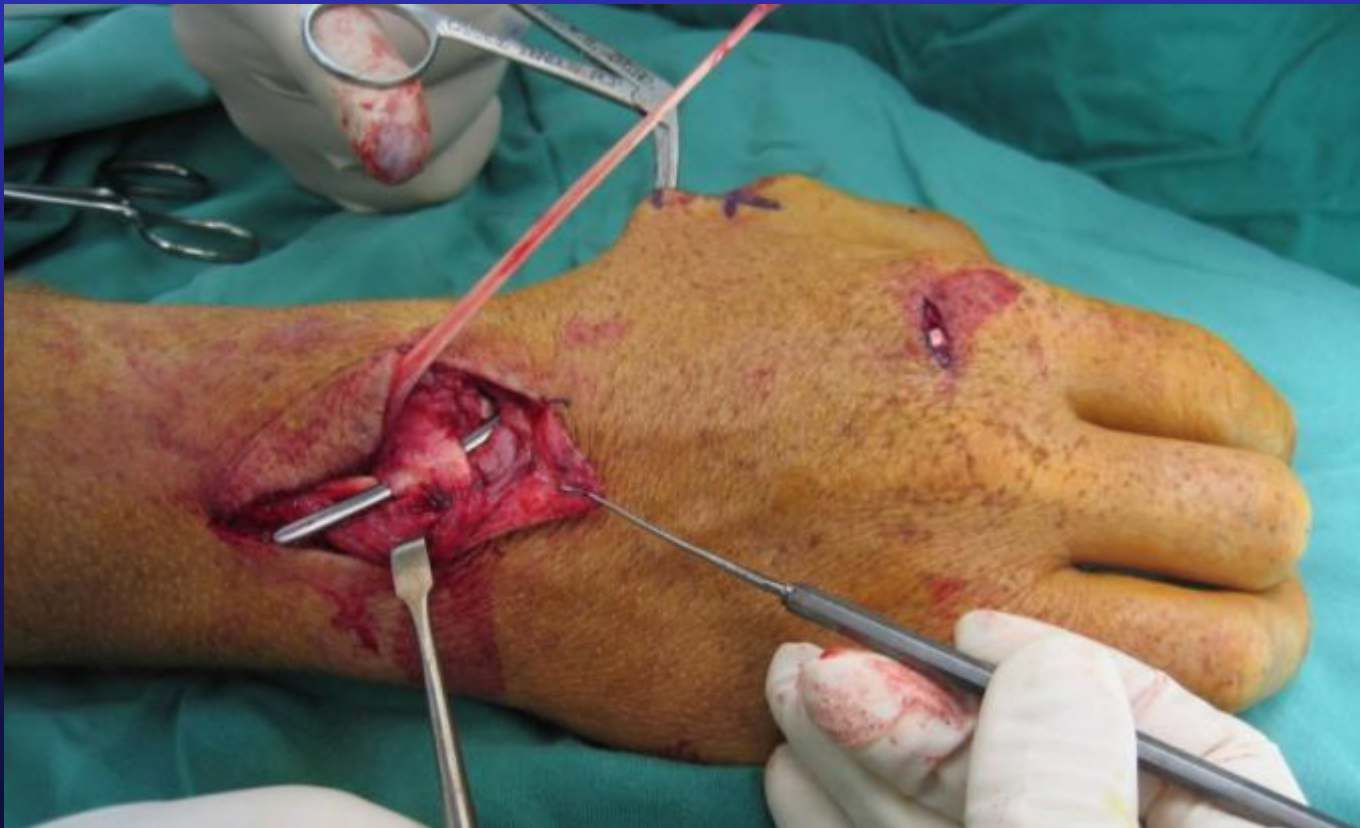Thenar incision



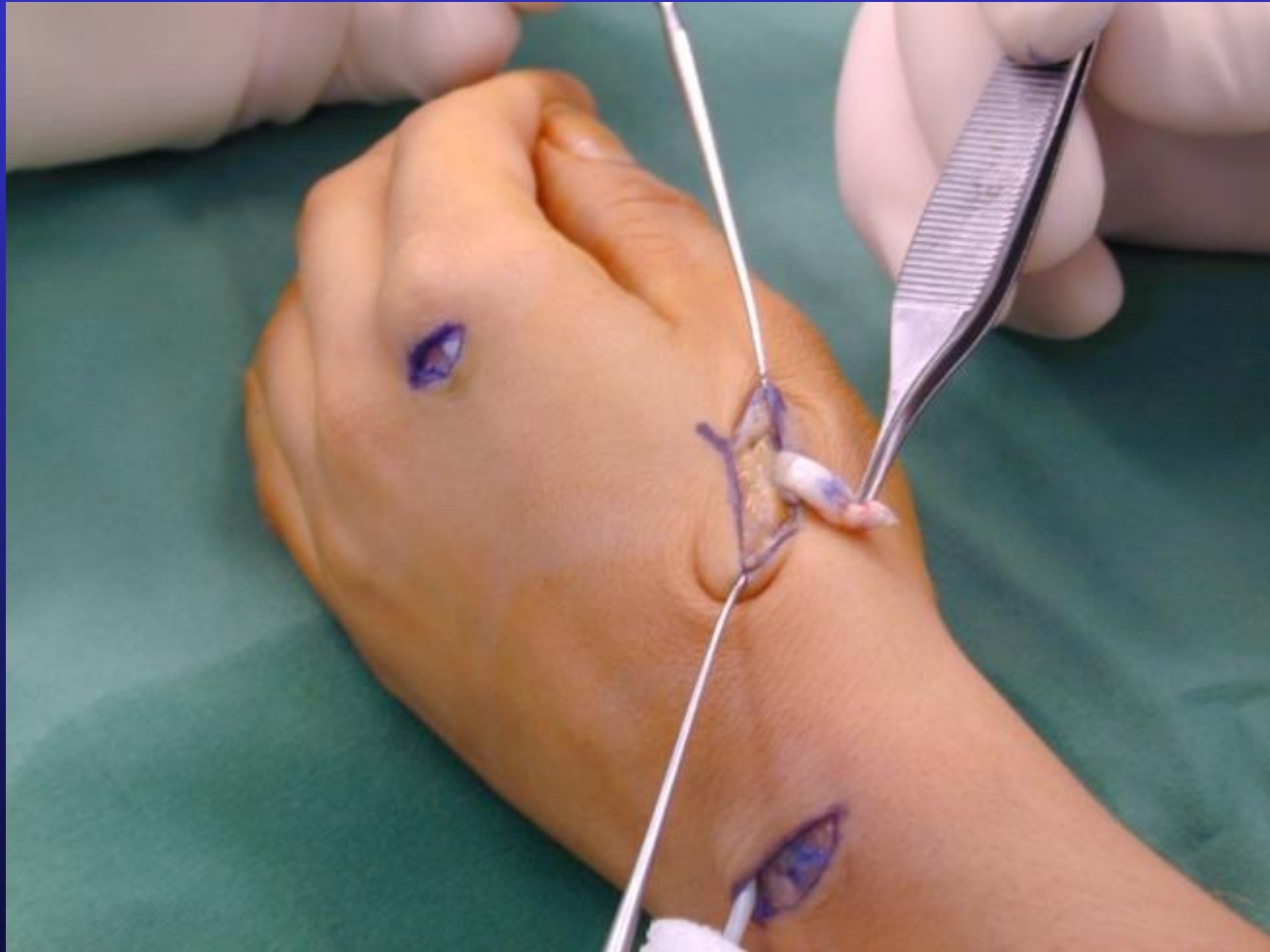
- Beware SRN
- Find EPL tendon end

Tendon grabber

- Easier to find correct tendon plane adjacent to EPL stump

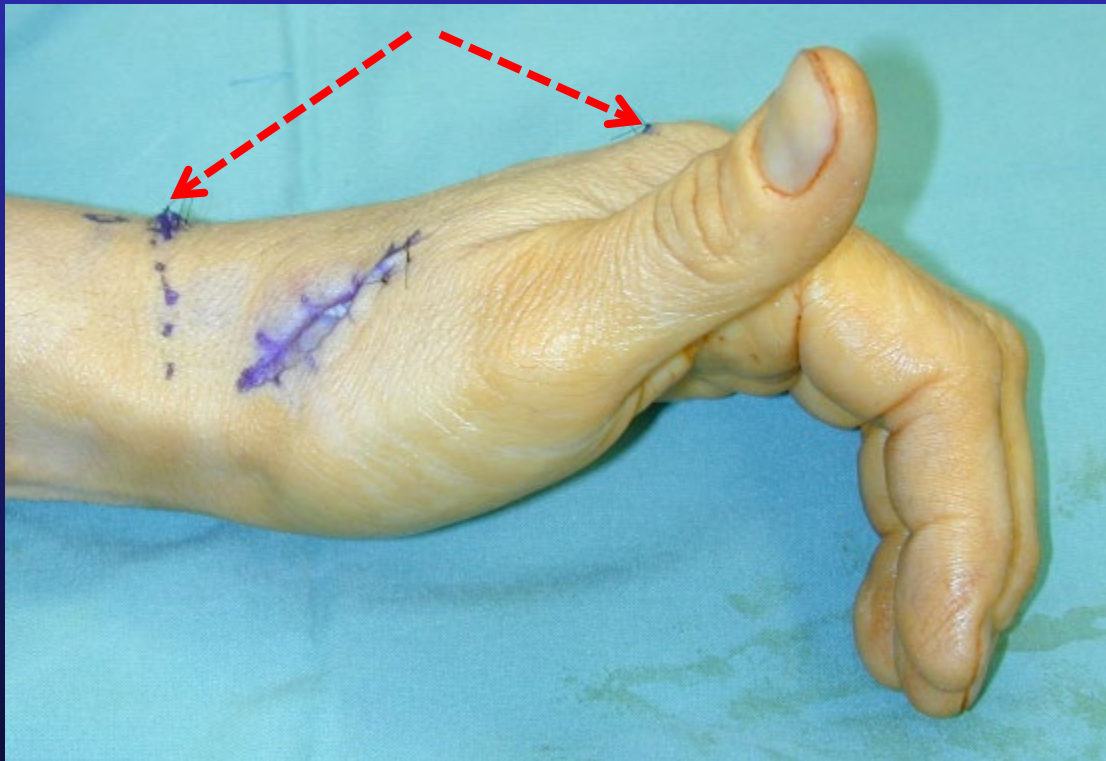


EPL distal tendon



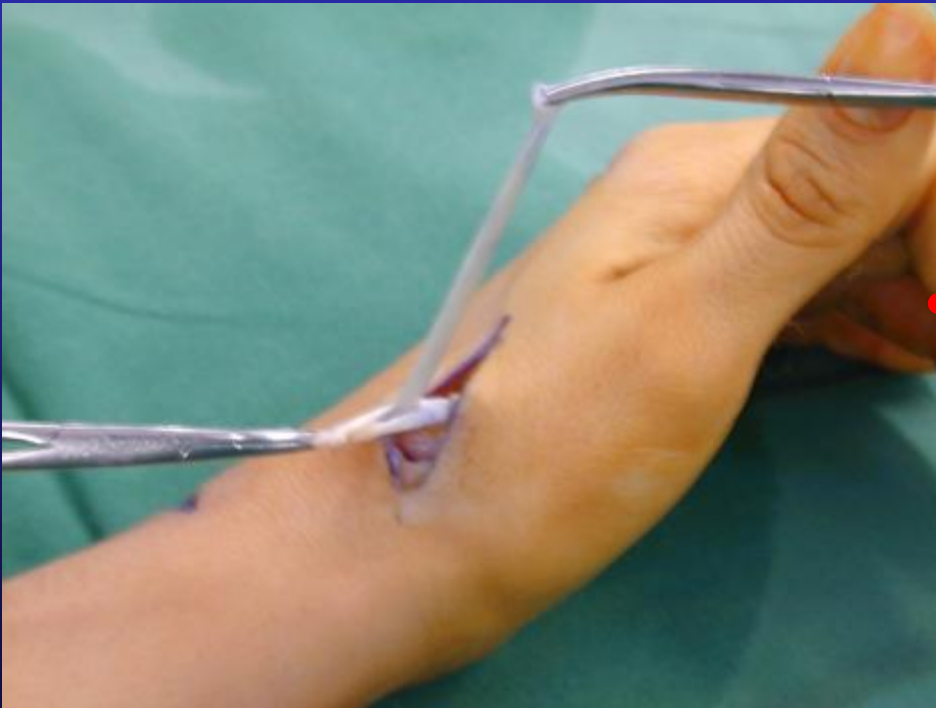
Close 2 donor wounds 1st

- Before tendon junction

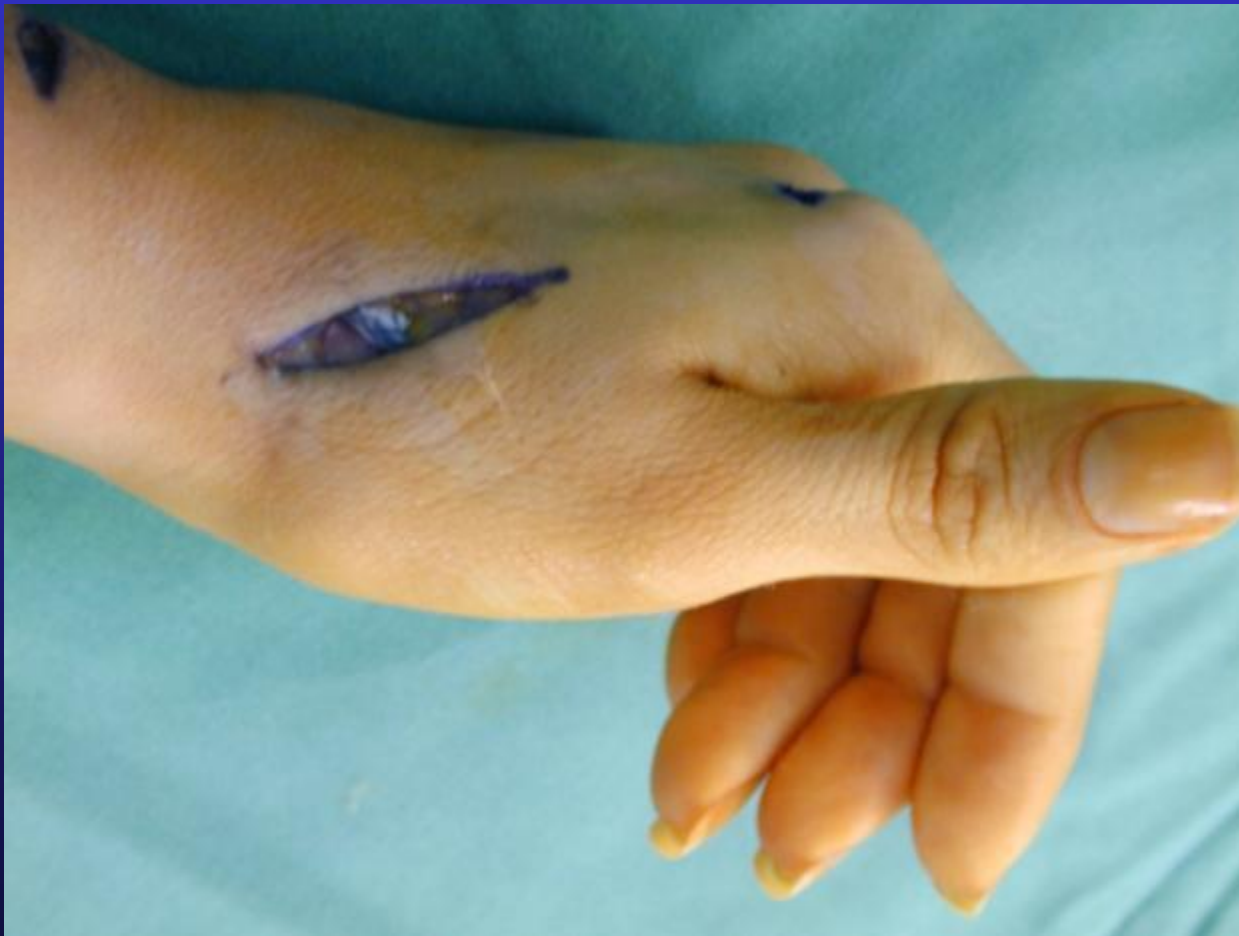

Tendon junction

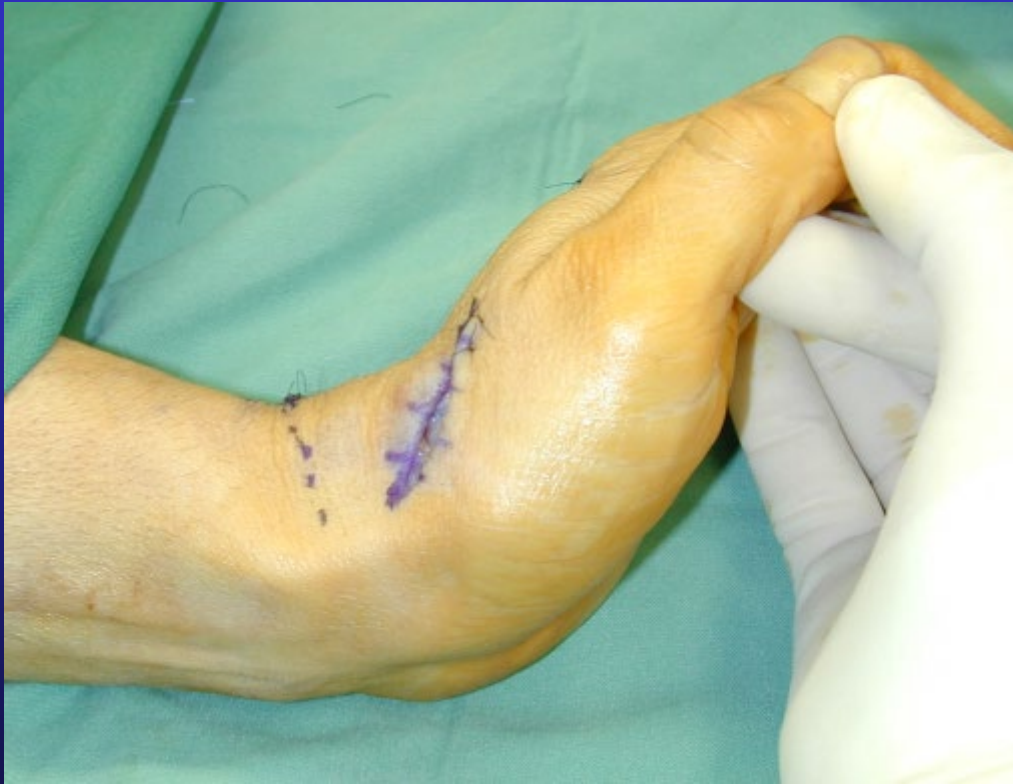- +/- As tight as possible – it will stretch
- 30 or 40 Ticron sutures



+/- Never too tight!!!

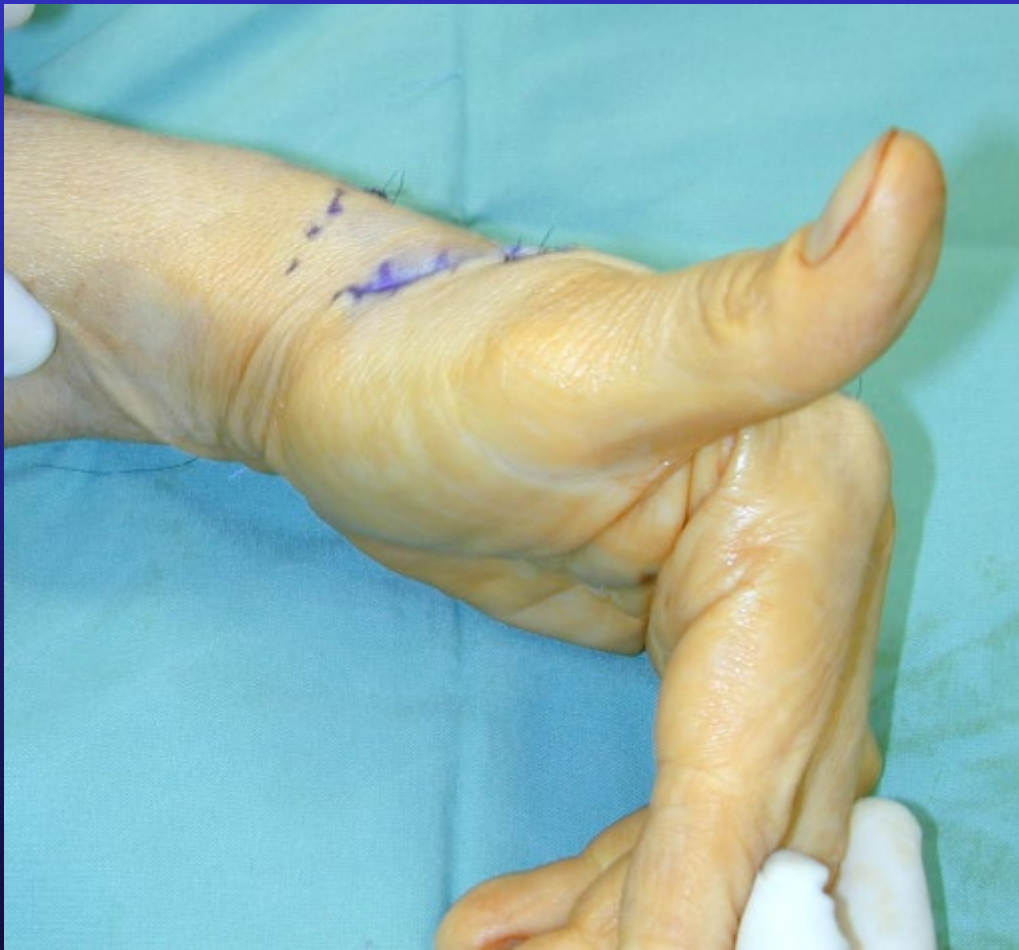

Testing tension



- Wrist DF thumb can touch index

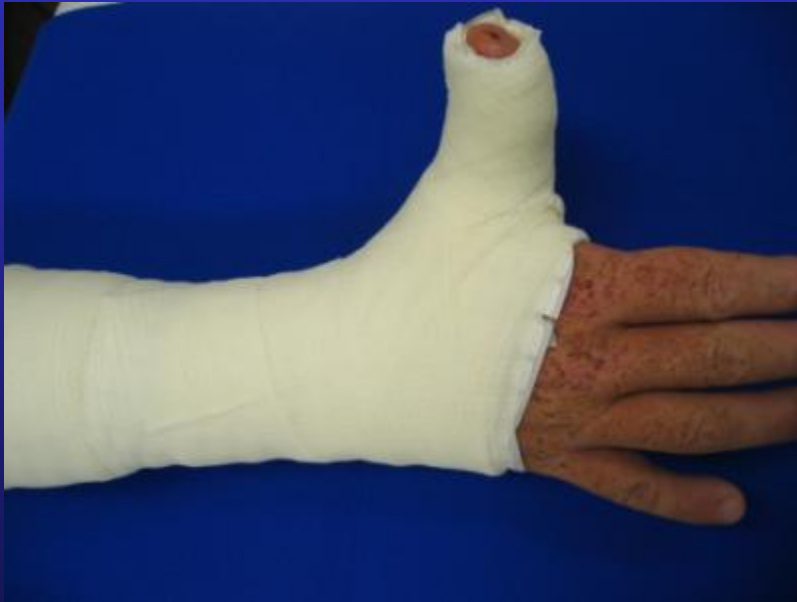Testing tension



- Wrist neutral
thumb fully extends
- In practice I find
this is too loose!!!

Cast 6 weeks

- Wrist DF 30 – 40 *
- Thumb extended



Hand Therapy

- Crepe bandage after cast remove
- Scar massage
- Transfer will stretch within 6 weeks



The End

www.myhand.com.au