

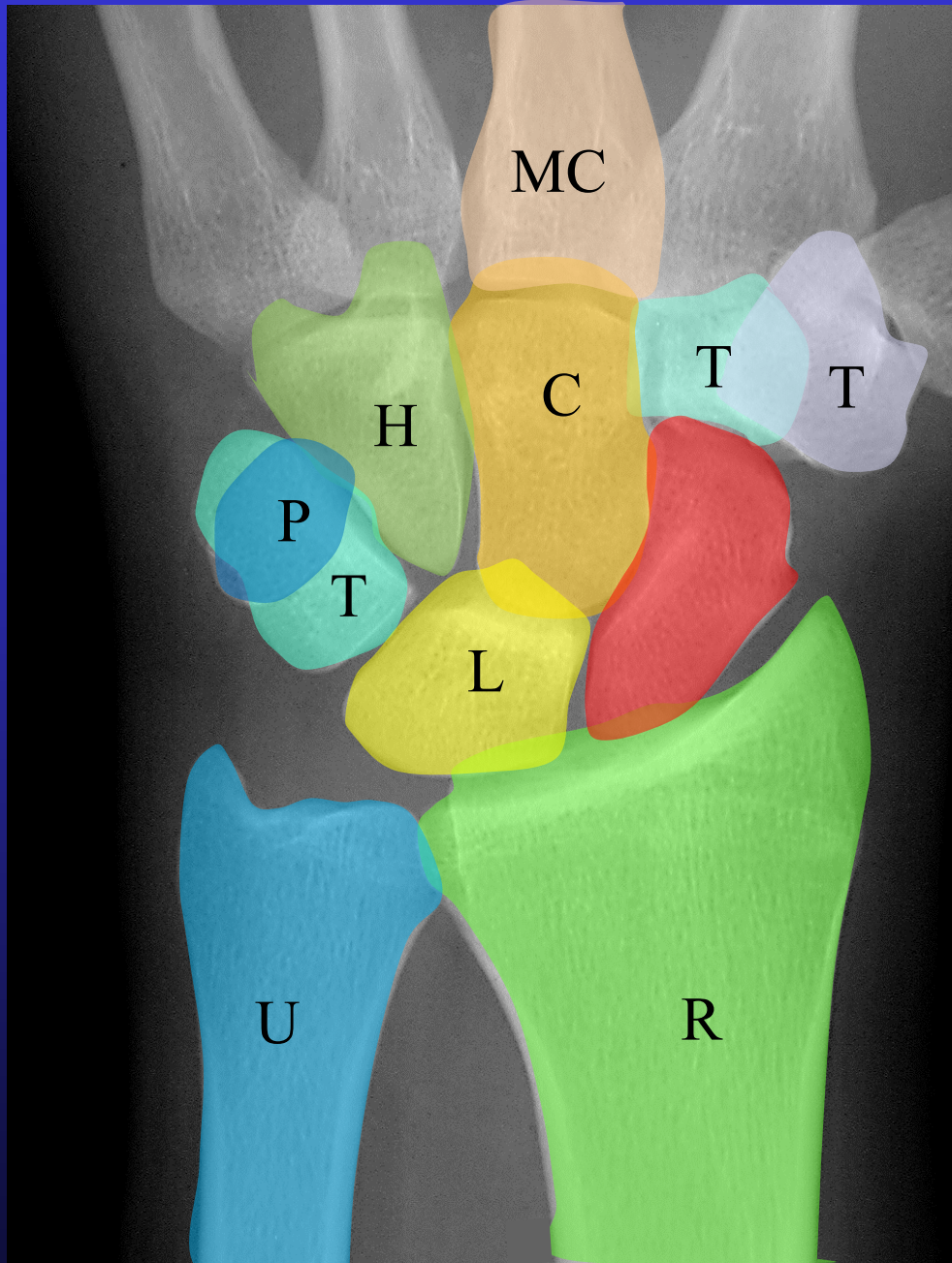
Lateral Wrist Xrays

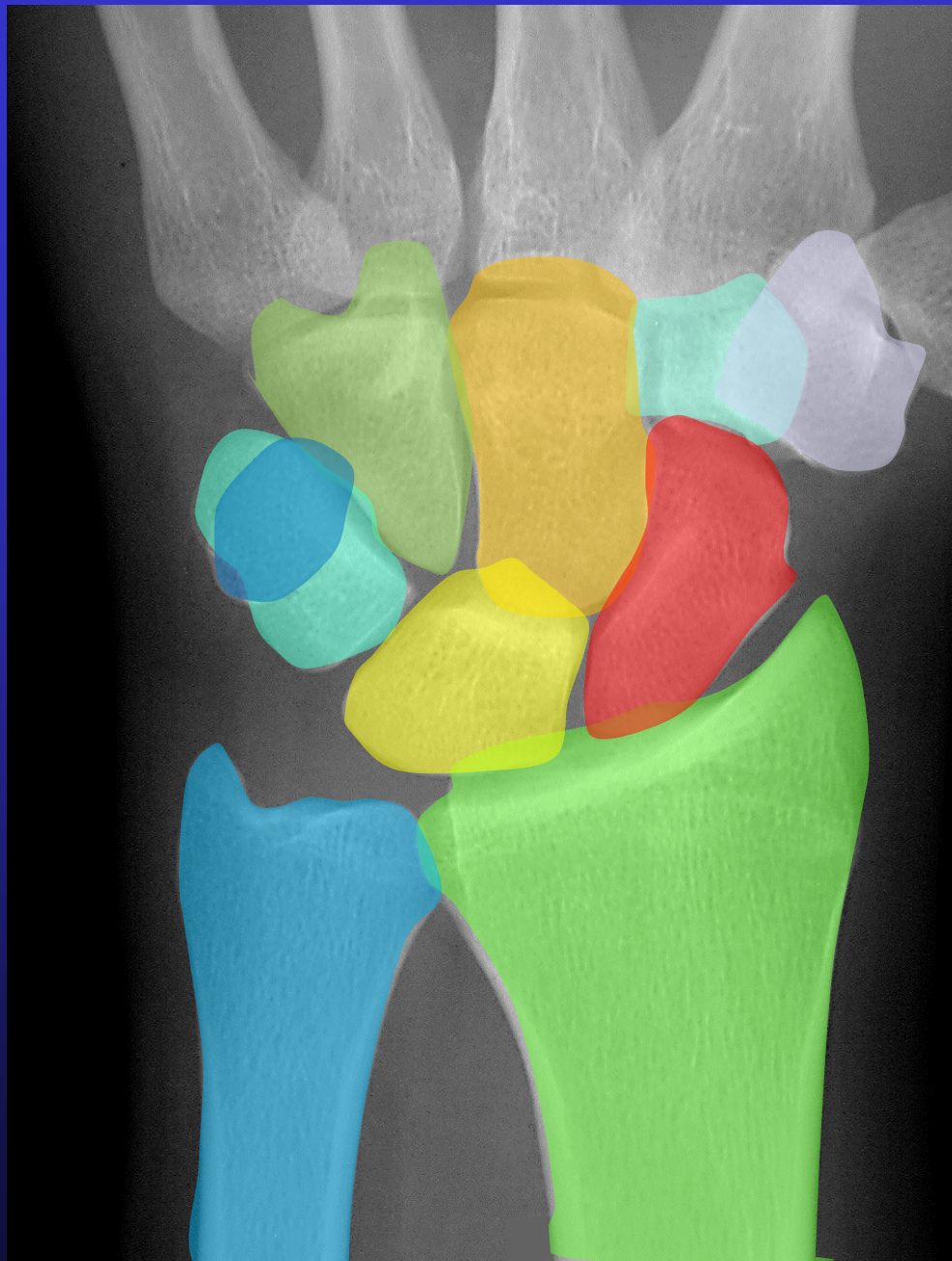
Dr Stuart Myers

Orthopaedic Hand Surgeon,
Prince of Wales Hospital, Sydney
Sydney Orthopaedic Specialists

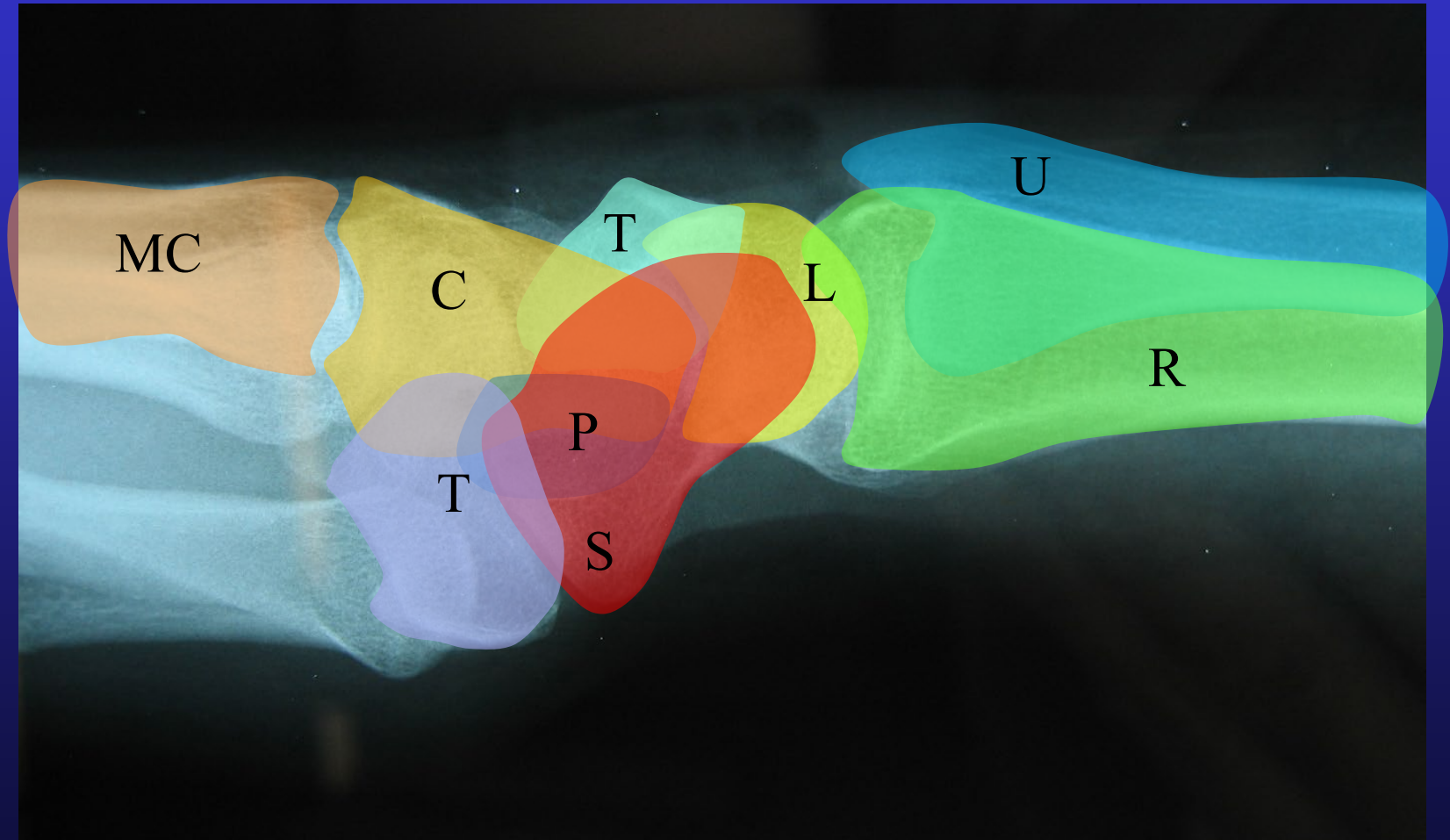
www.myhand.com.au







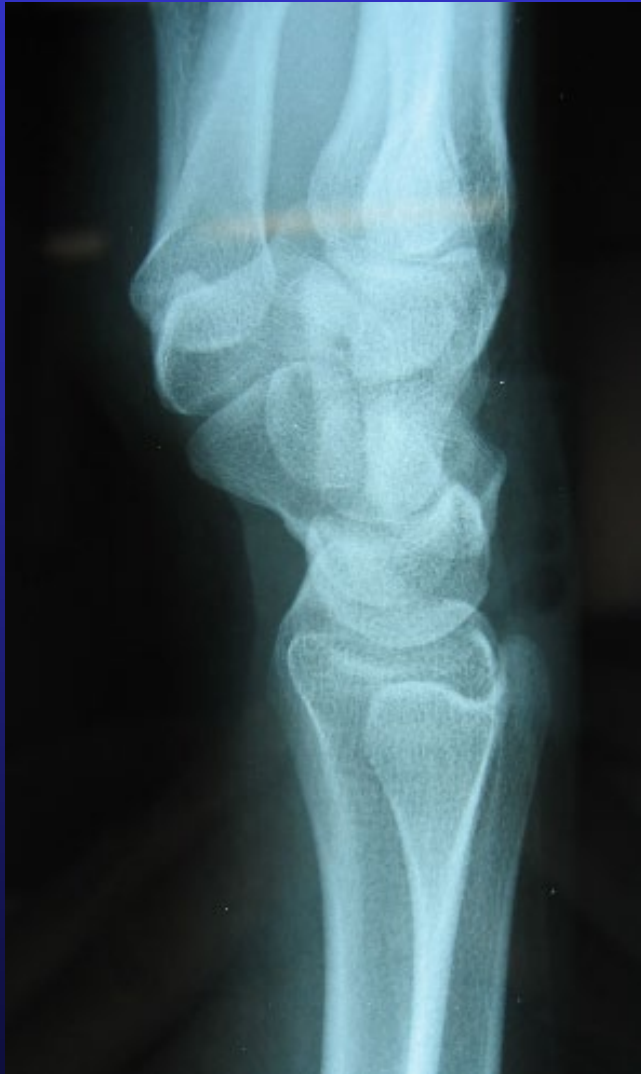
Carpal bones



Carpal bones

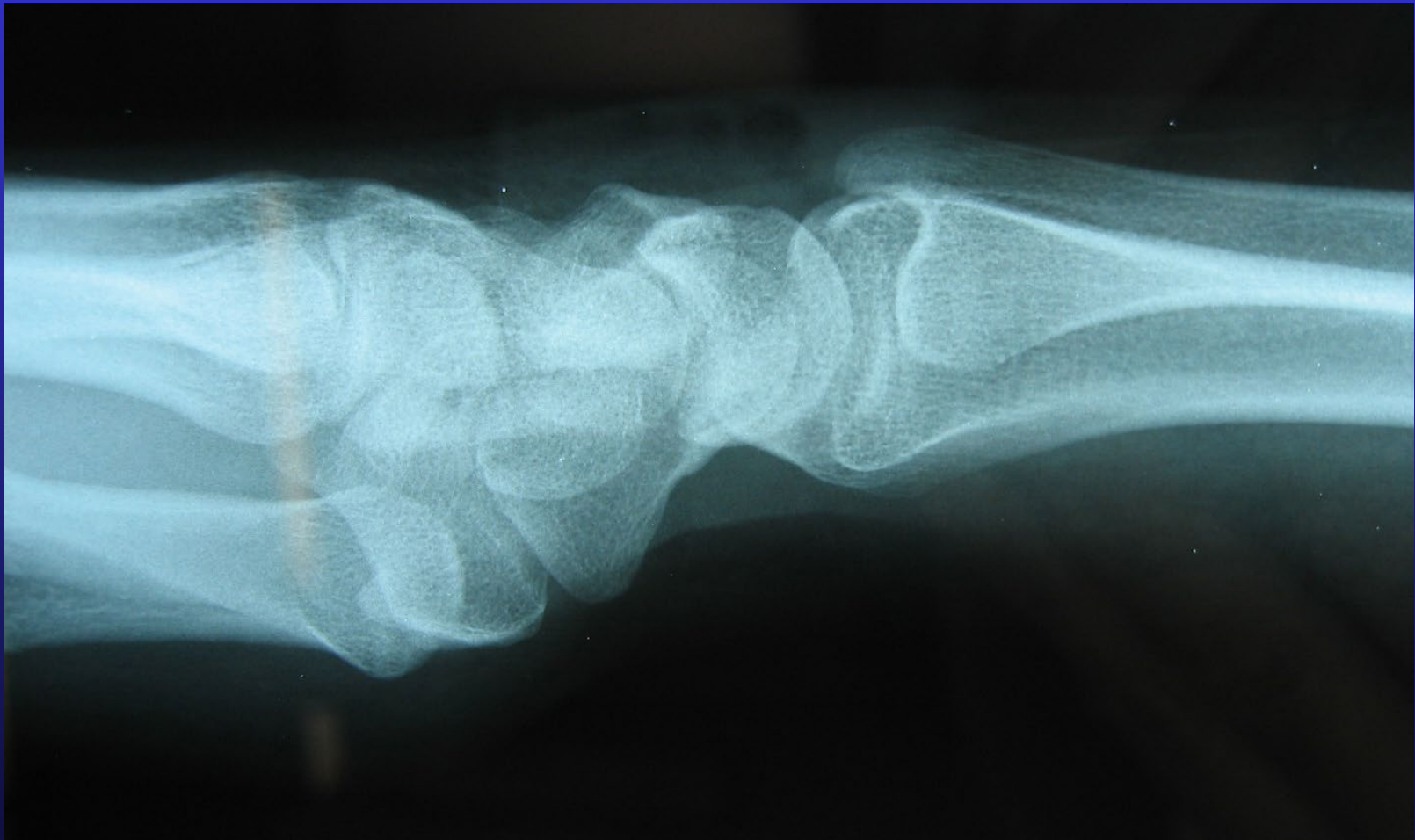

Lateral Views

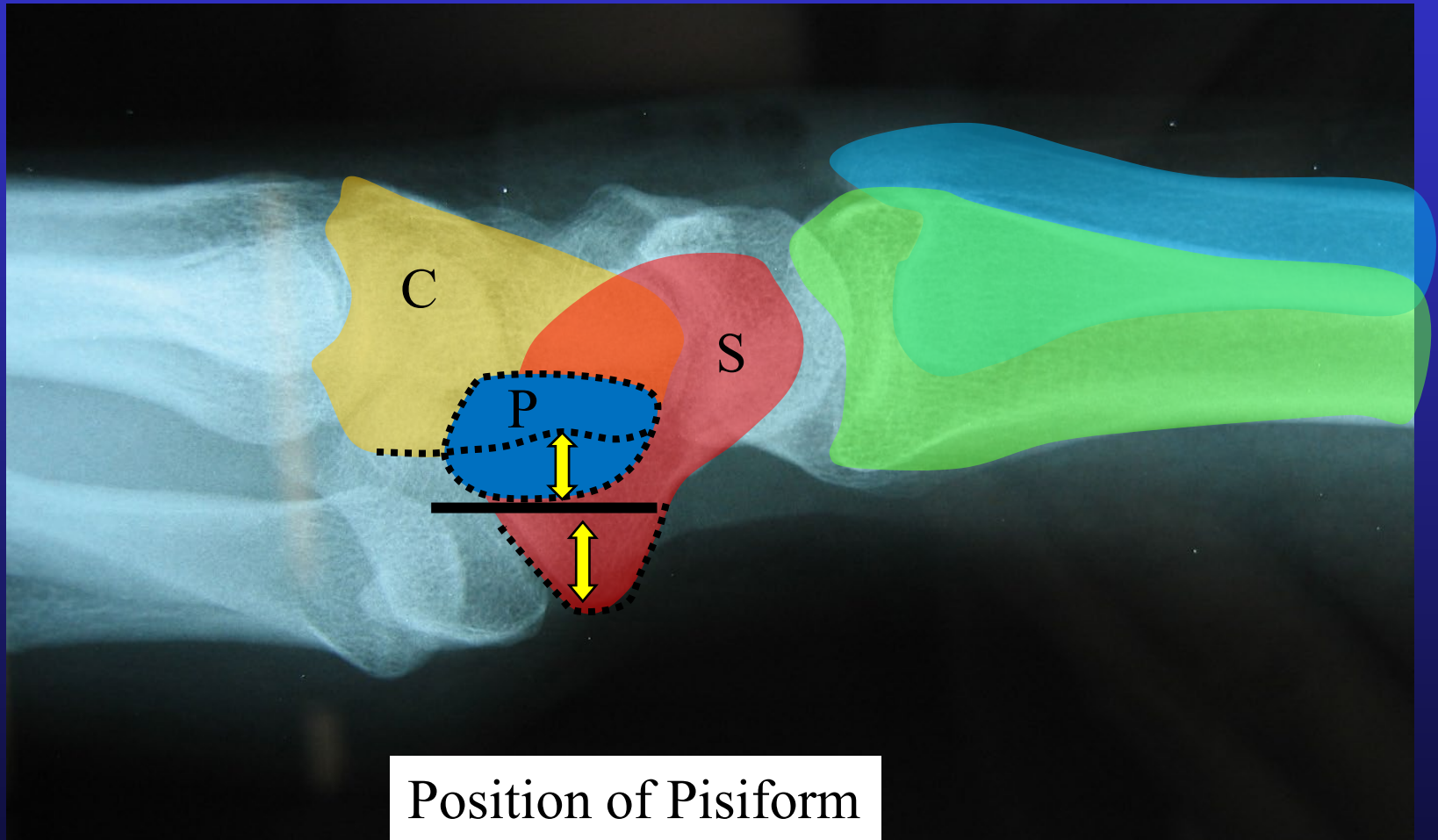


- Measure Scapholunate & Radio-lunate angles
- Neutral wrist deviation
- Middle metacarpal in line with radius
- Position Pisiform

Lateral Views

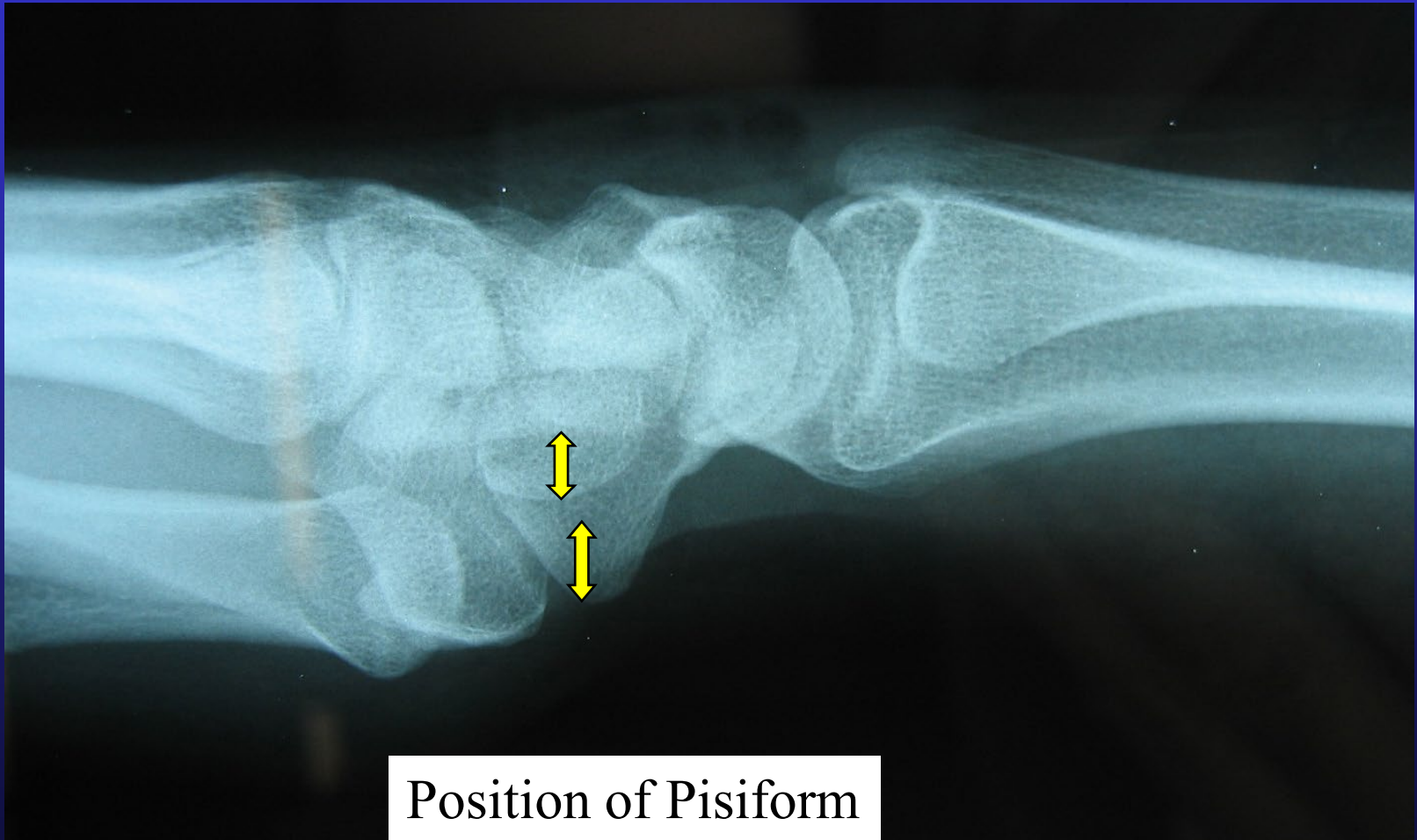

“True Lateral”



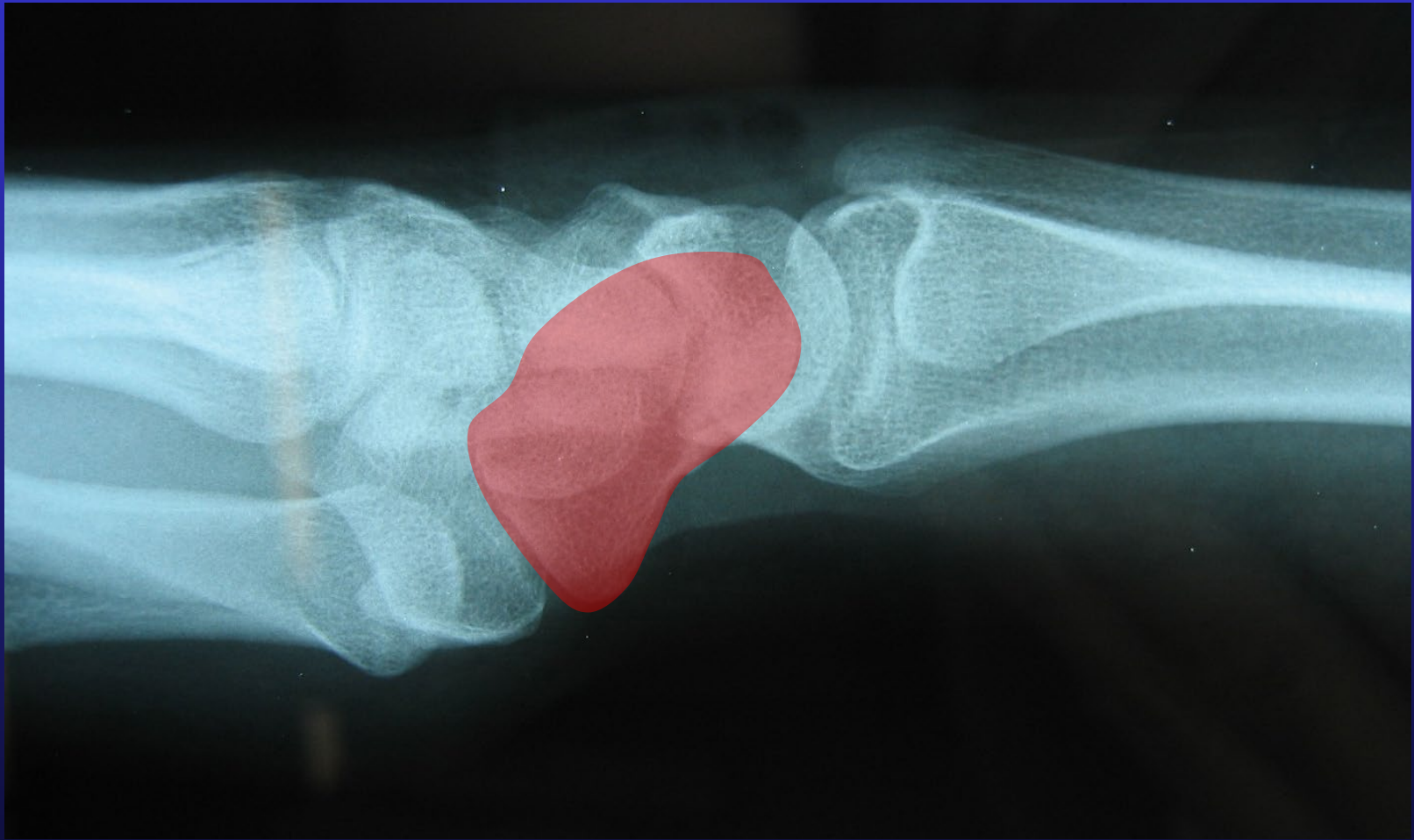
Position of Pisiform

“True Lateral”

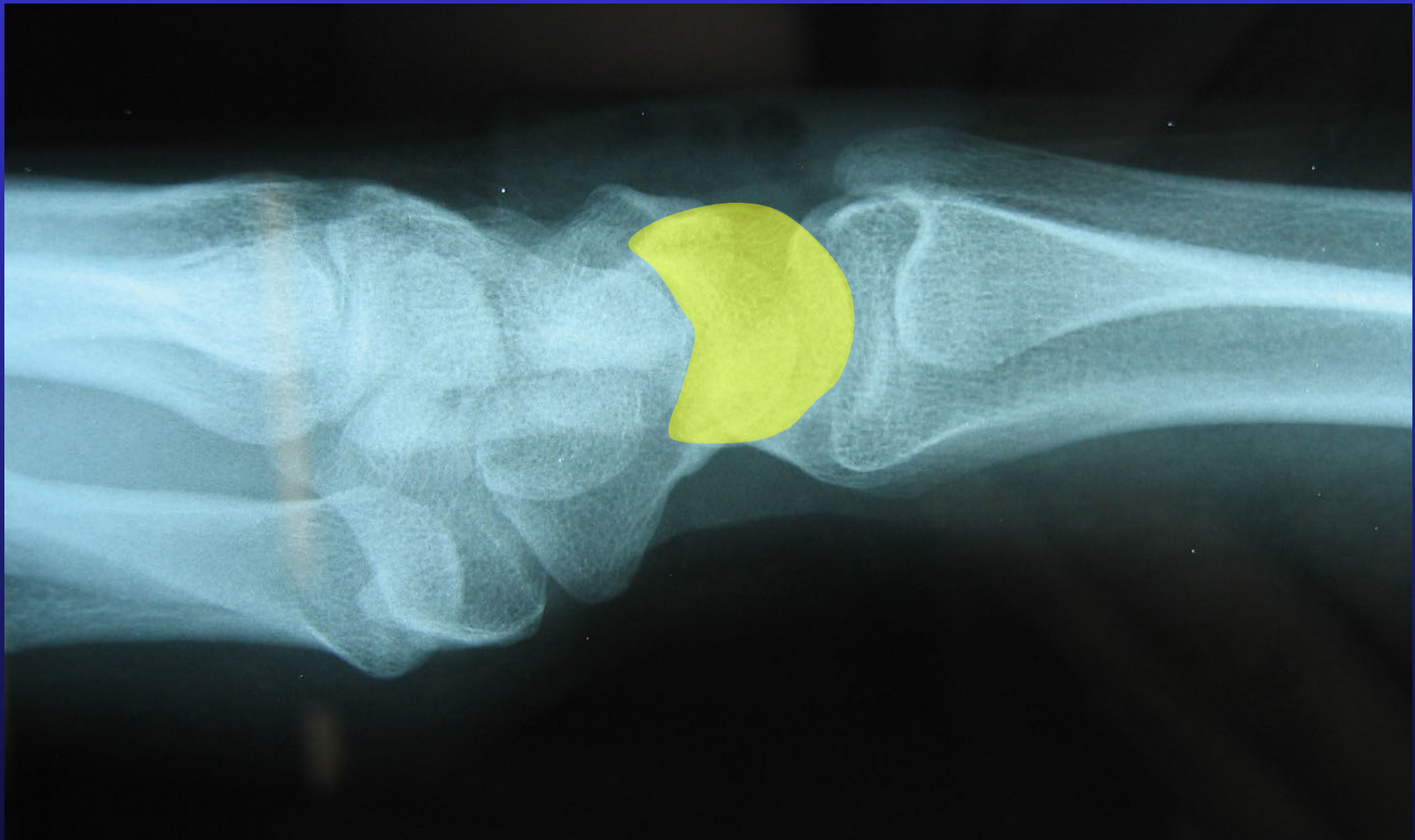


Position of Pisiform

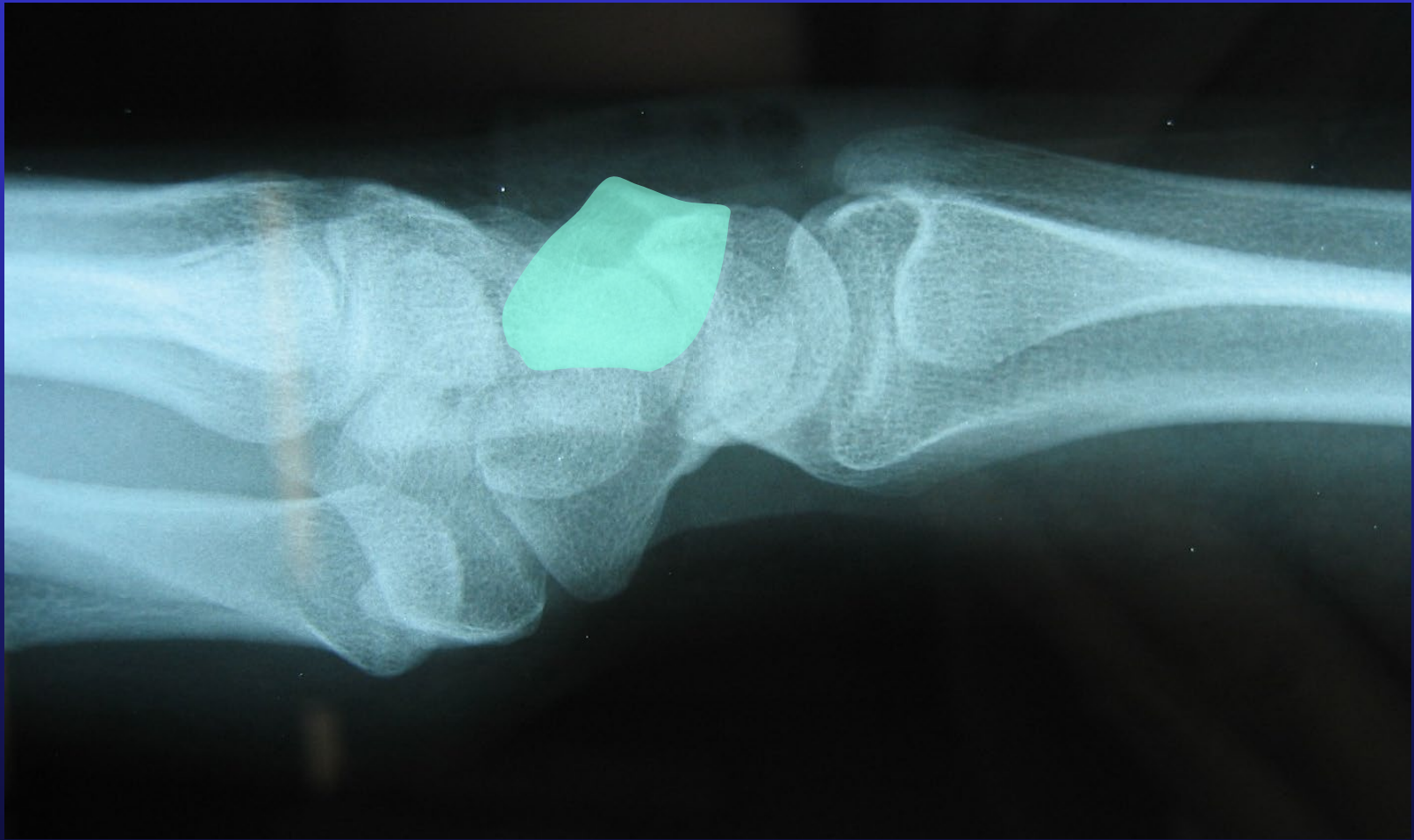Scaphoid



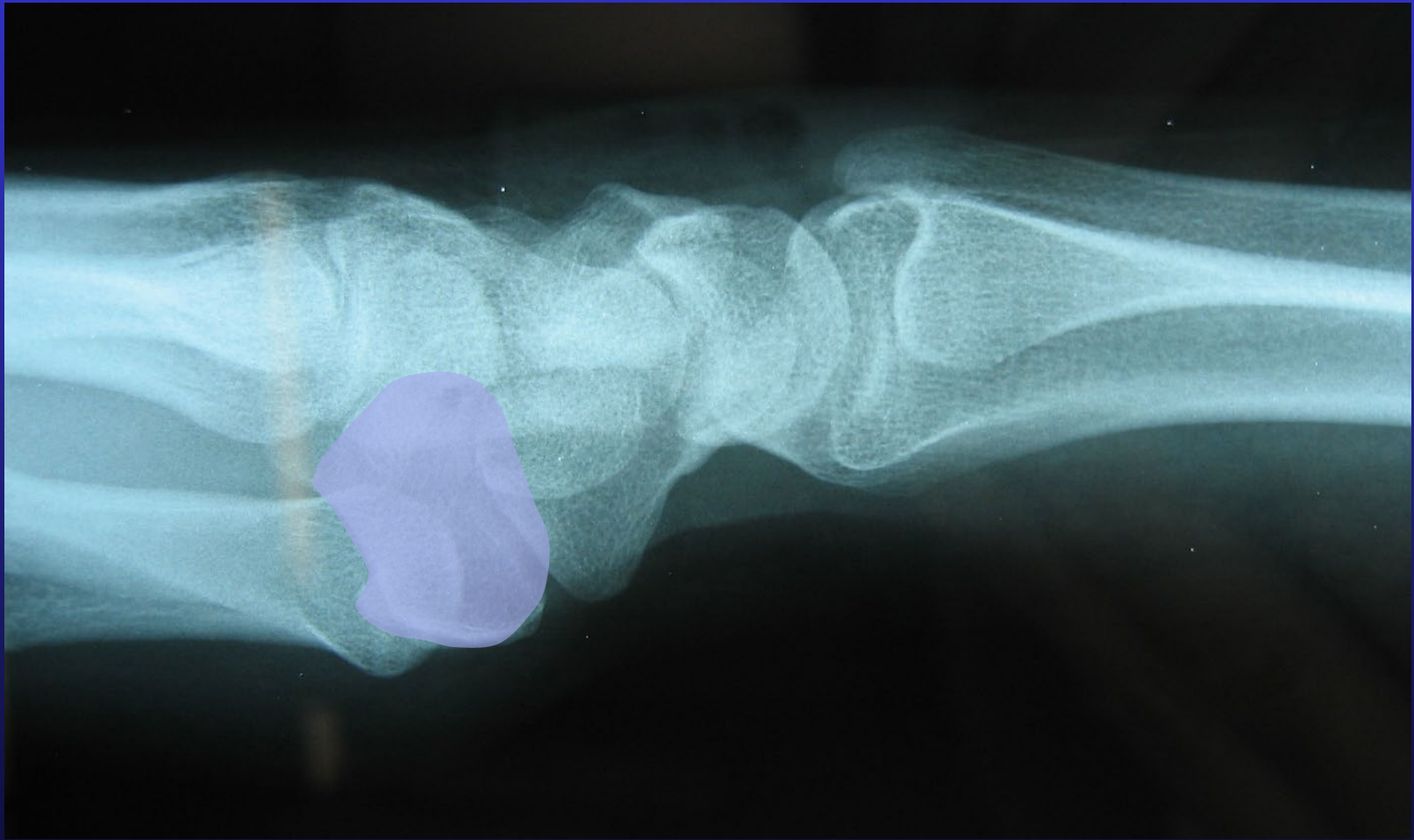
Lunate



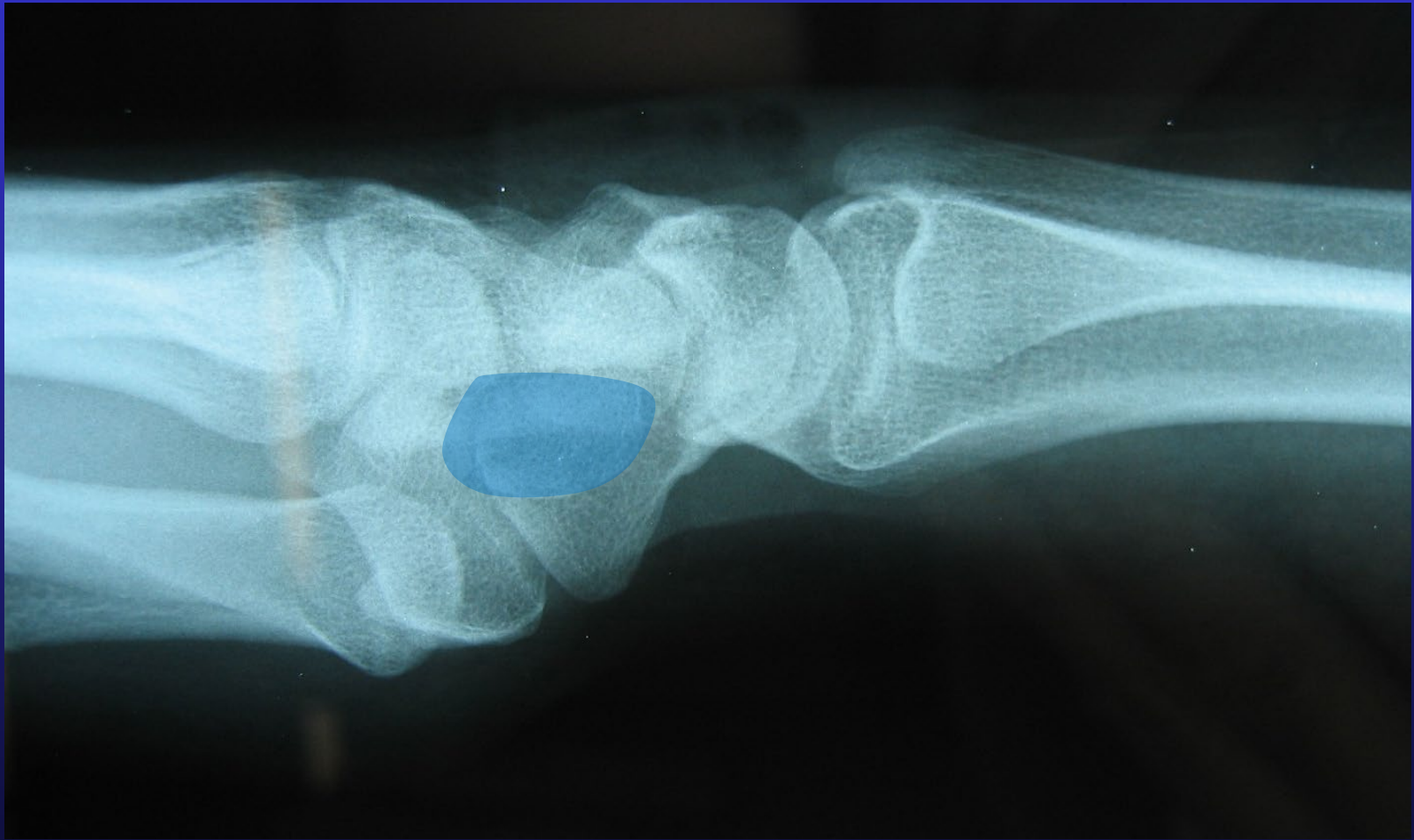Triquetrum



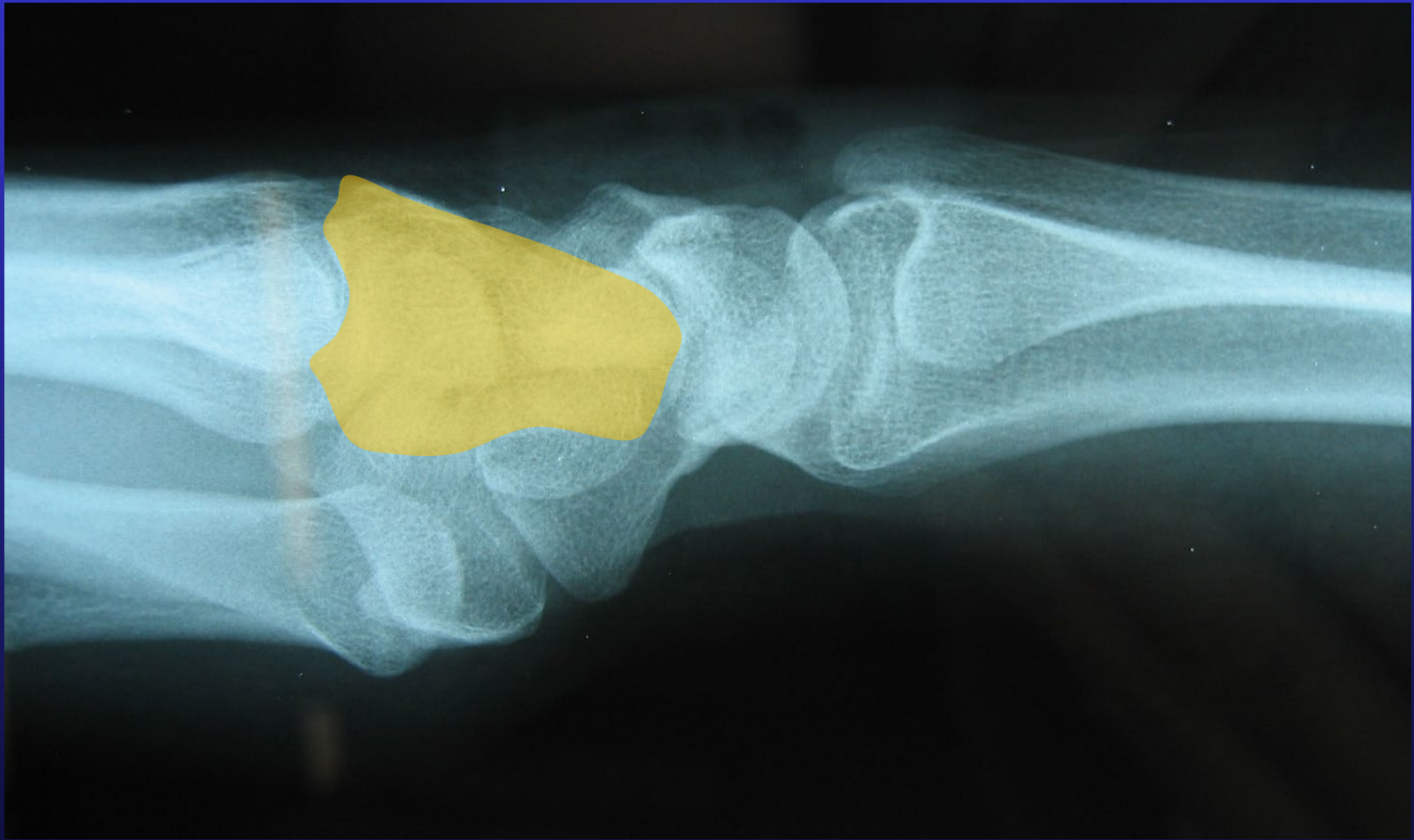Trapezium



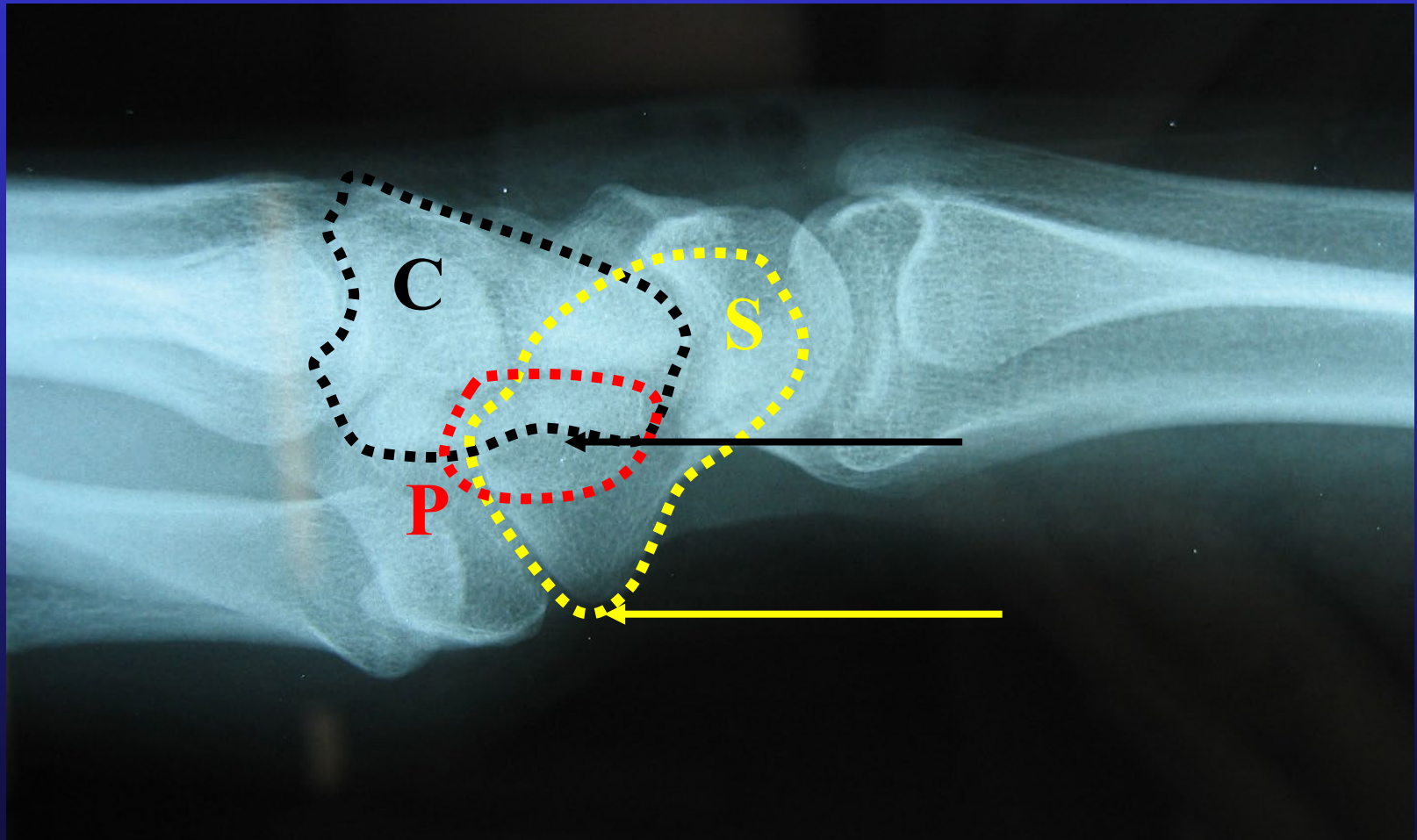
Pisiform



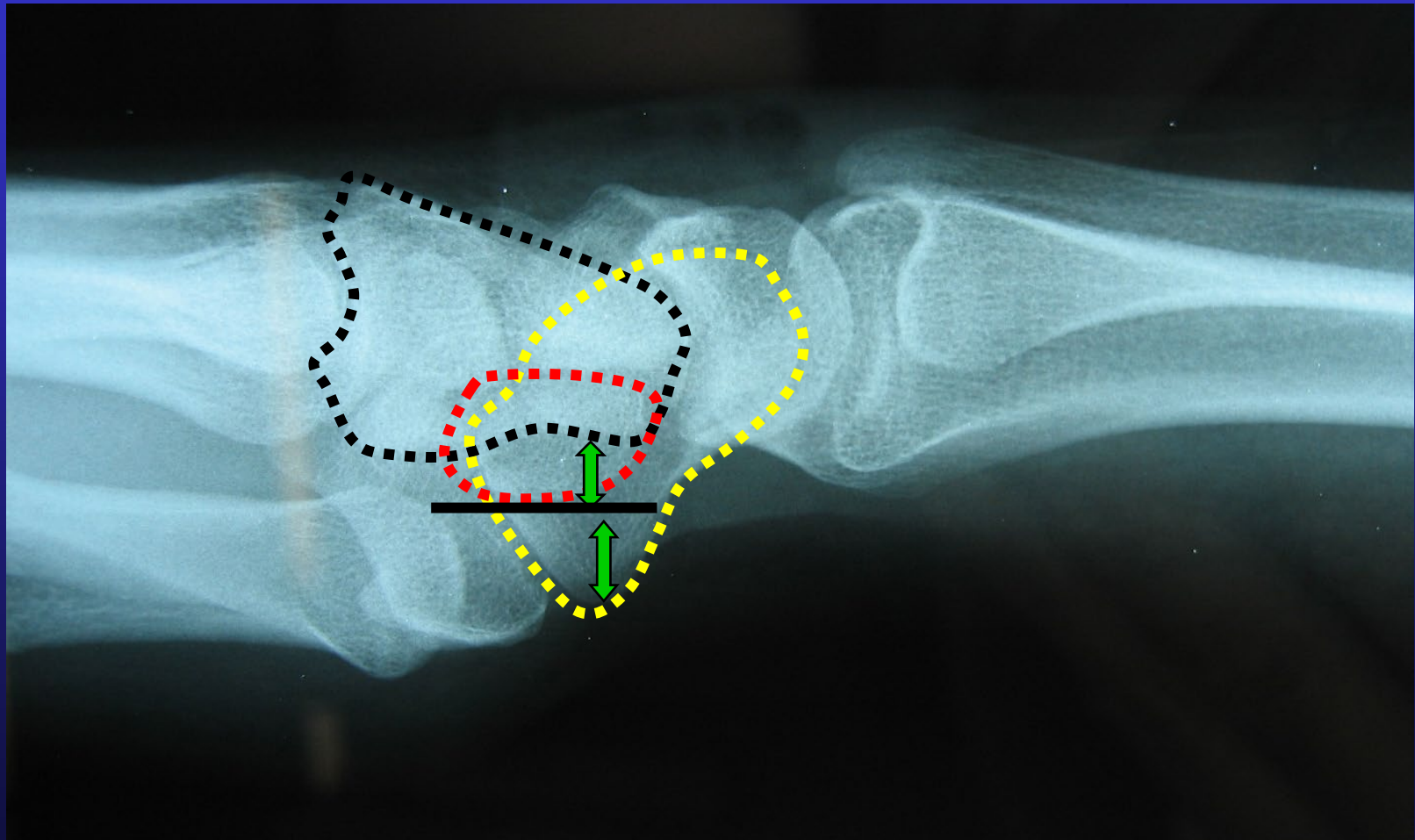
Capitate



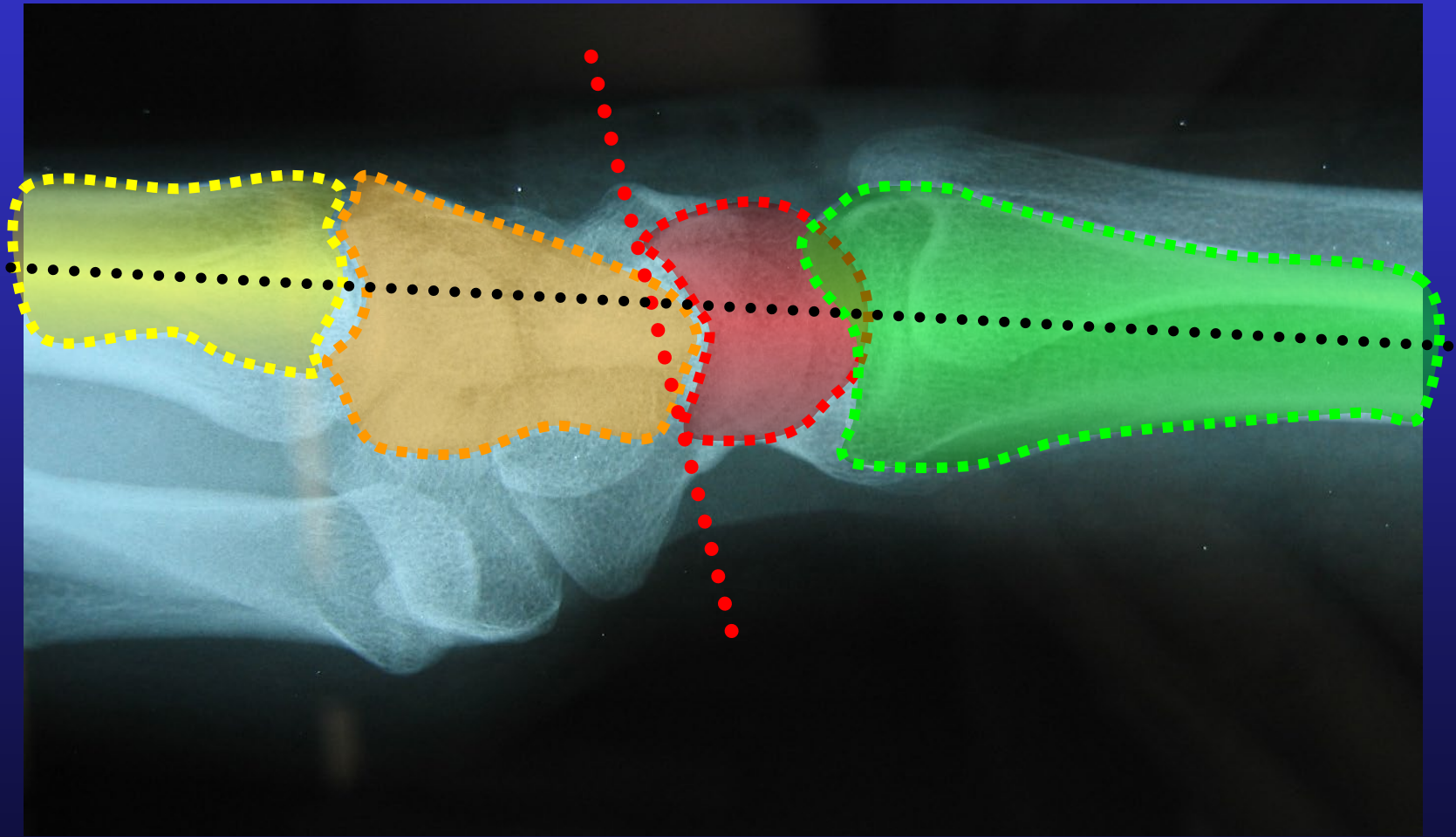
True Lateral



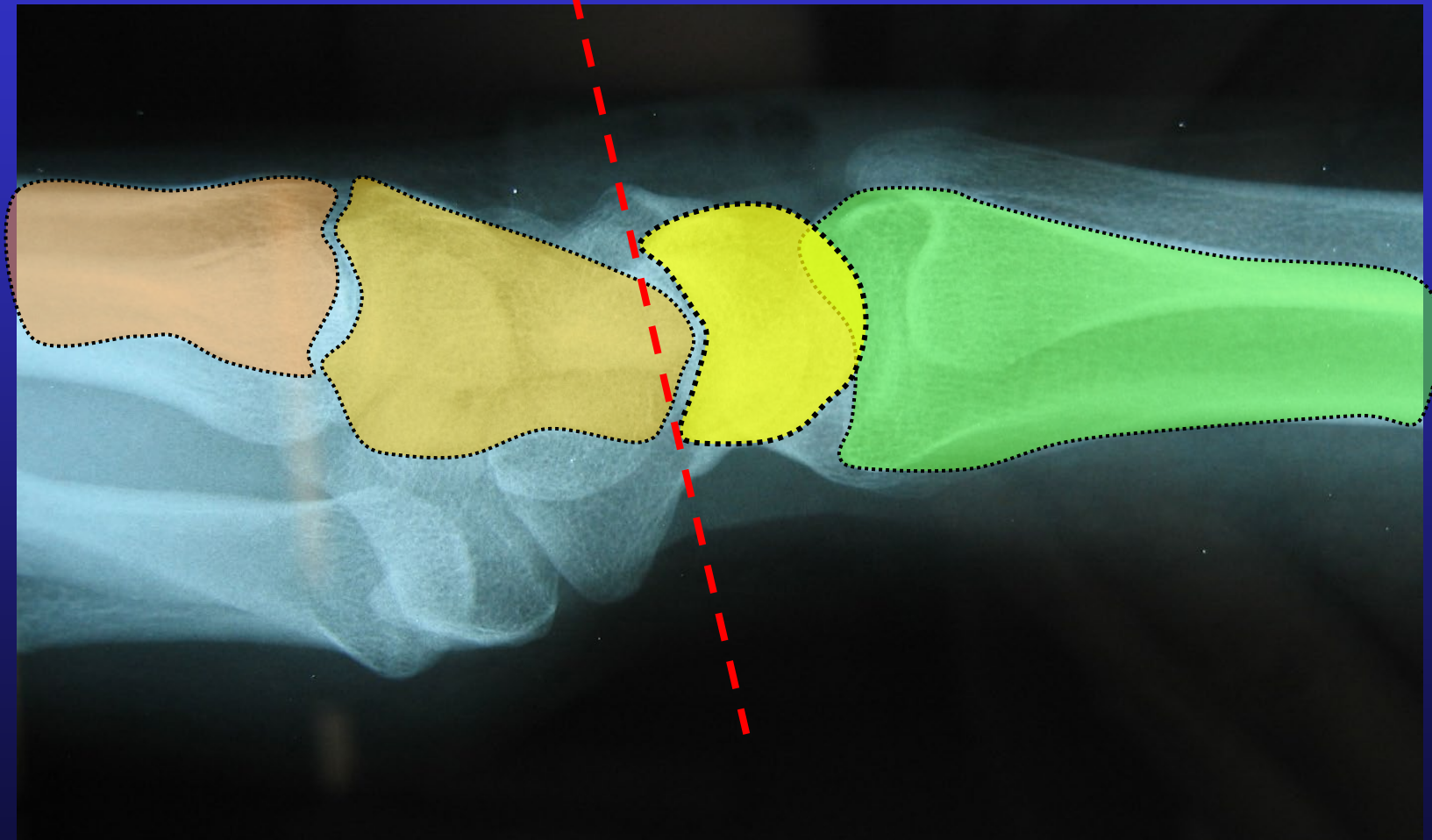
True Lateral



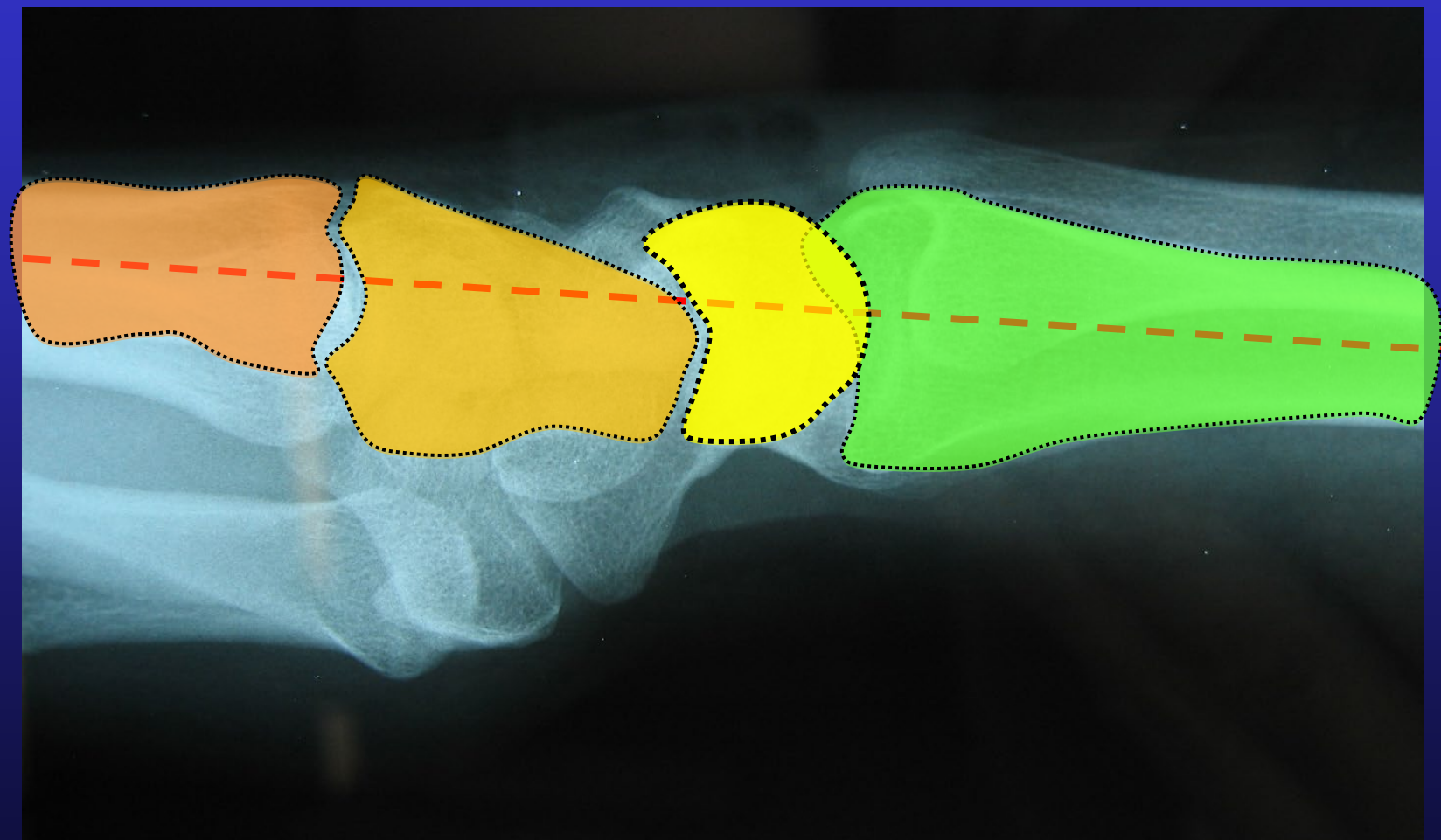
Lunate



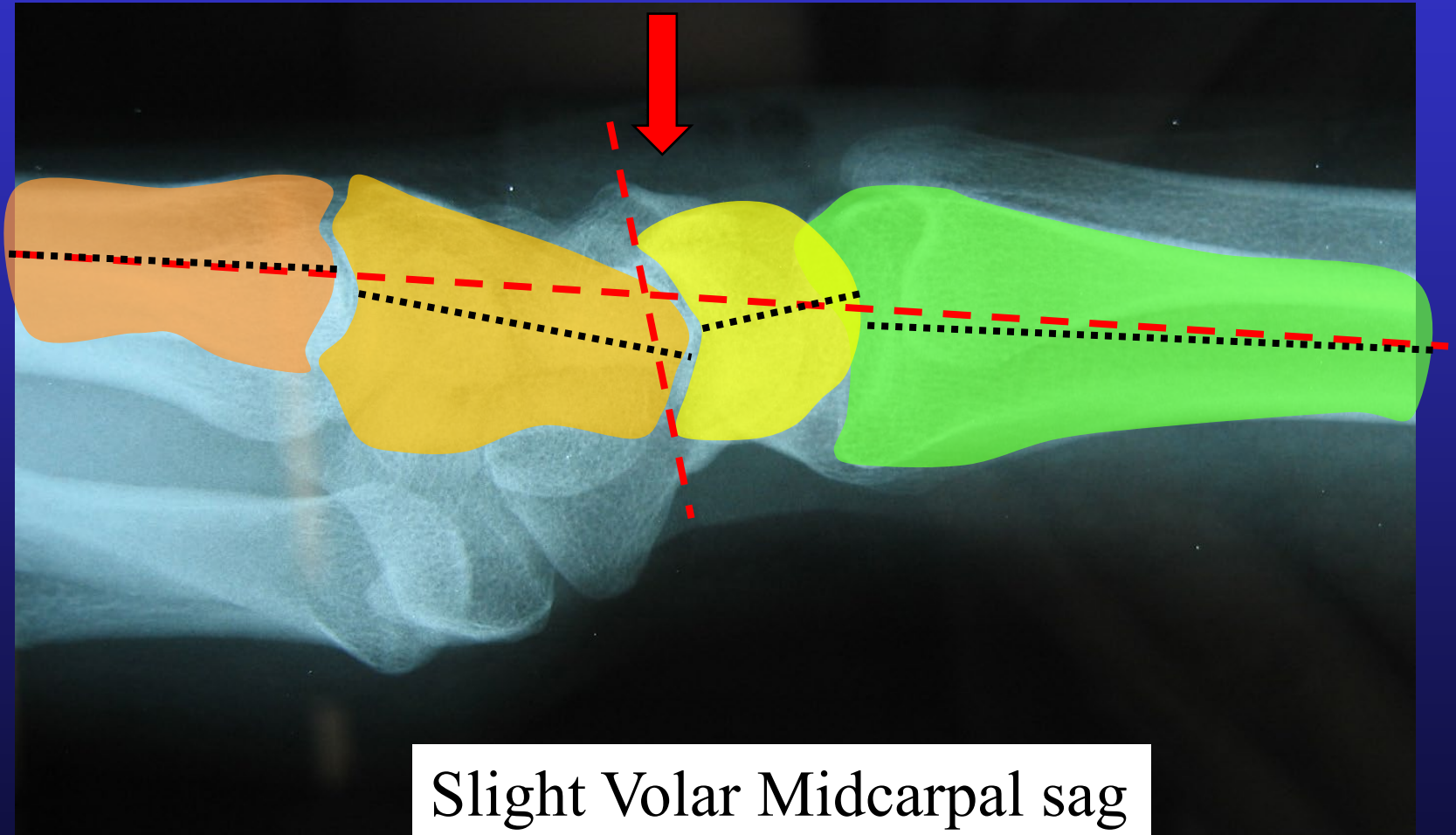
Lunate



Lunate

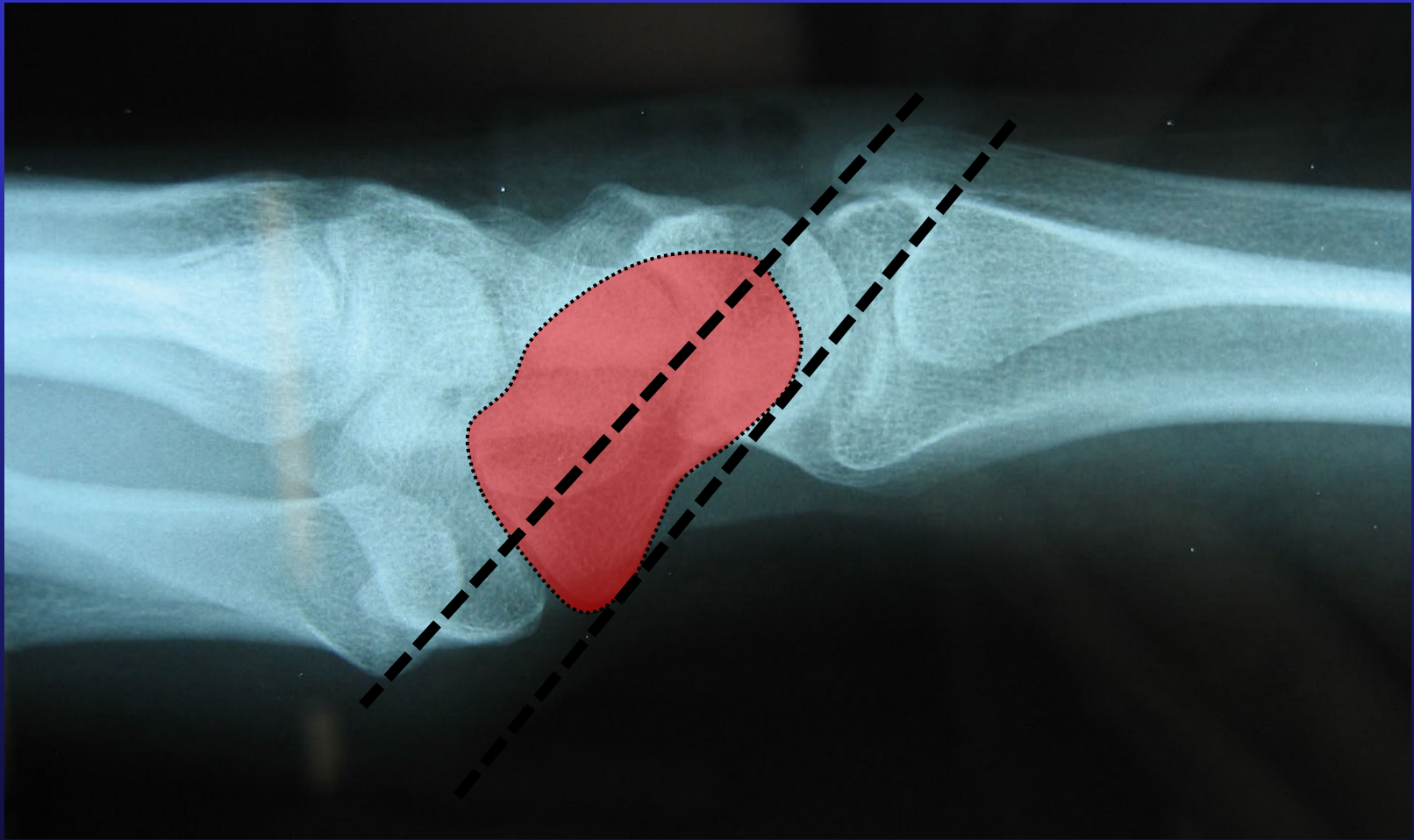


Lunate

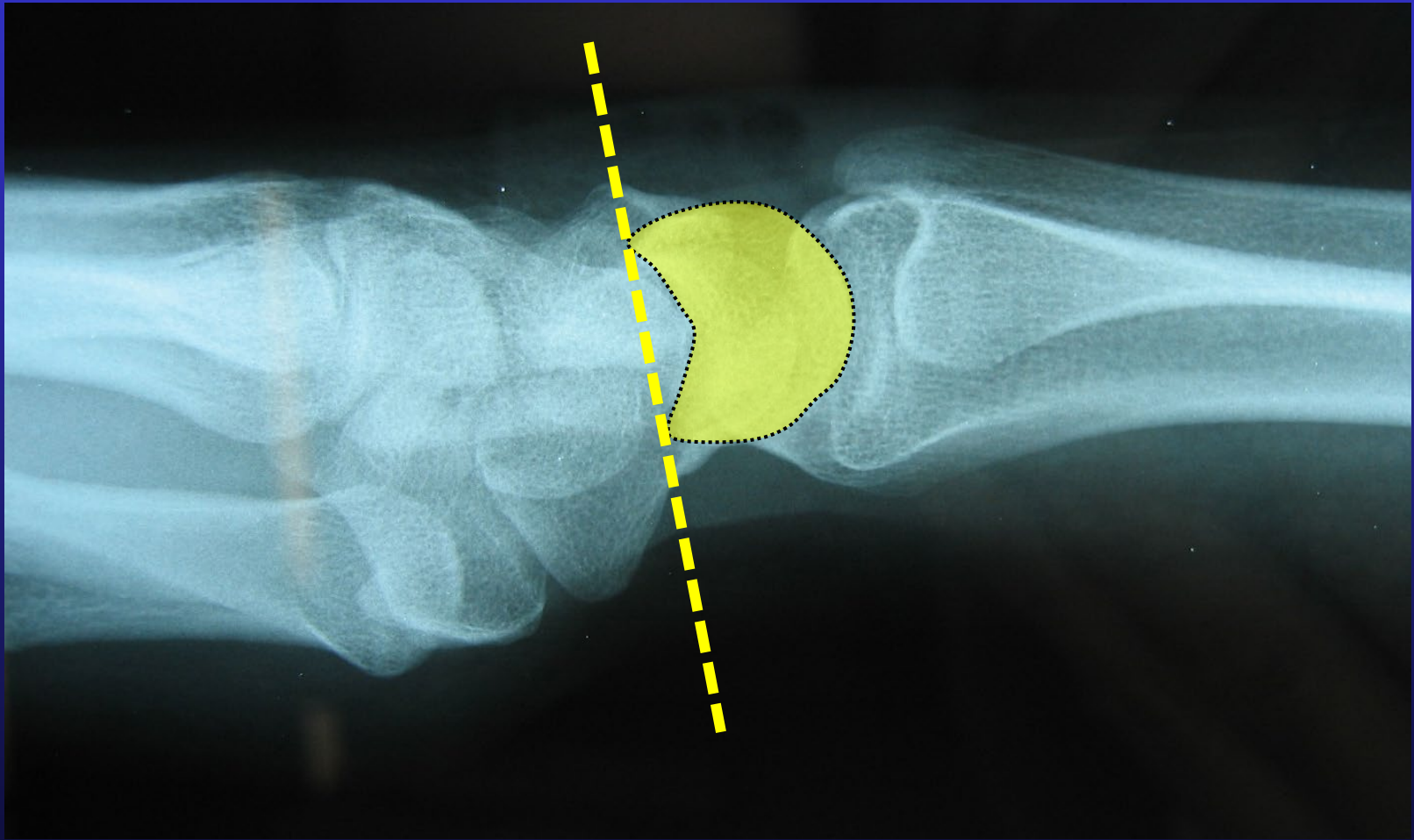


Slight Volar Midcarpal sag

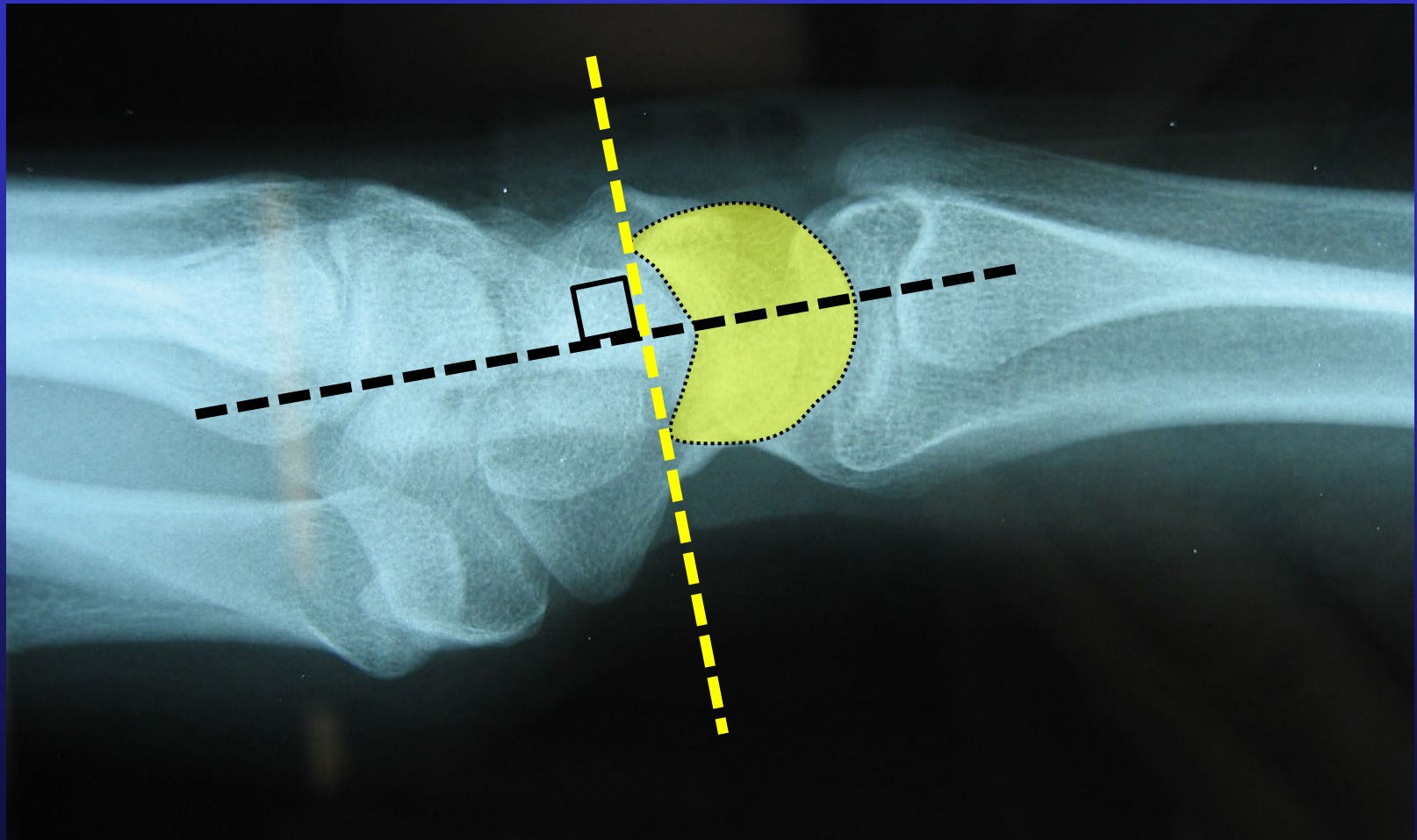
Scaphoid alignment



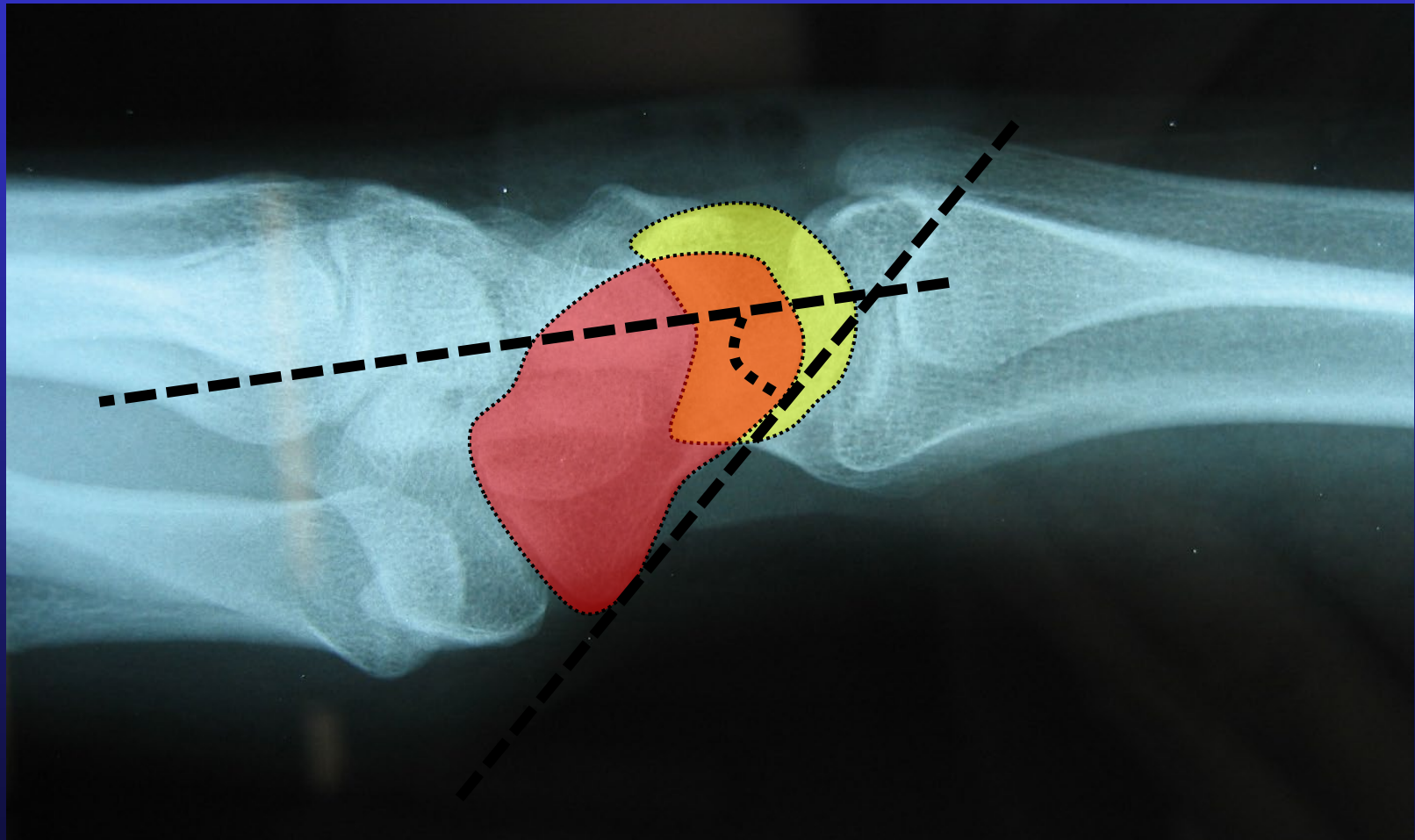
Lunate Alignment



Lunate Alignment



Scapho-lunate angle



Lateral Xray

Scapolunate Angle

