

Wrist Xrays-

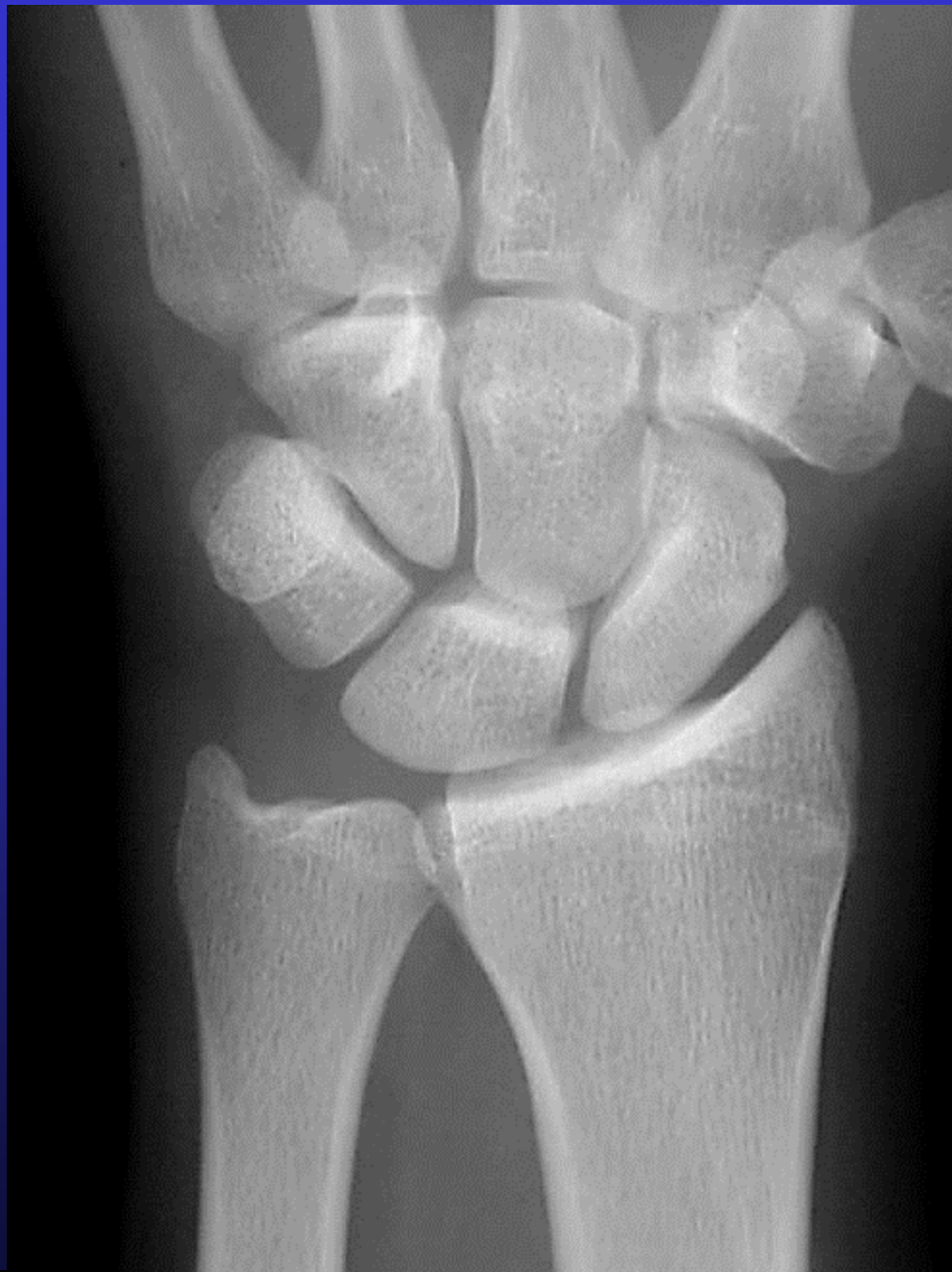A Hand Surgeons Perspective

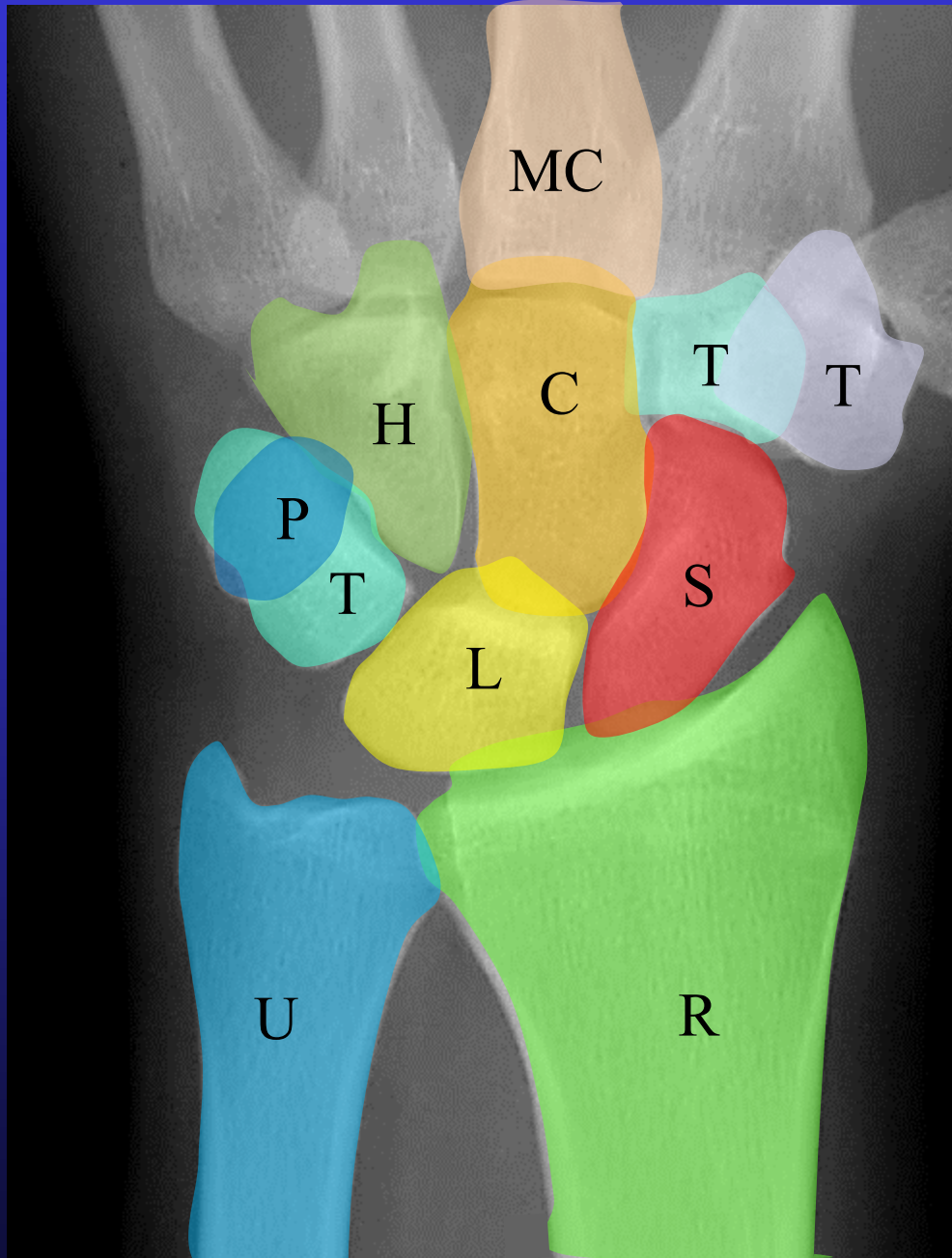
Dr Stuart Myers

Orthopaedic Hand Surgeon,
Prince of Wales Hospital, Sydney
Sydney Orthopaedic Specialists

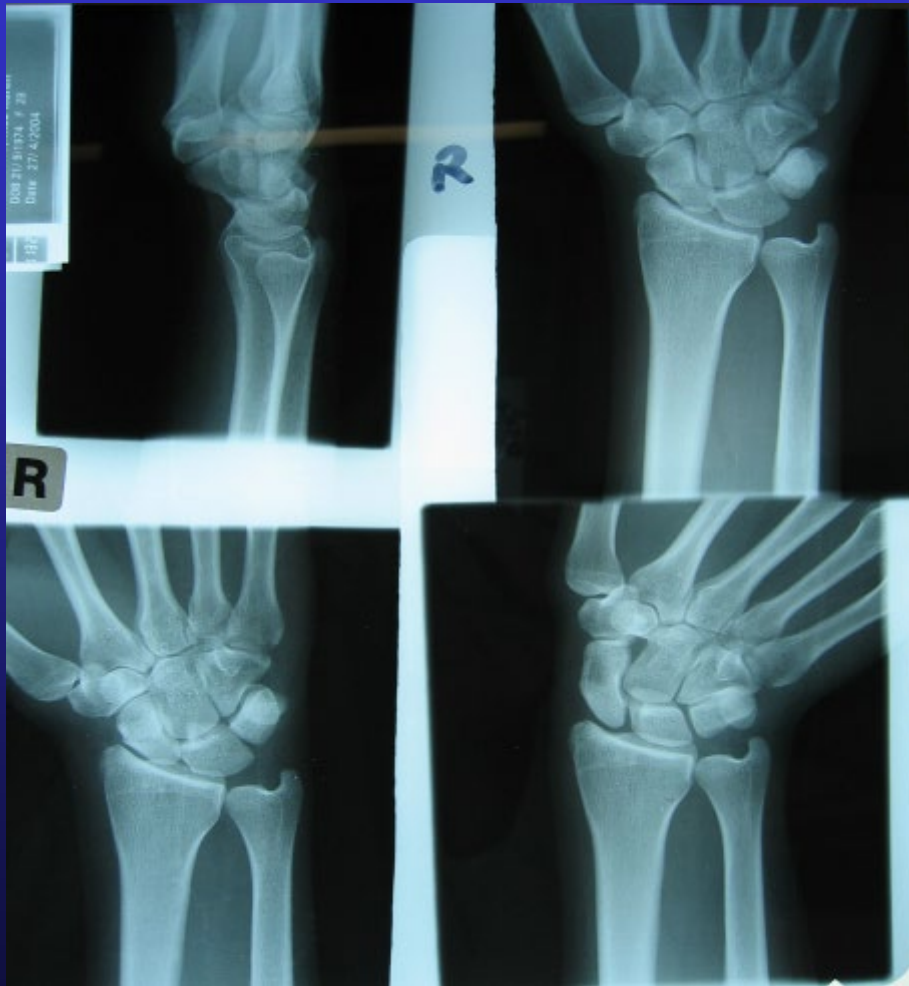www.myhand.com.au



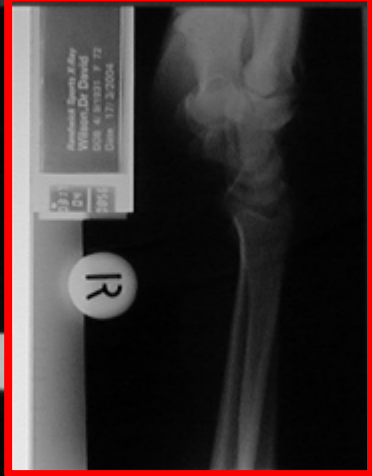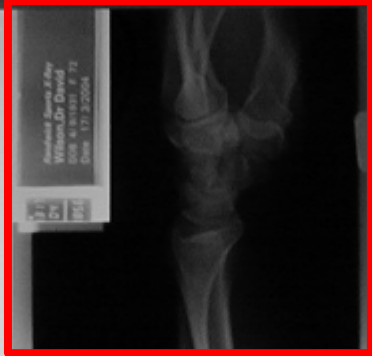




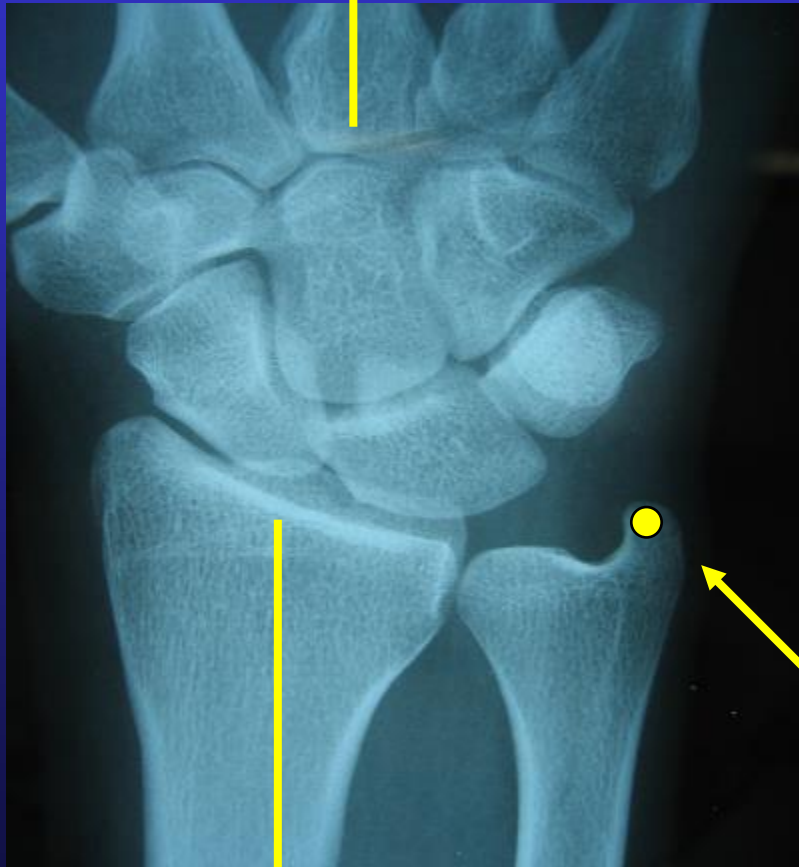Wrist Instability Views (“WIV”)



- These views are taken to look for **subtle changes** in carpal alignment due to ligament injuries.
- Attention to detail is critical
- 4 views are performed on 1 Xray for each wrist in the same order to allow comparison with the other side

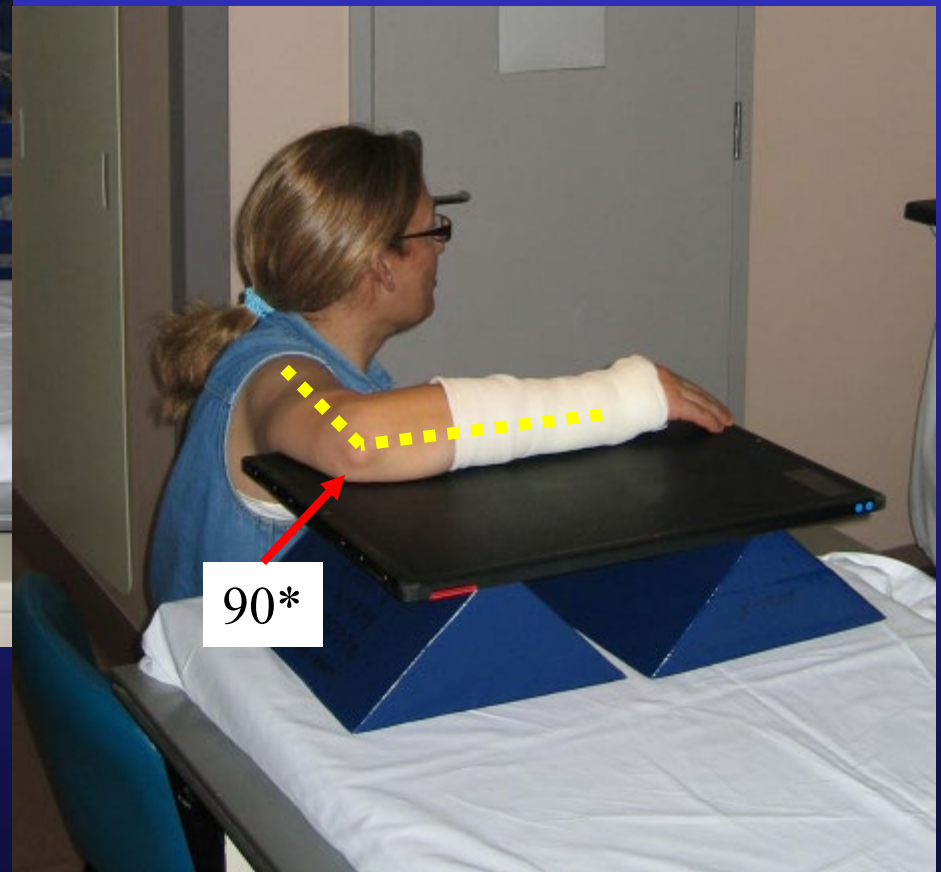
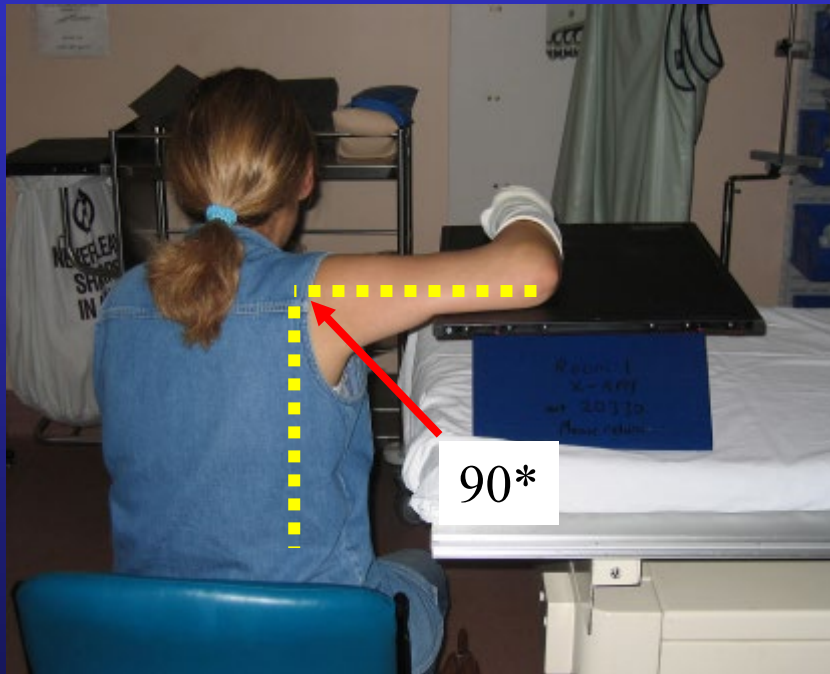


PA View

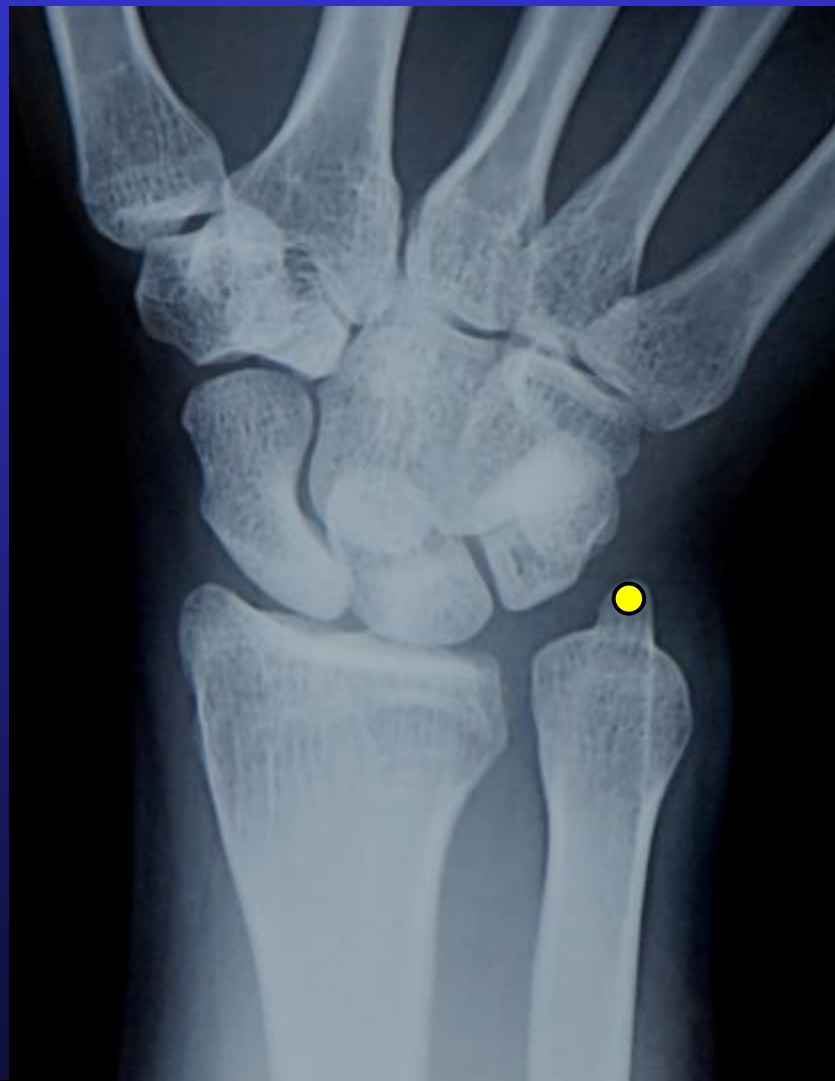
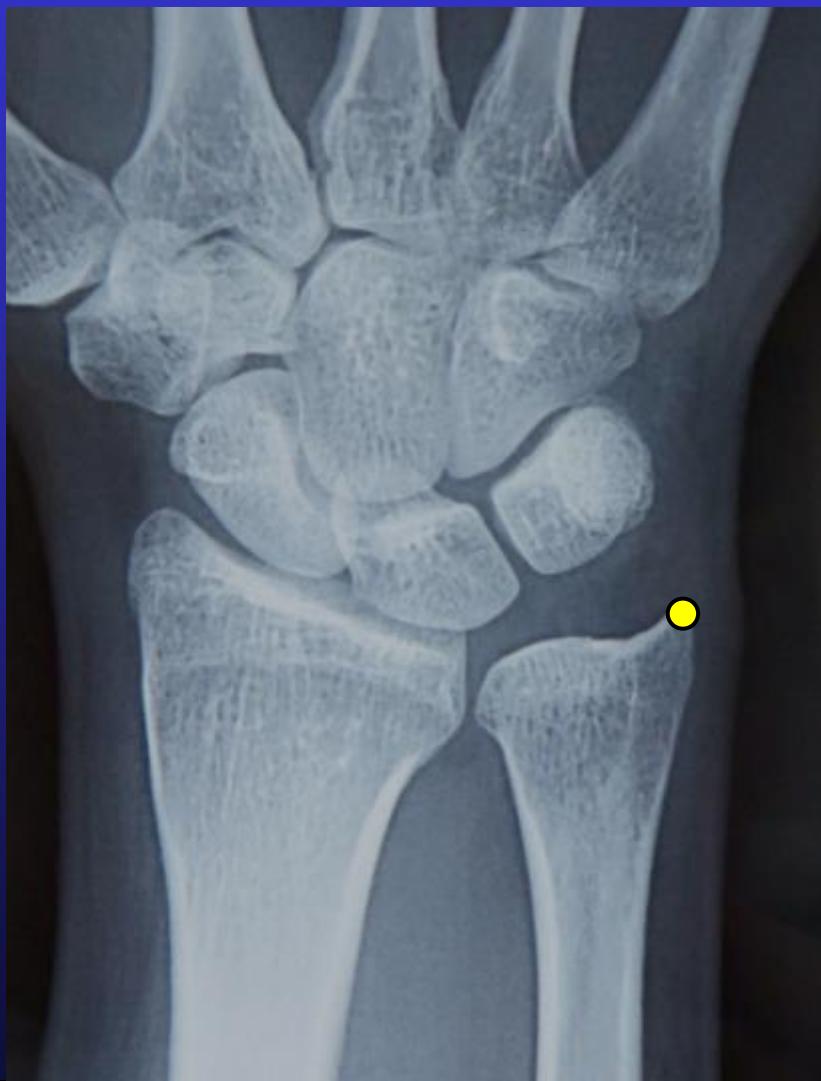
- PA view in neutral in 90 : 90 position
 - Radius in line with middle metacarpal
- Position of Ulna styloid

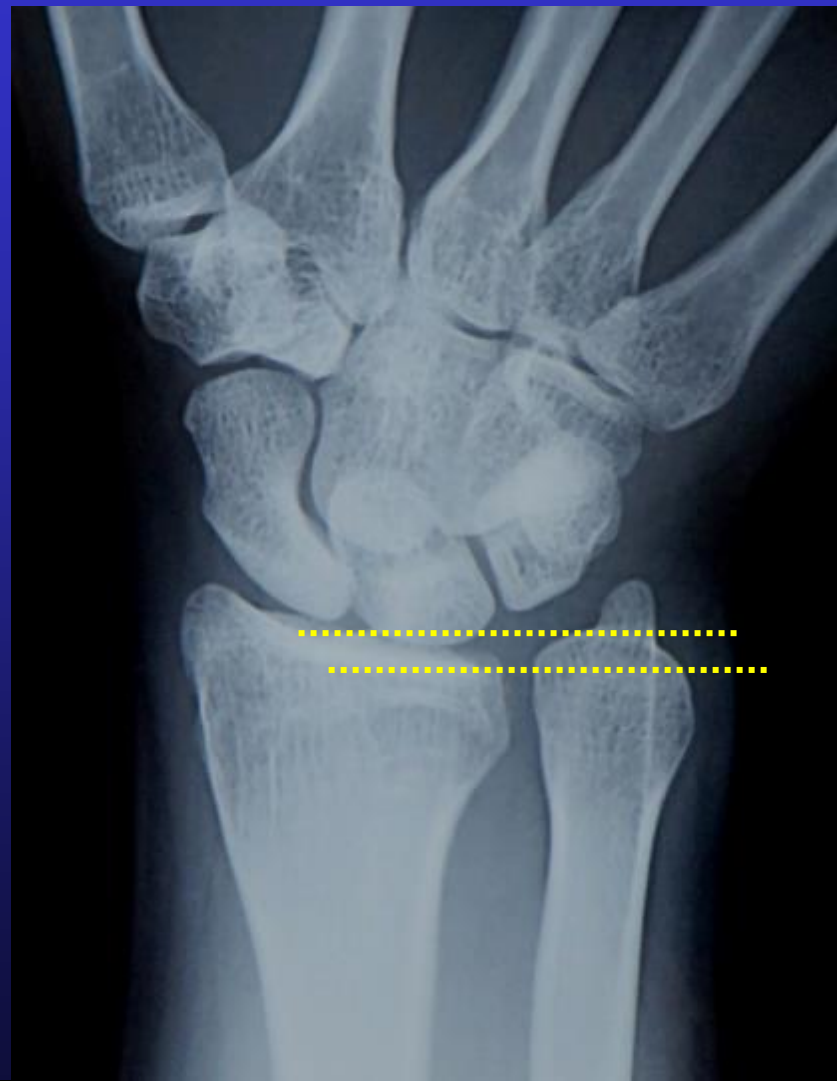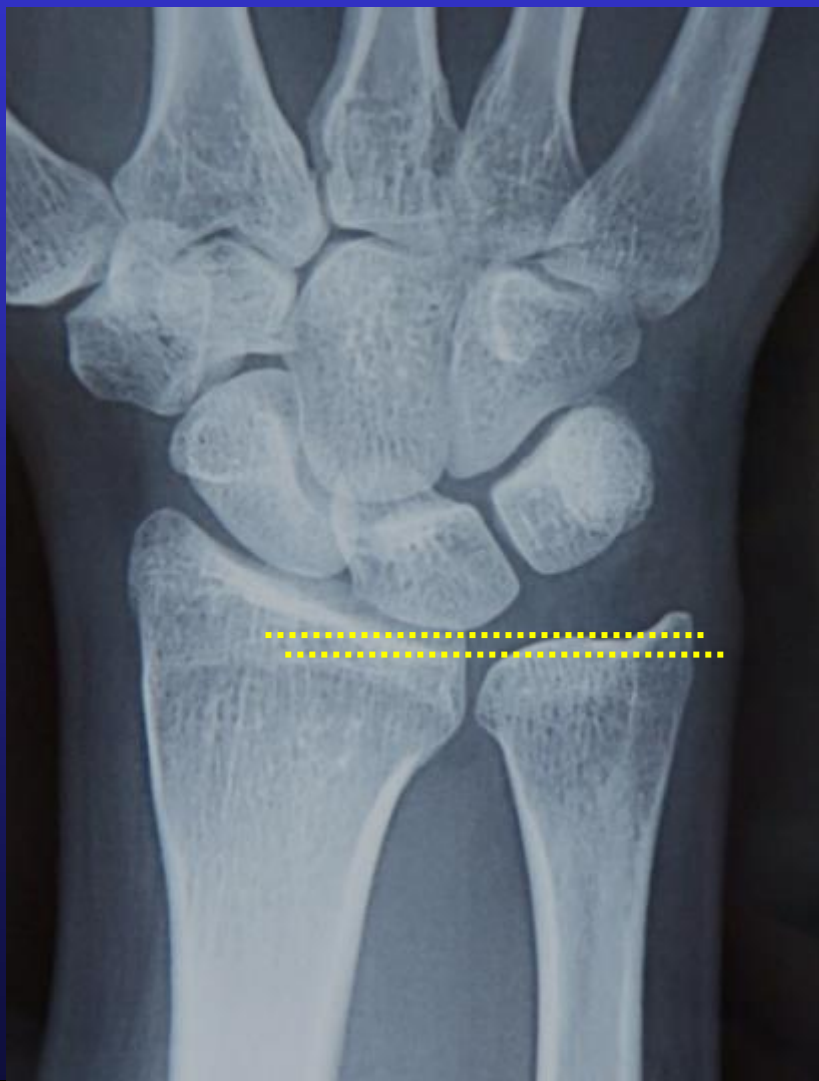90 : 90 Position




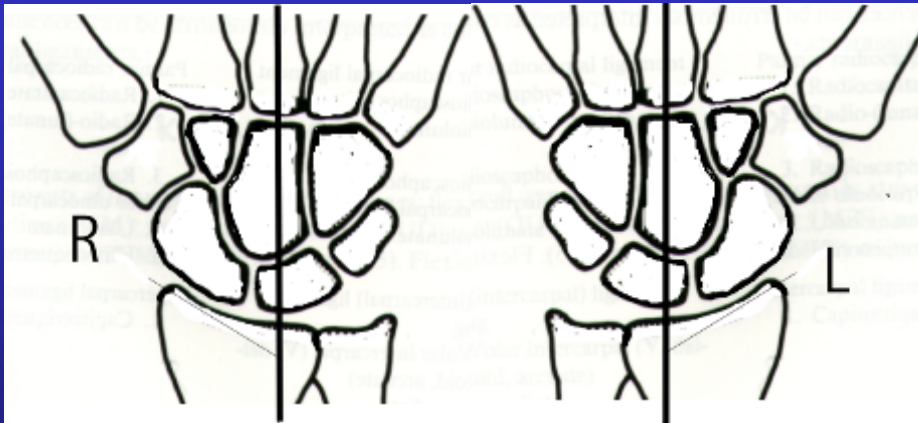
Same wrist!!



Same wrist!!

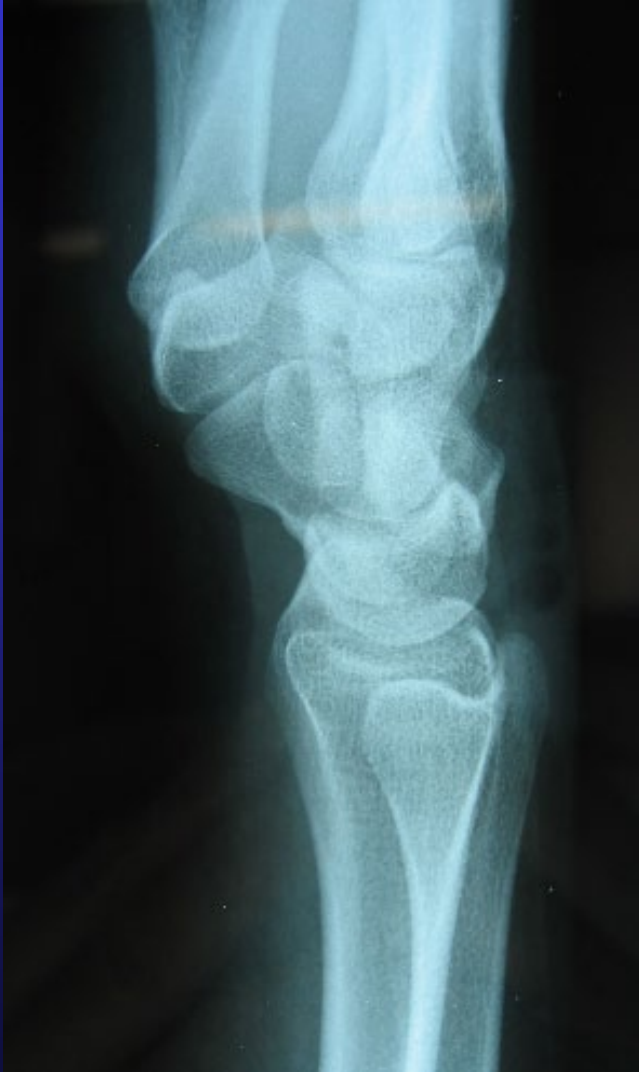

“90/90 Views”



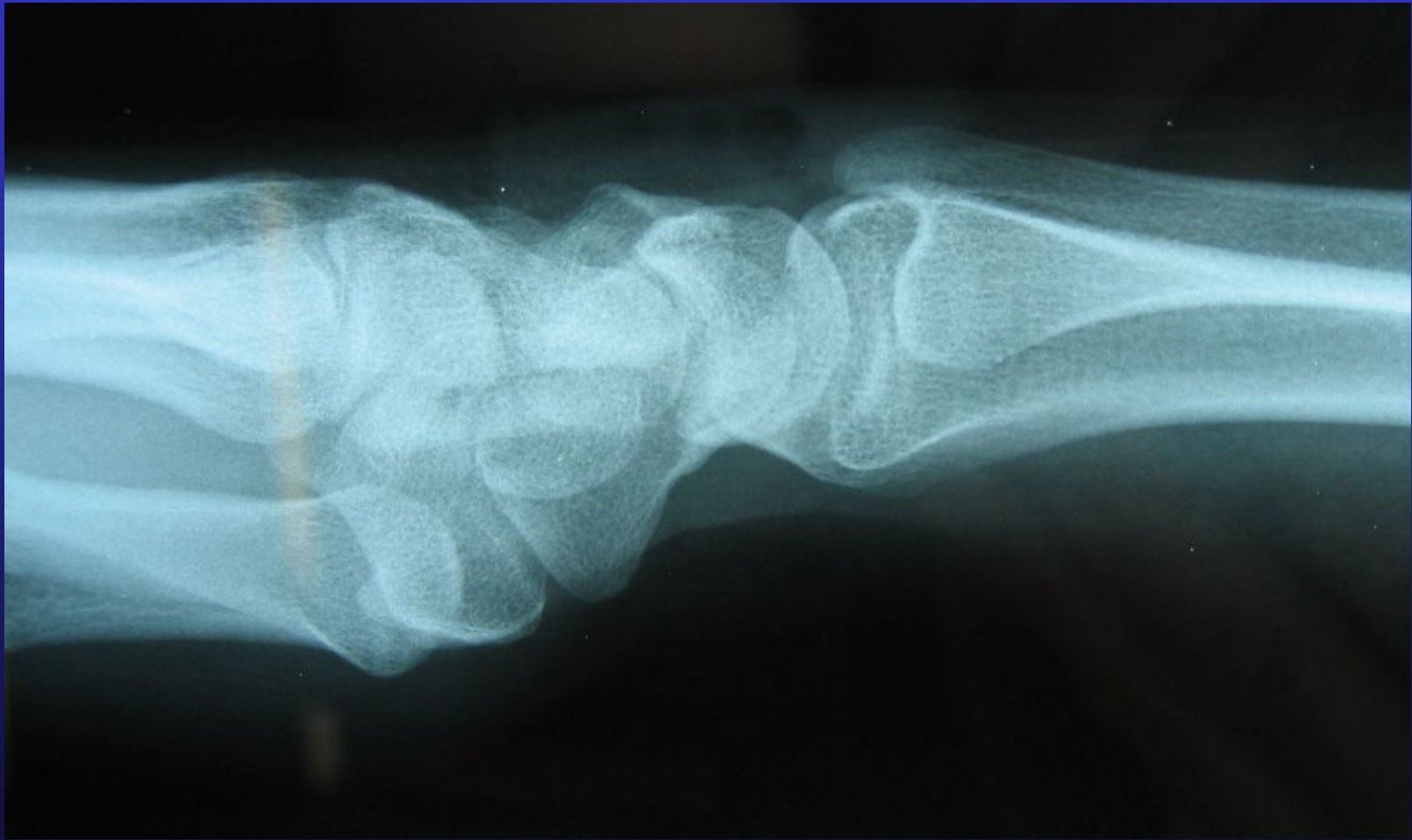- used to assess the relative lengths of the radius & Ulnar i.e. the “Ulnar Variance”
- Xray taken with:
 - Shoulder at 90*
 - elbow at 90*
 - forearm in neutral rotation

Lateral Views

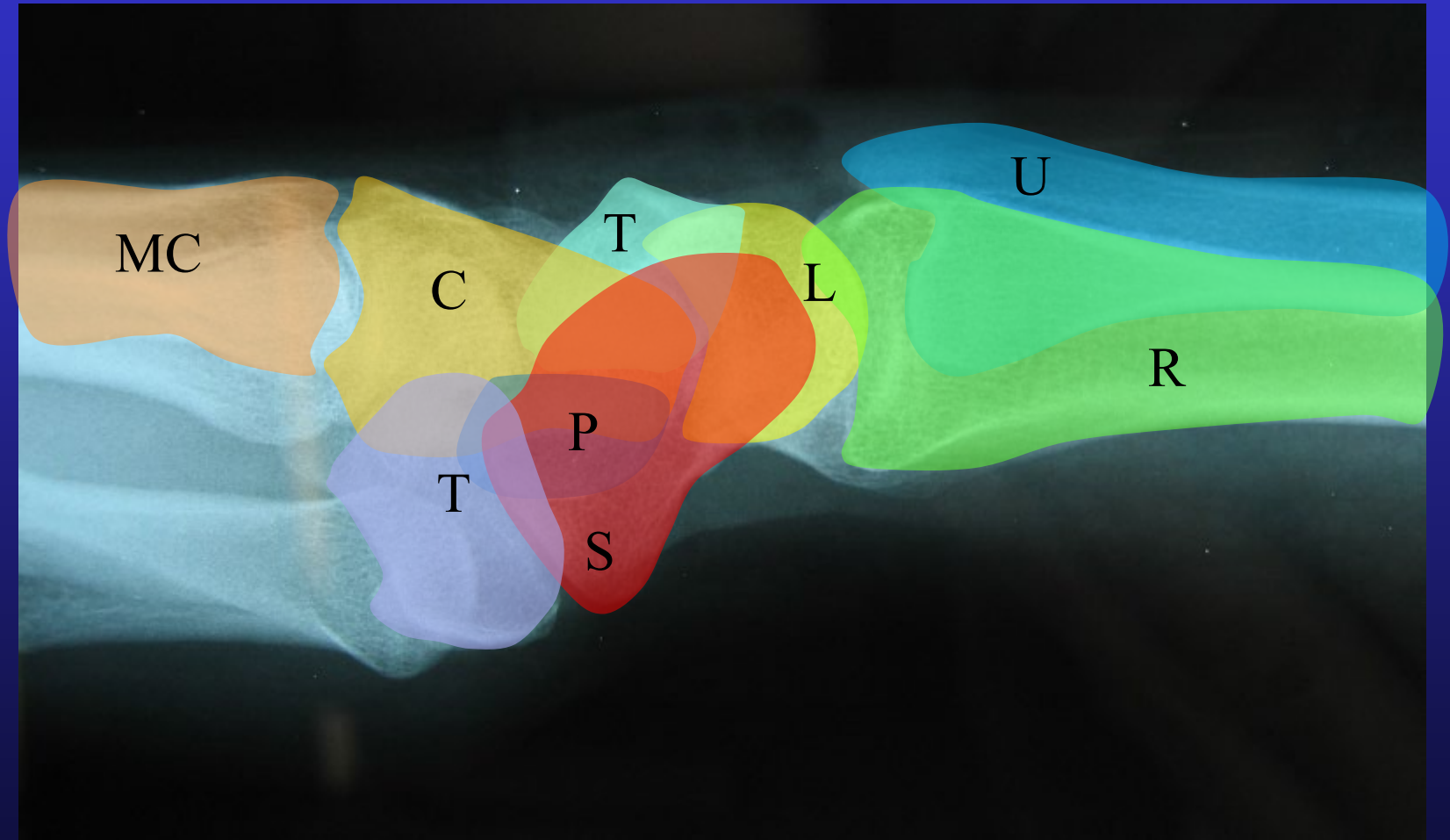


- Measure Scapholunate & Radio-lunate angles
- Neutral wrist deviation
- Middle metacarpal in line with radius
- ?? Lunate

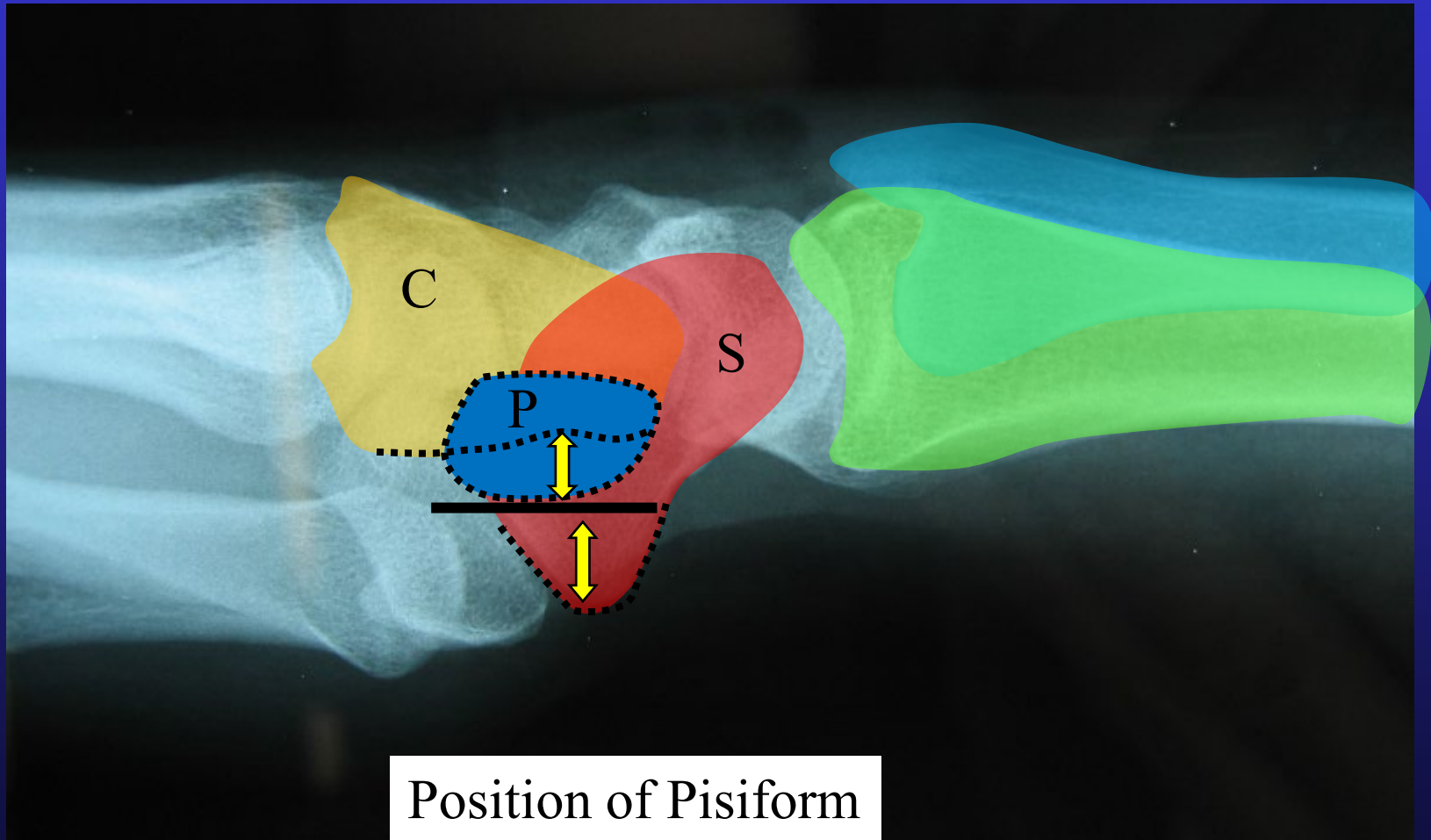
Lateral Views



Carpal bones

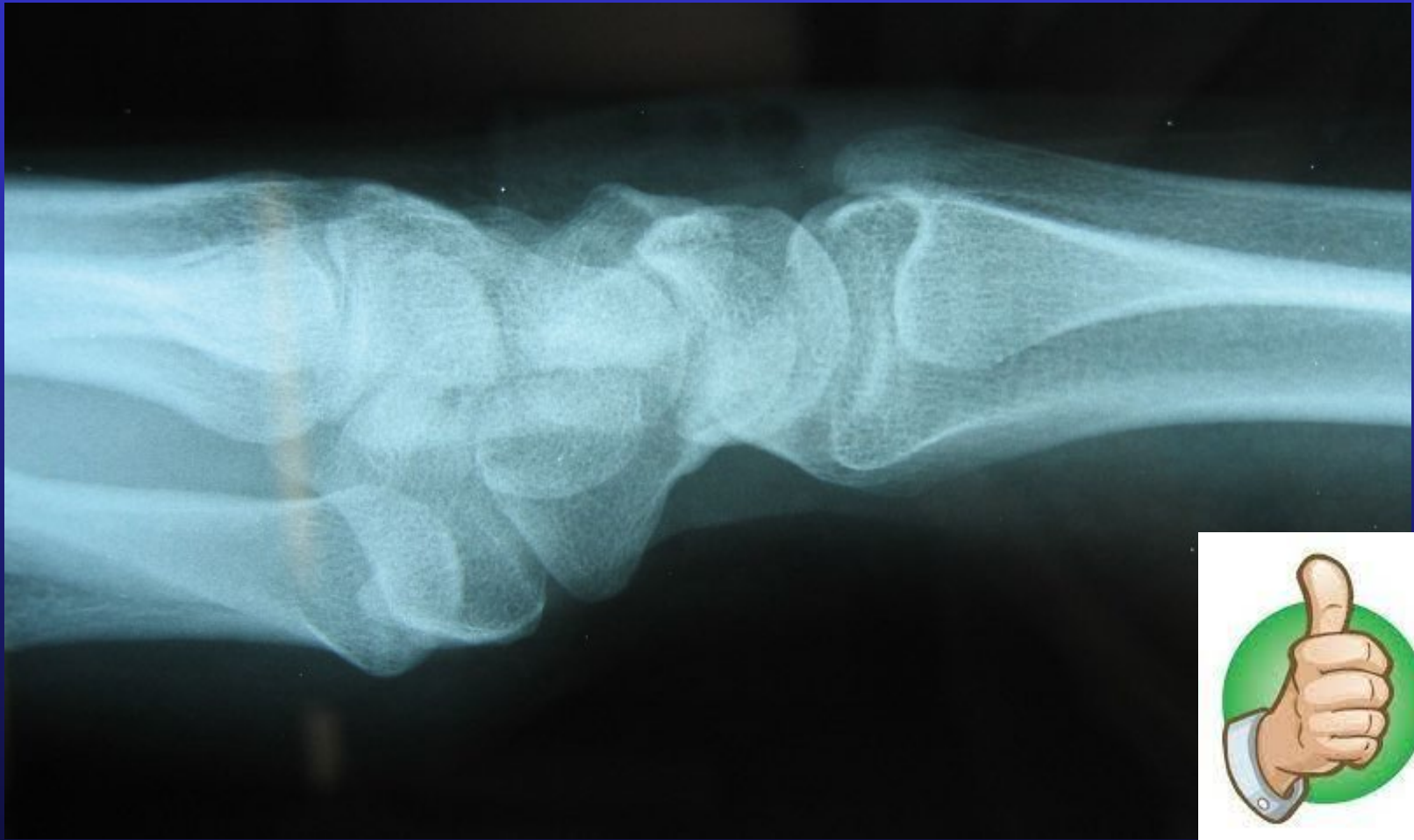

“True Lateral”

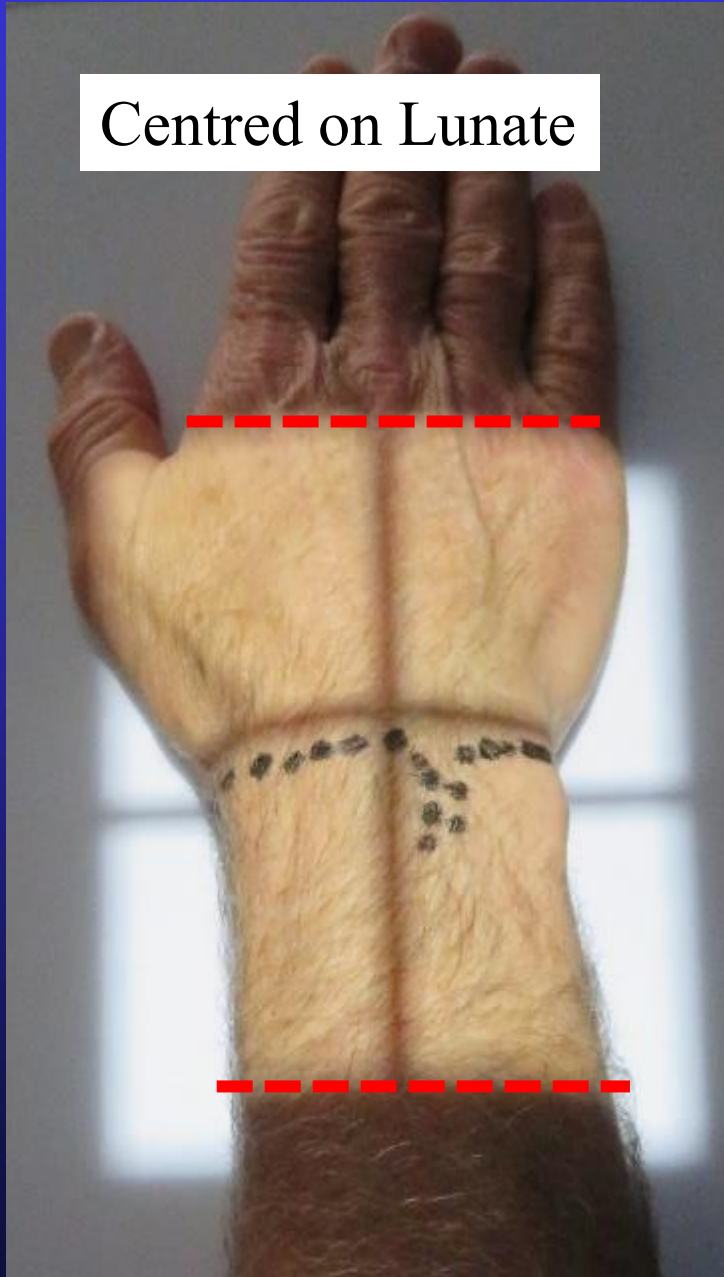


Position of Pisiform

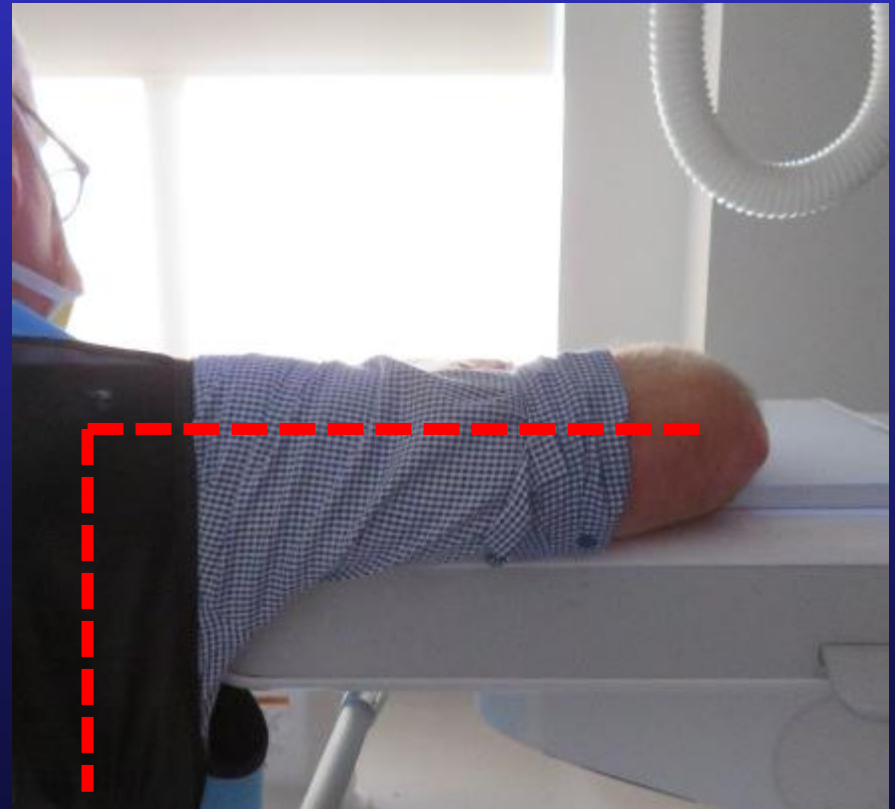
Lateral Views

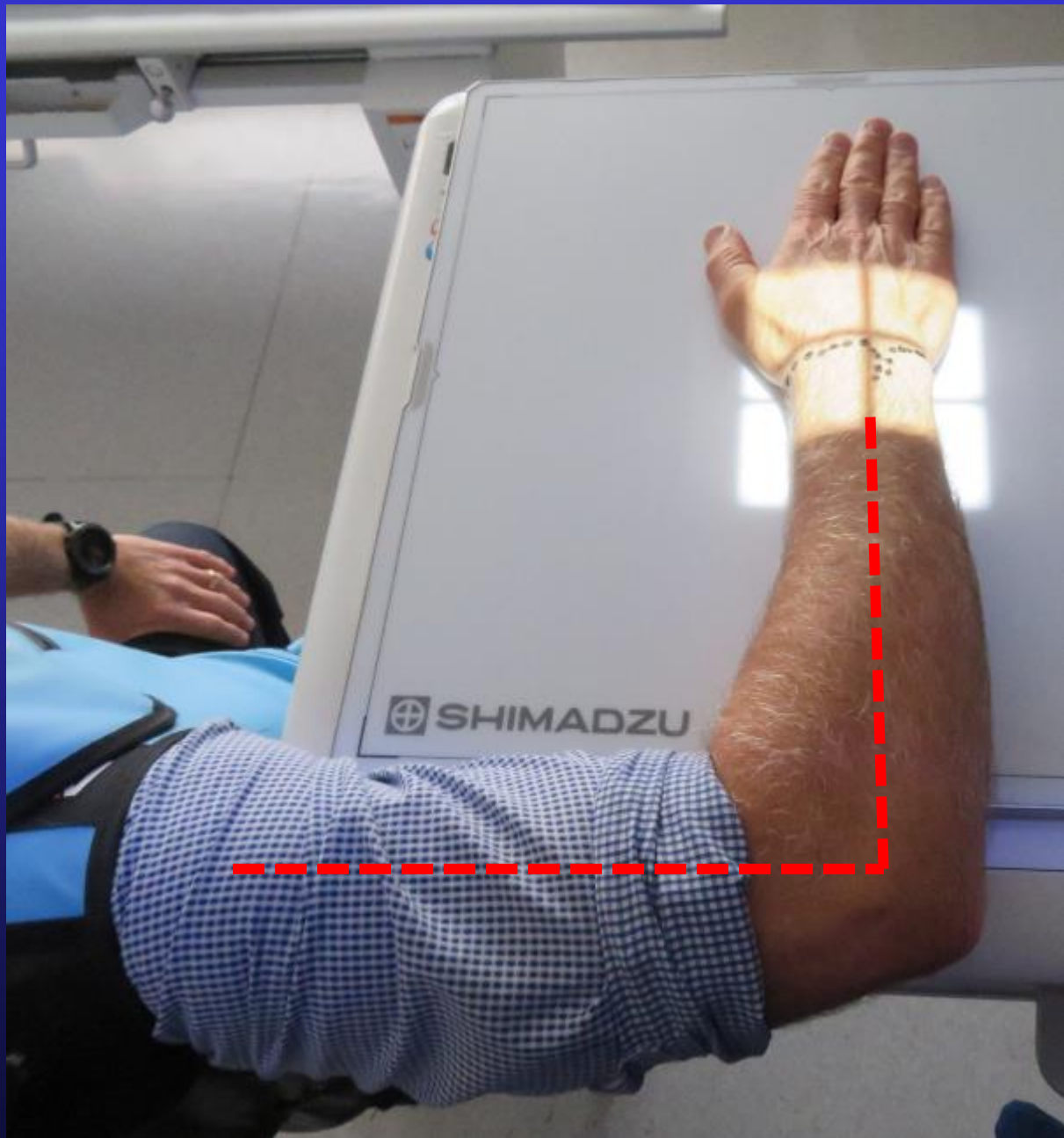


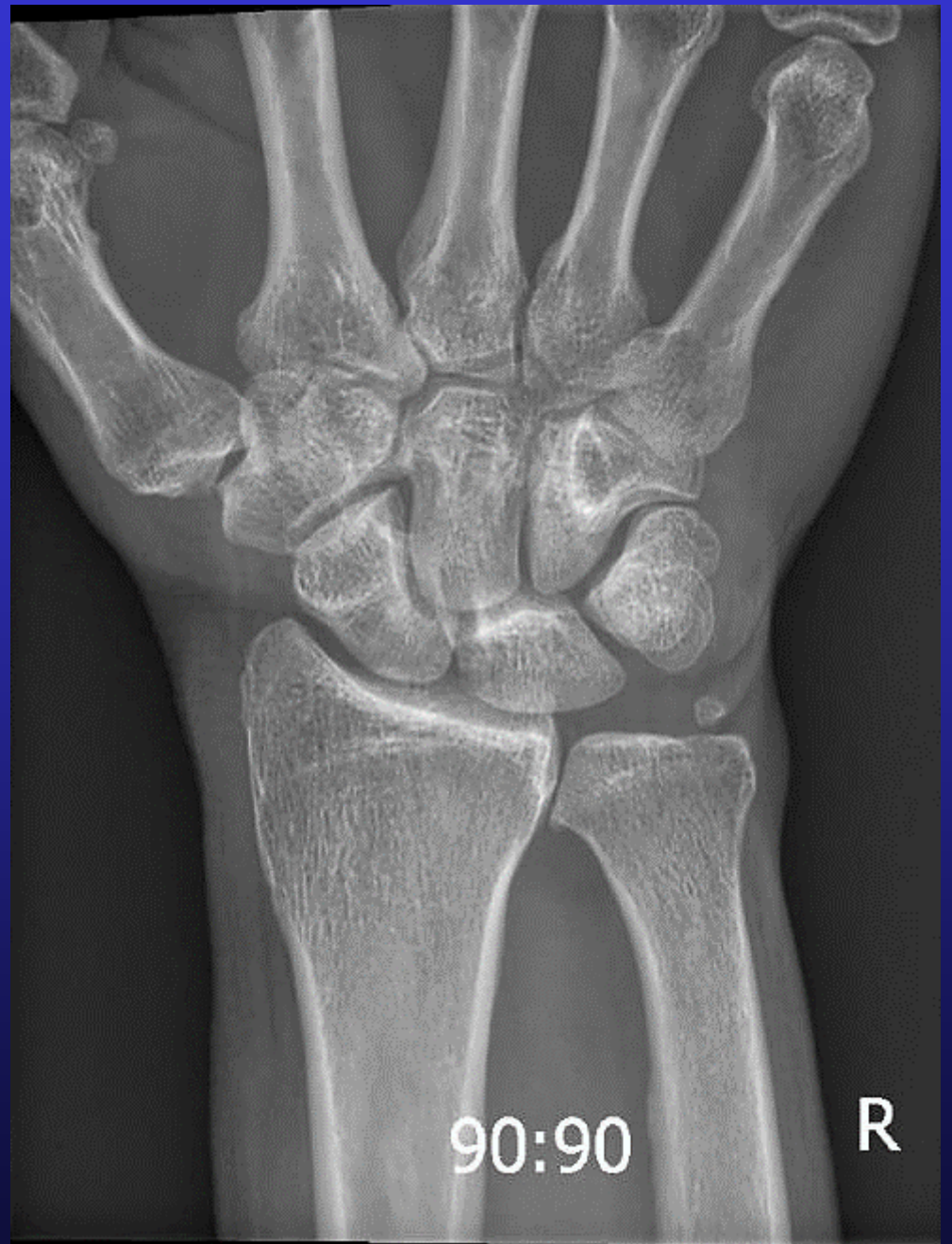Centred on Lunate

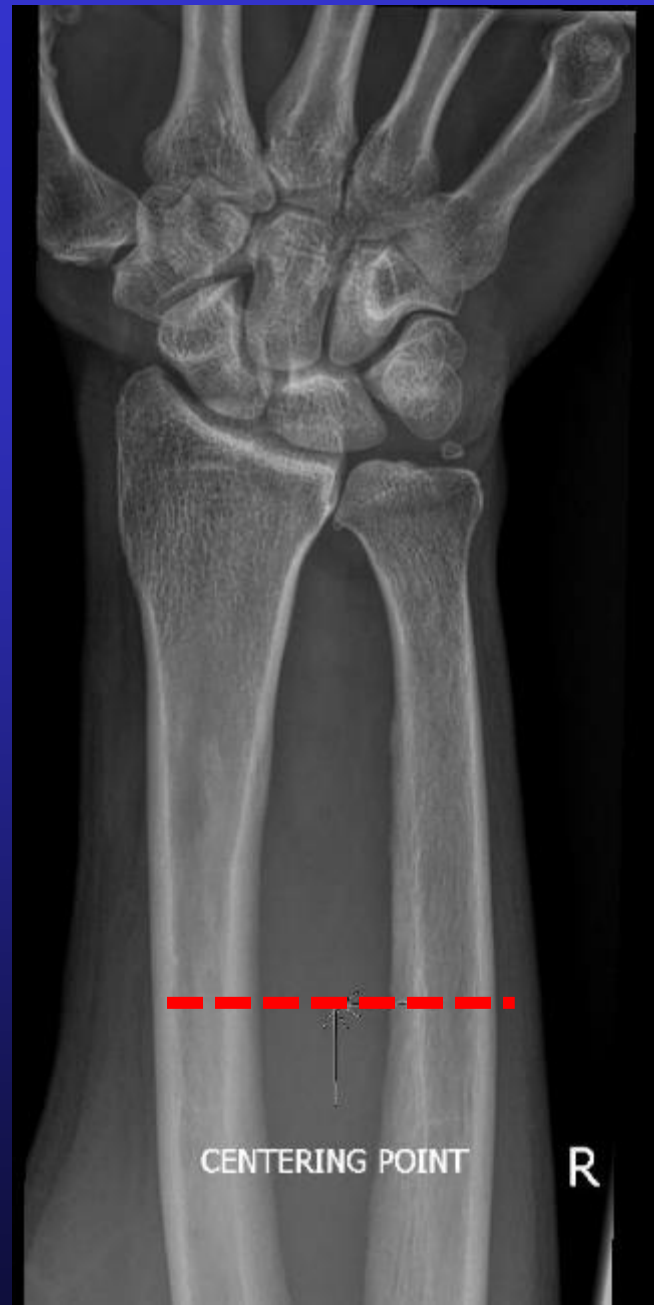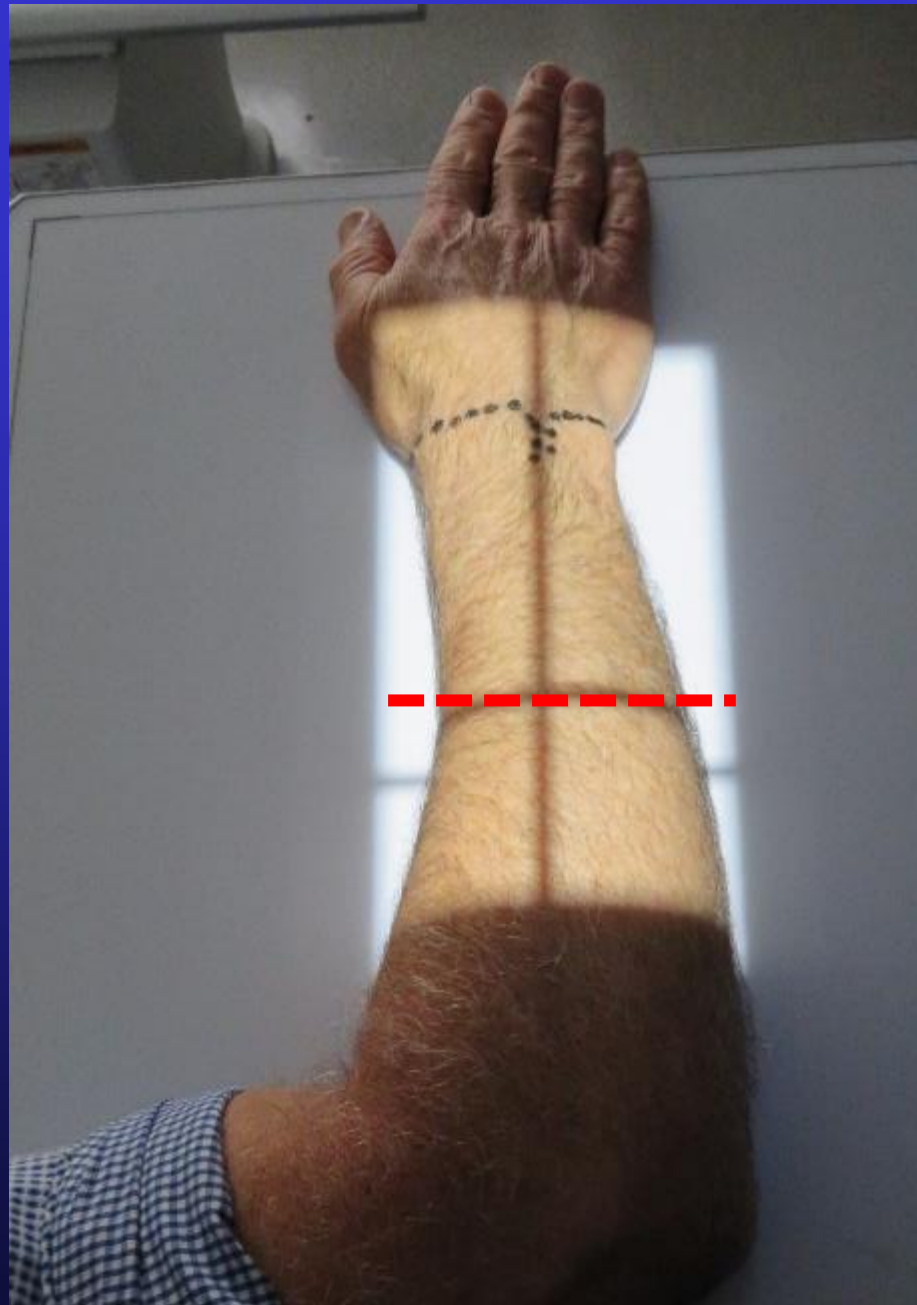


PA Neutral 90:90





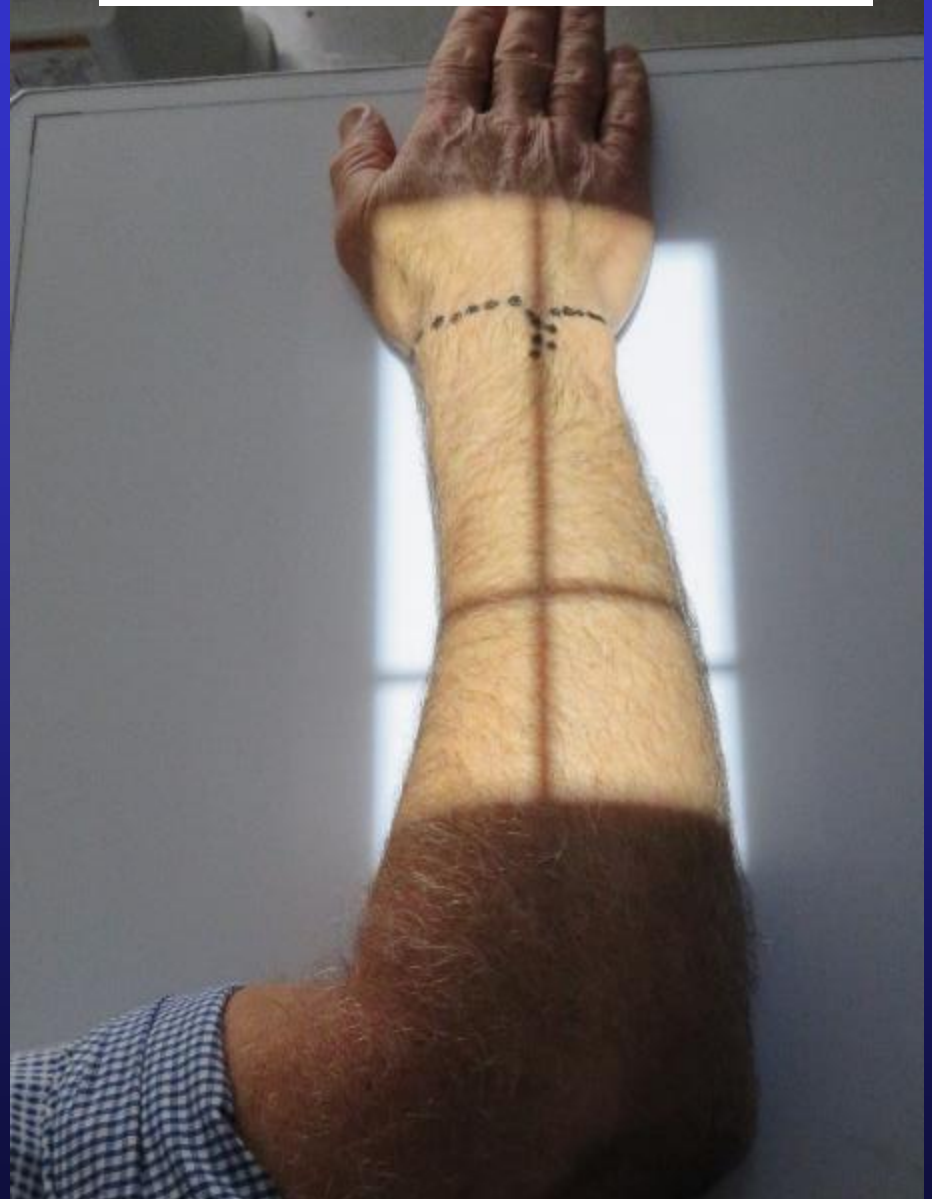



Centred on Lunate

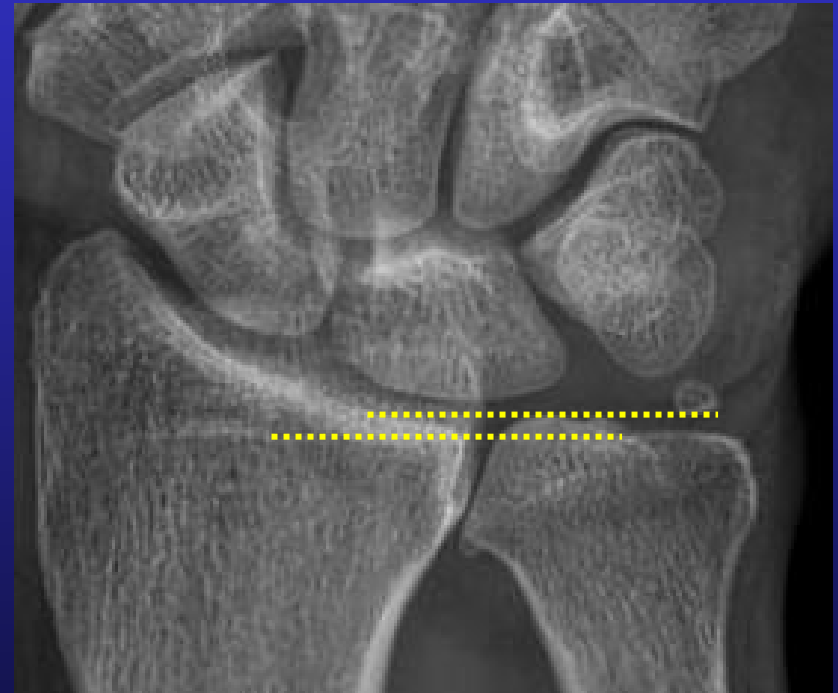
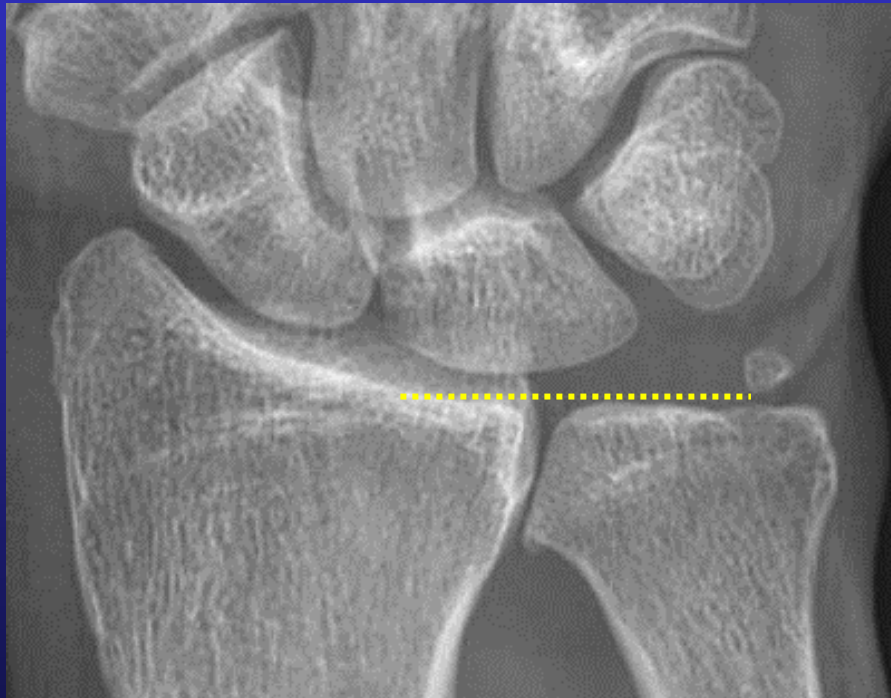
Centred on Mid forearm

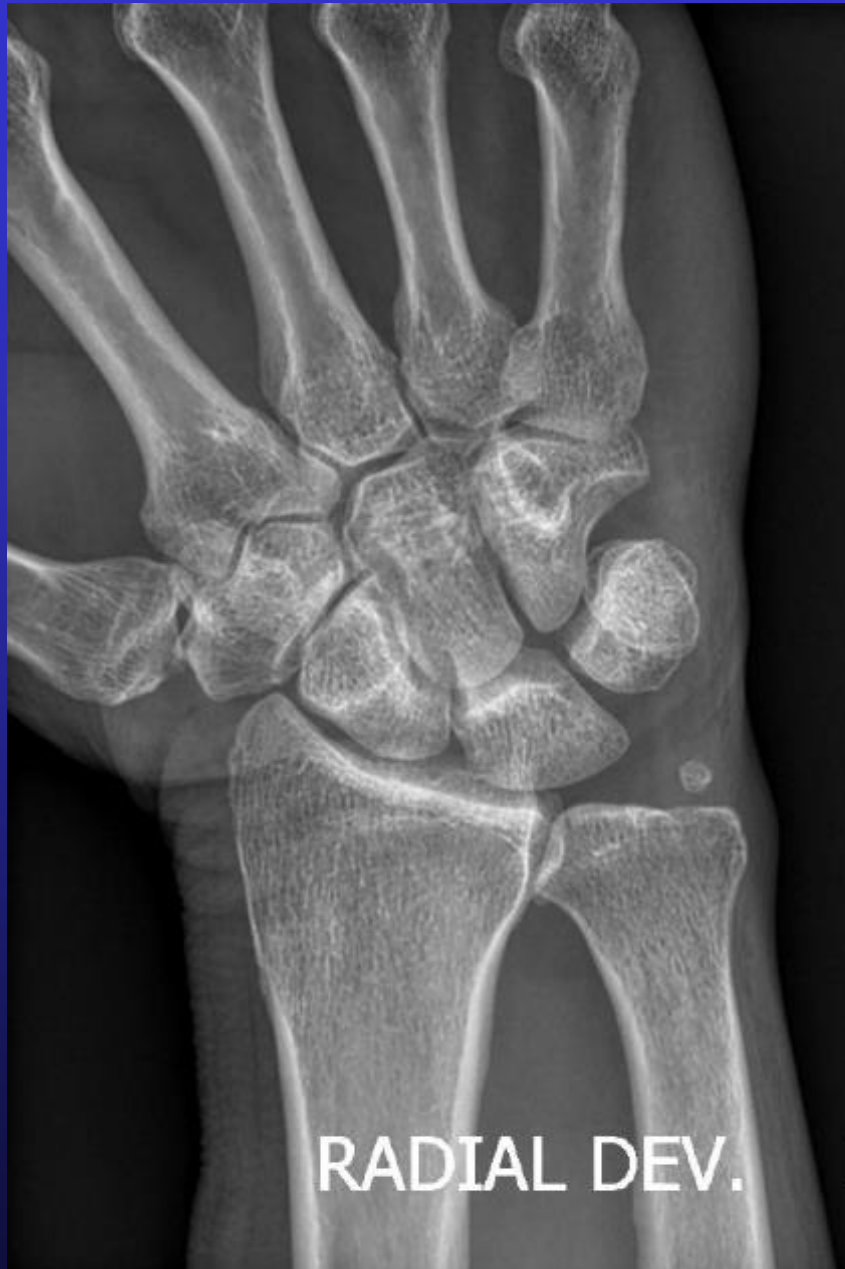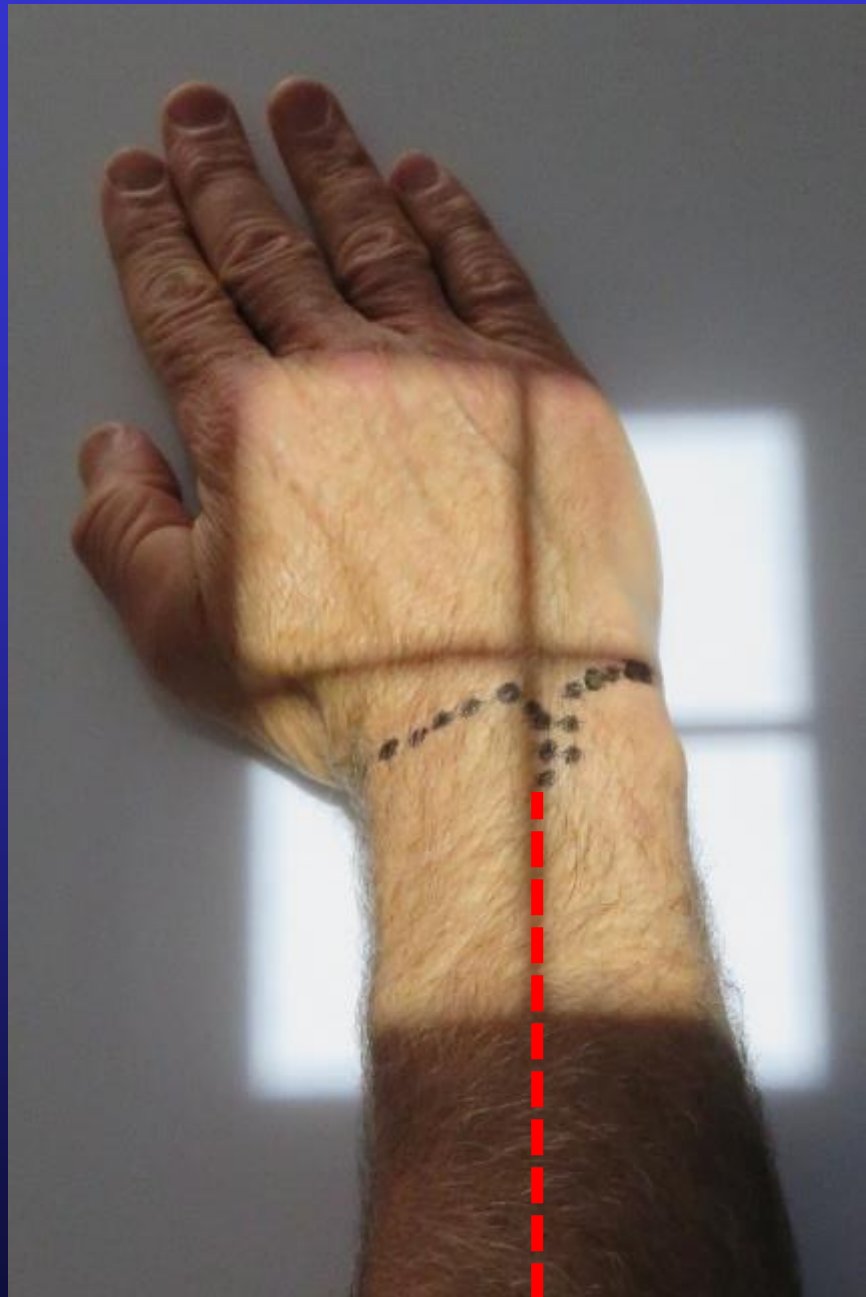


Centred on Lunate

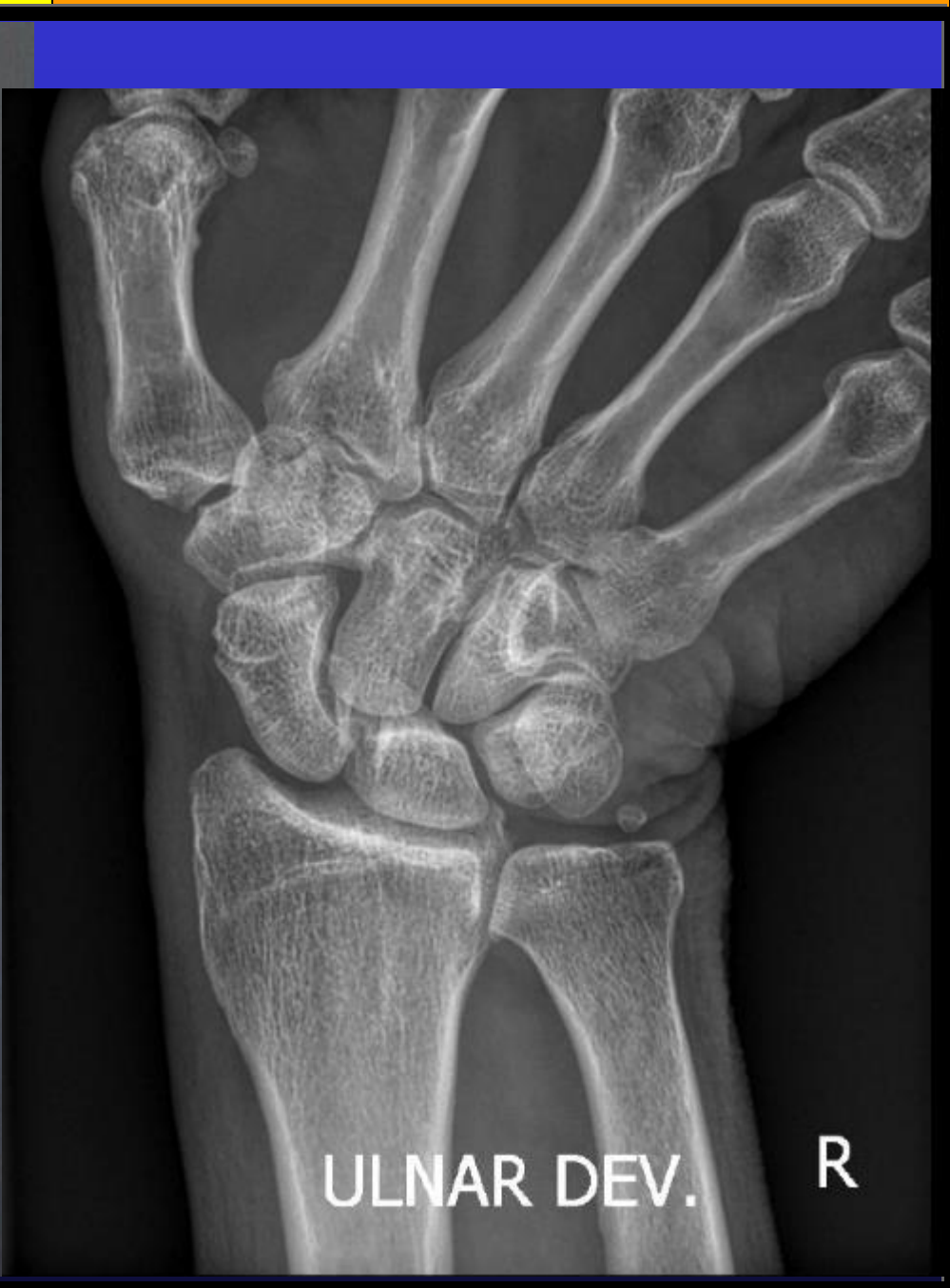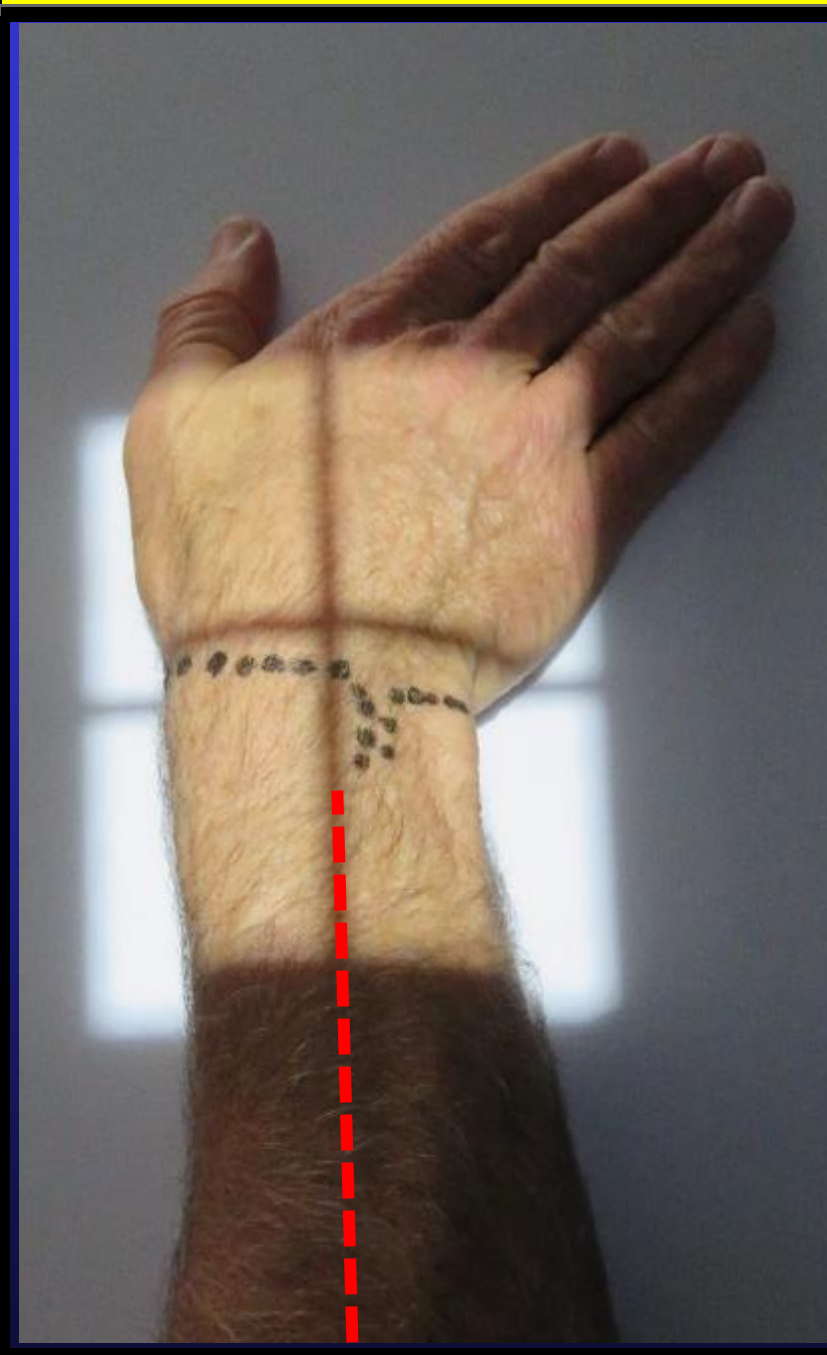
Centred on Mid forearm

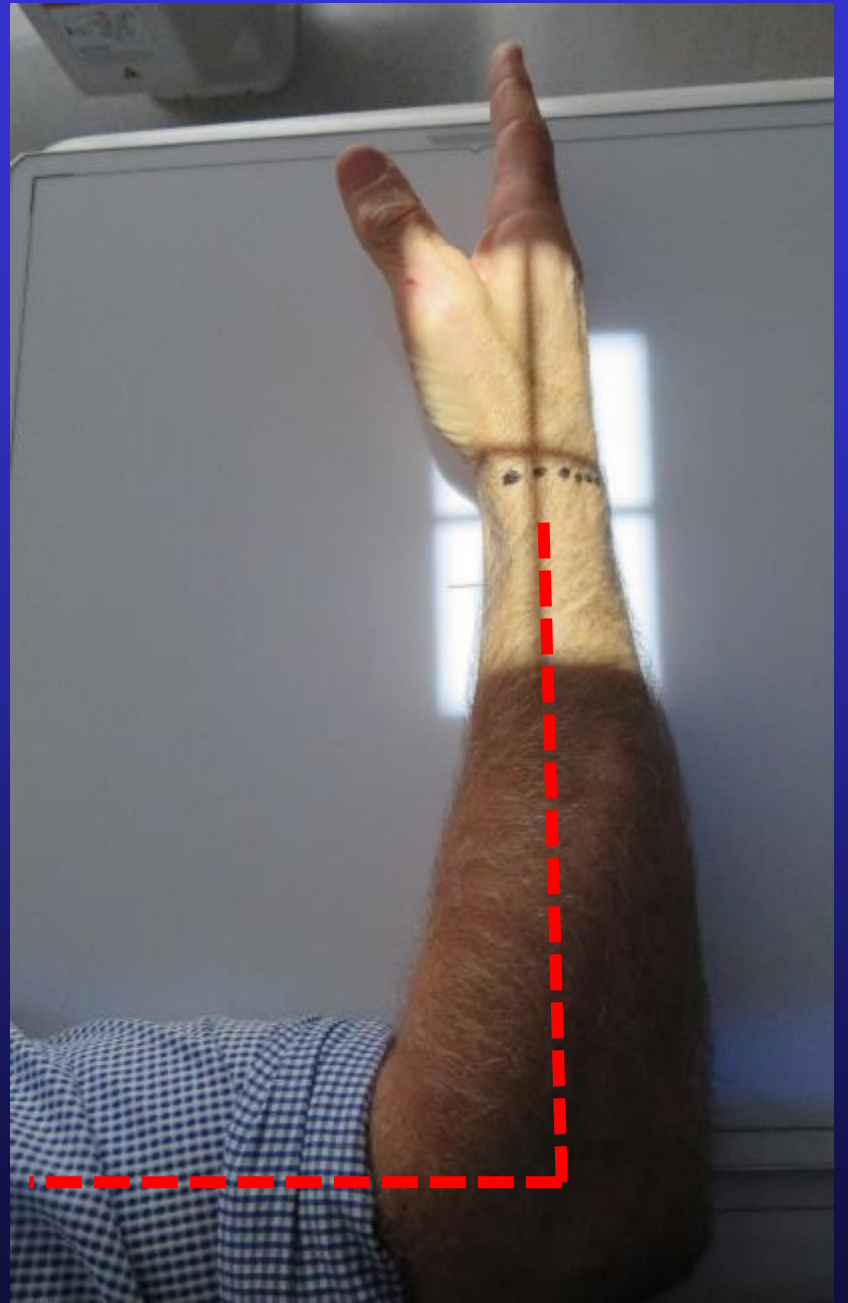
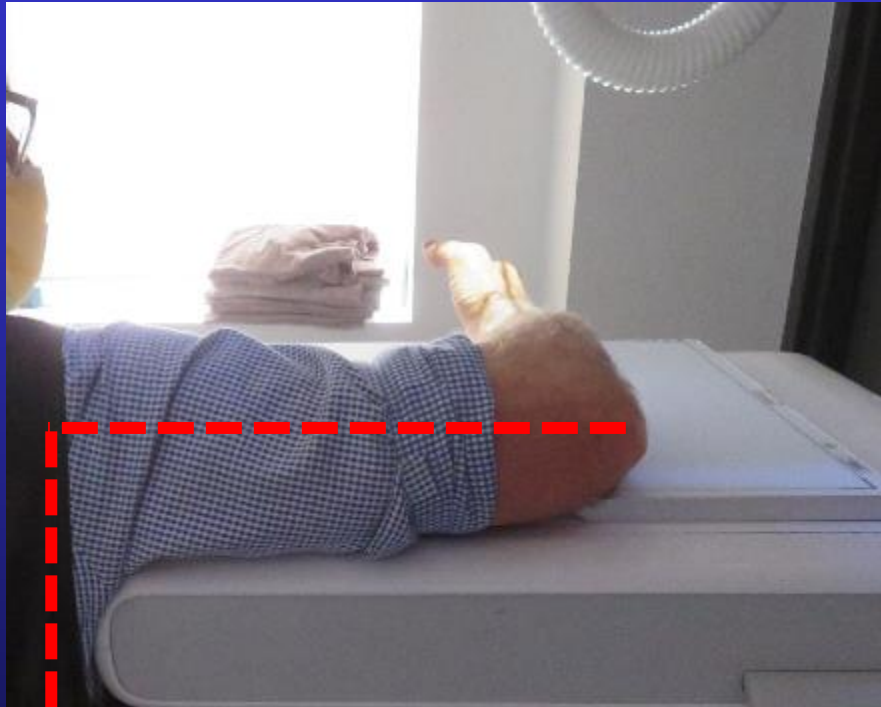


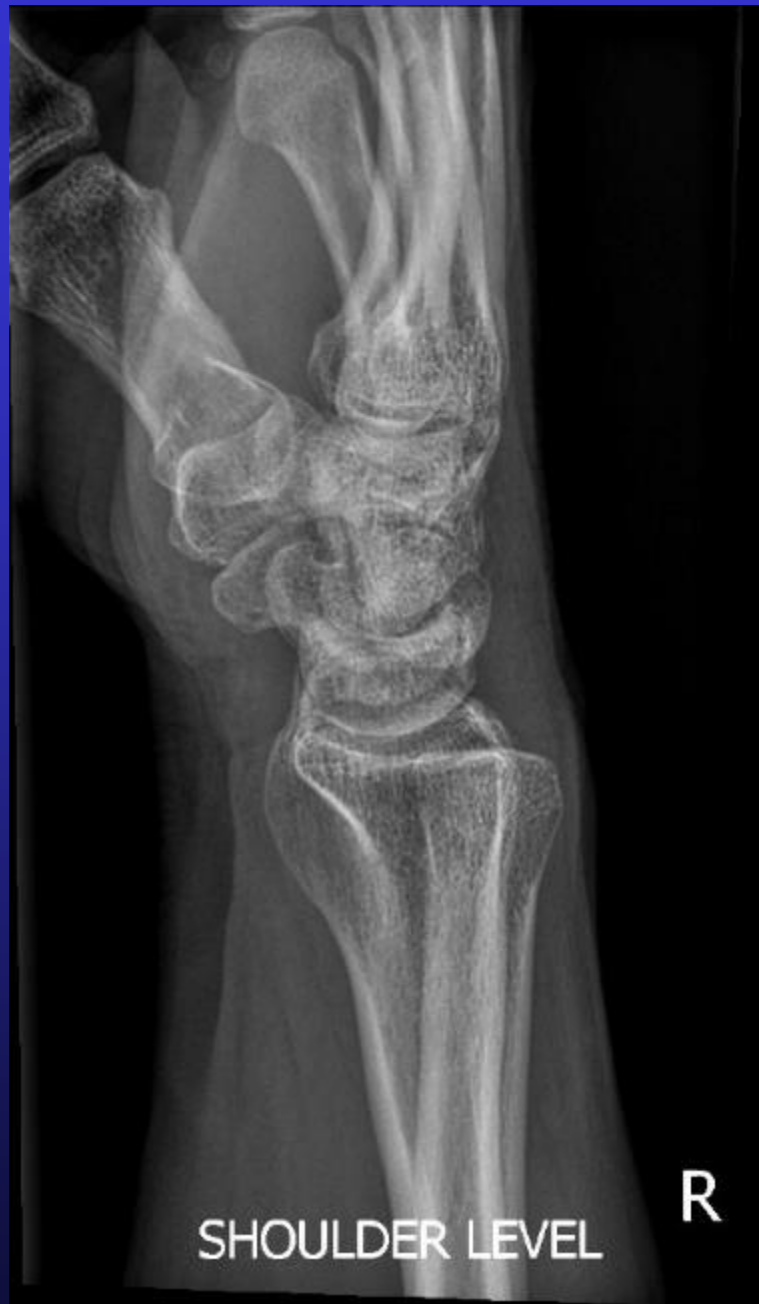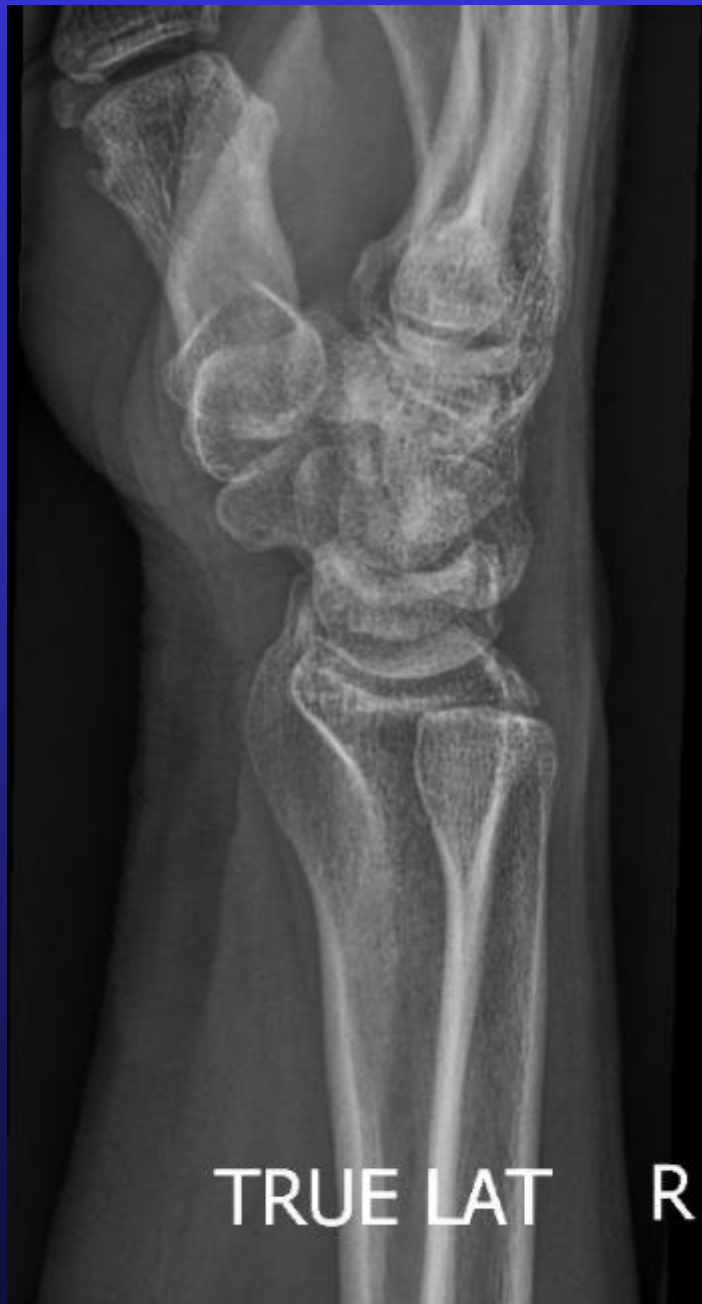Apparent change in Ulnar Variance

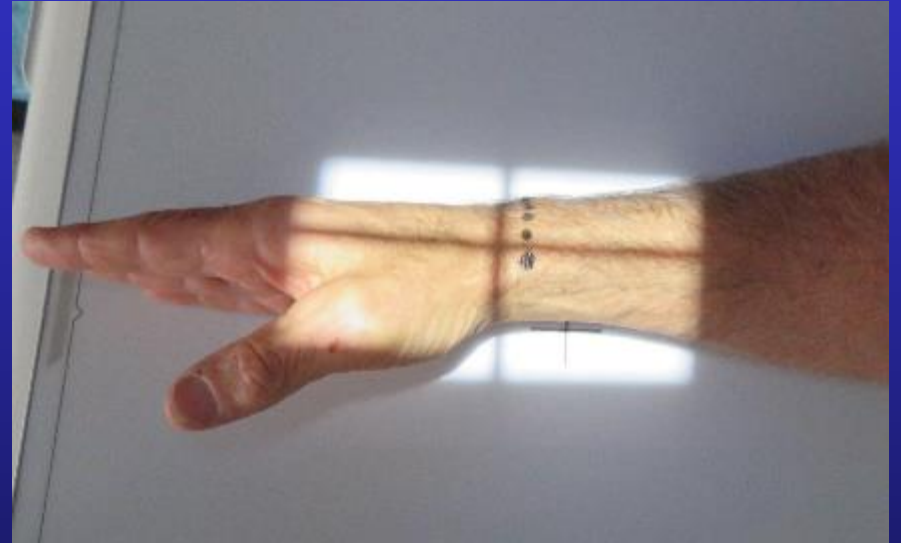
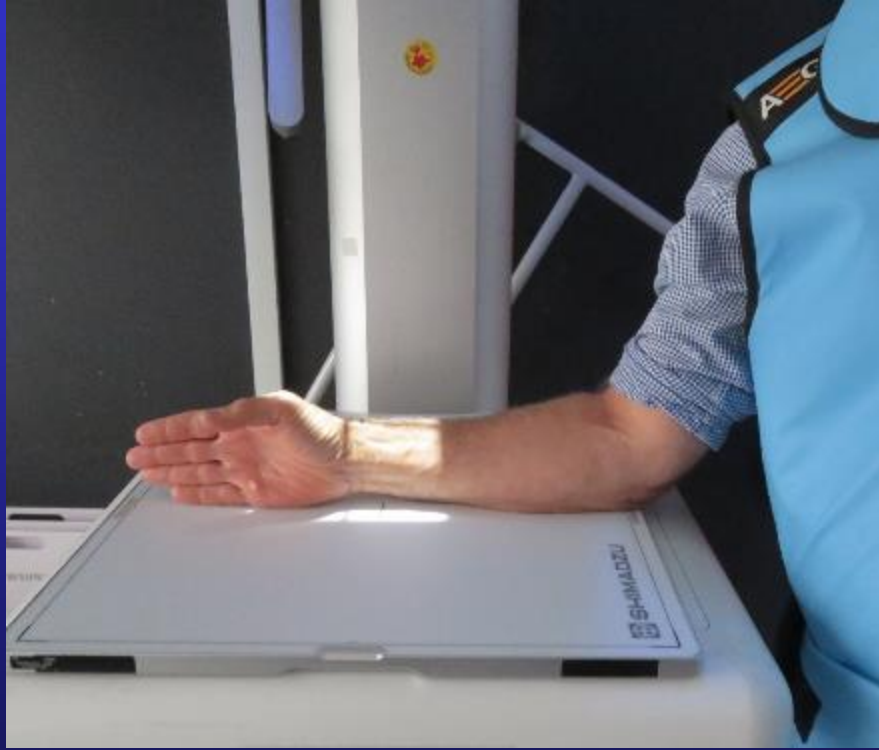

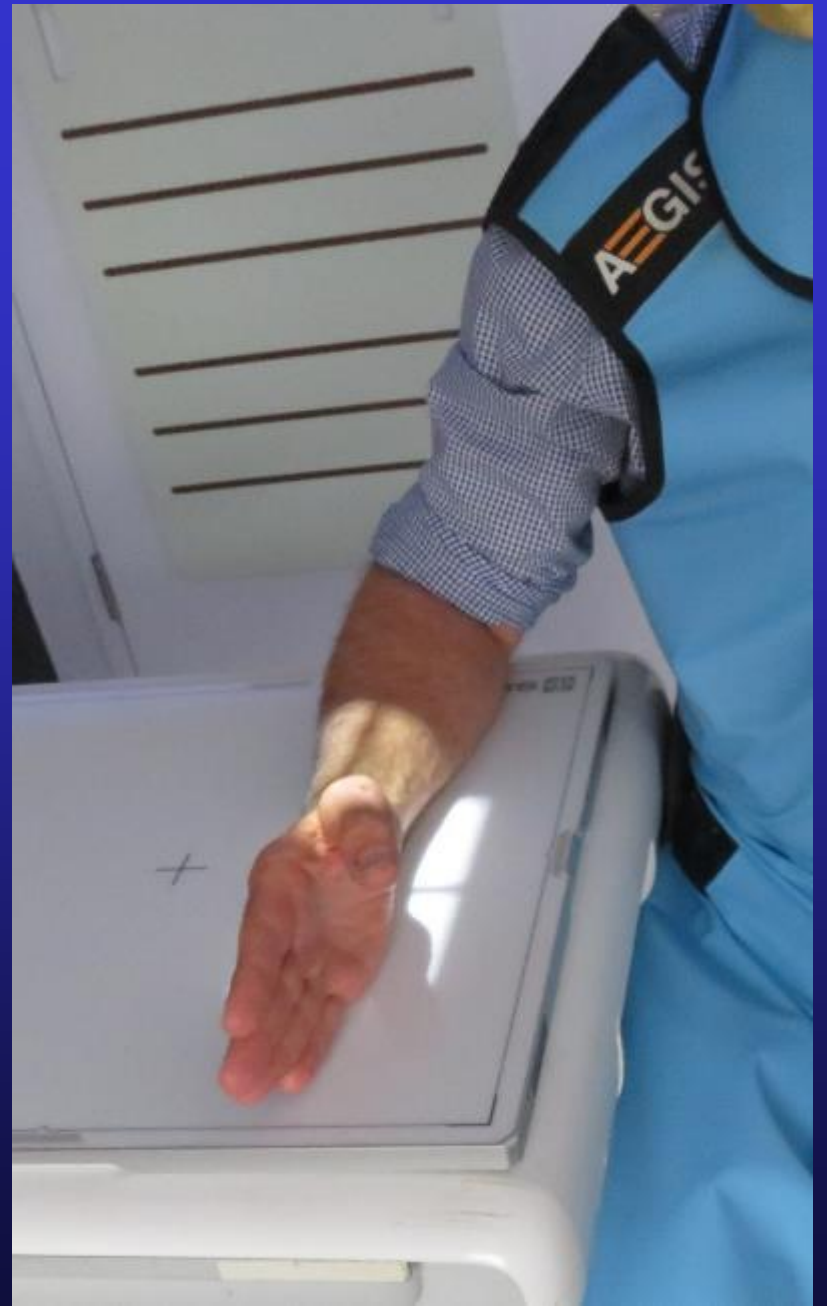RADIAL DEV. R

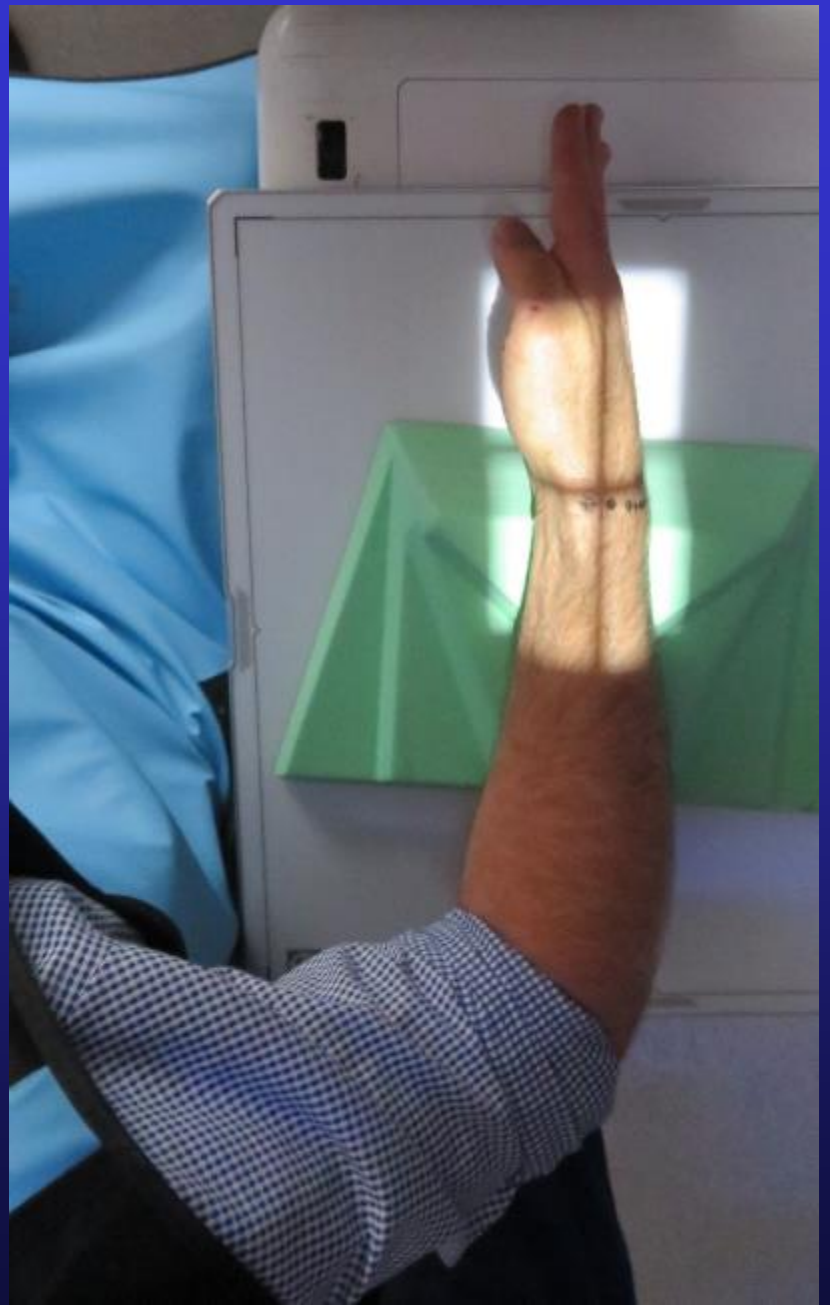


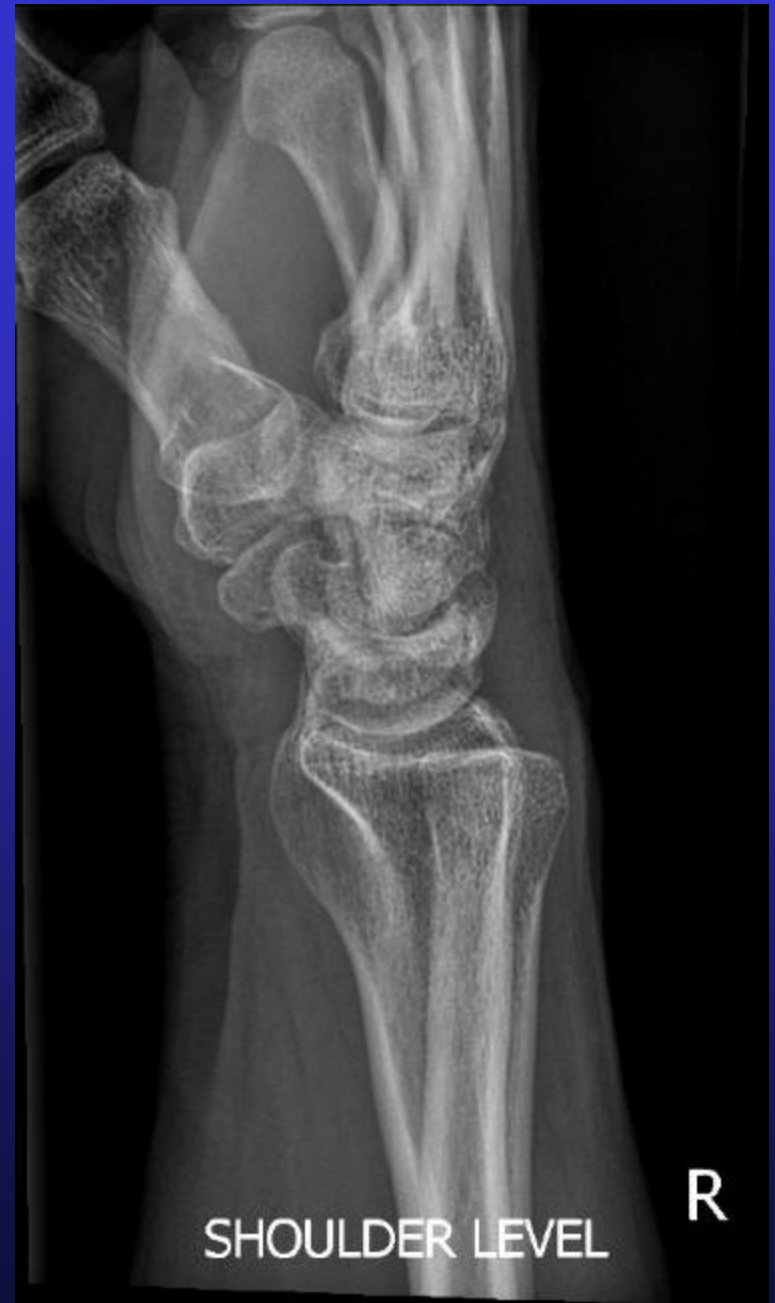


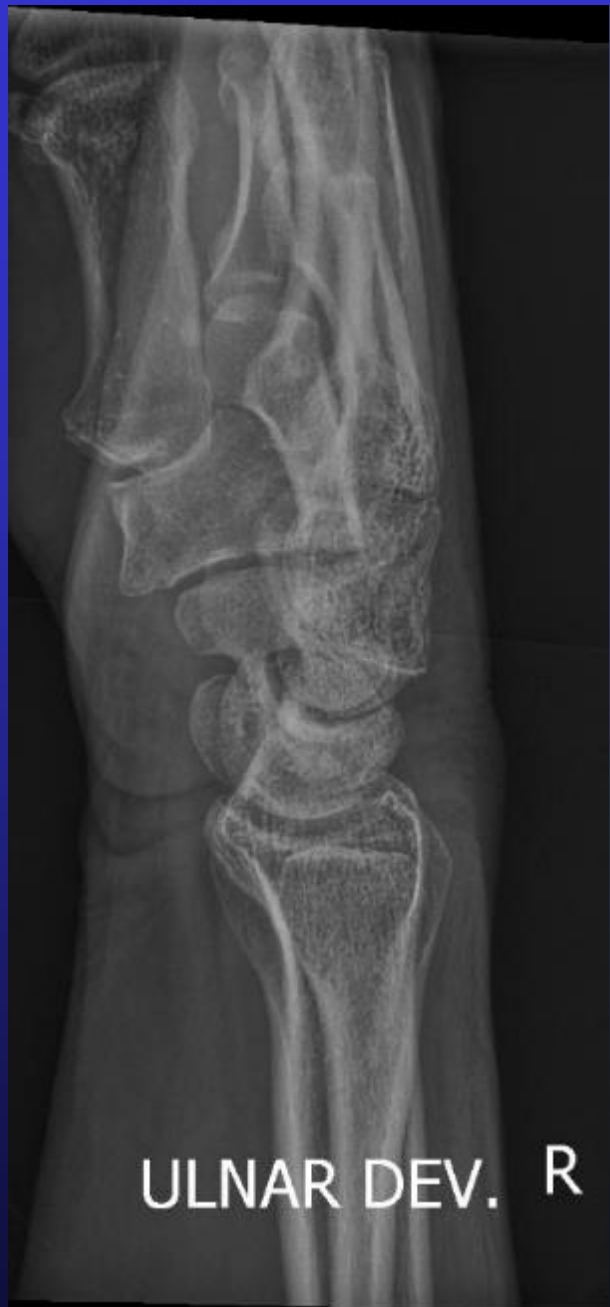
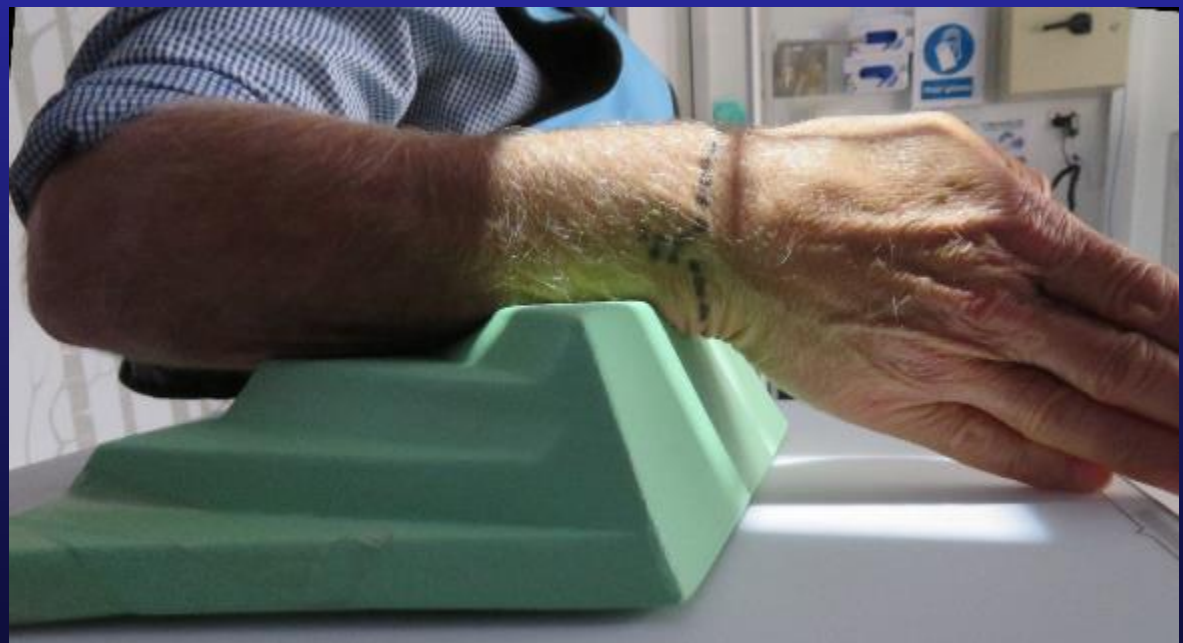
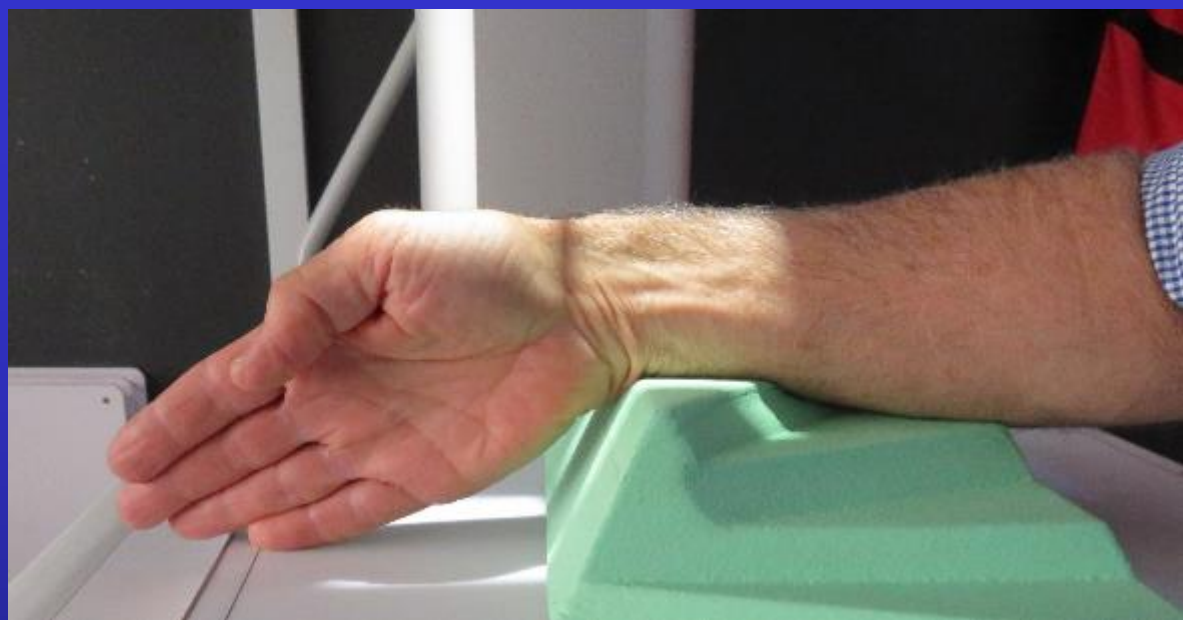




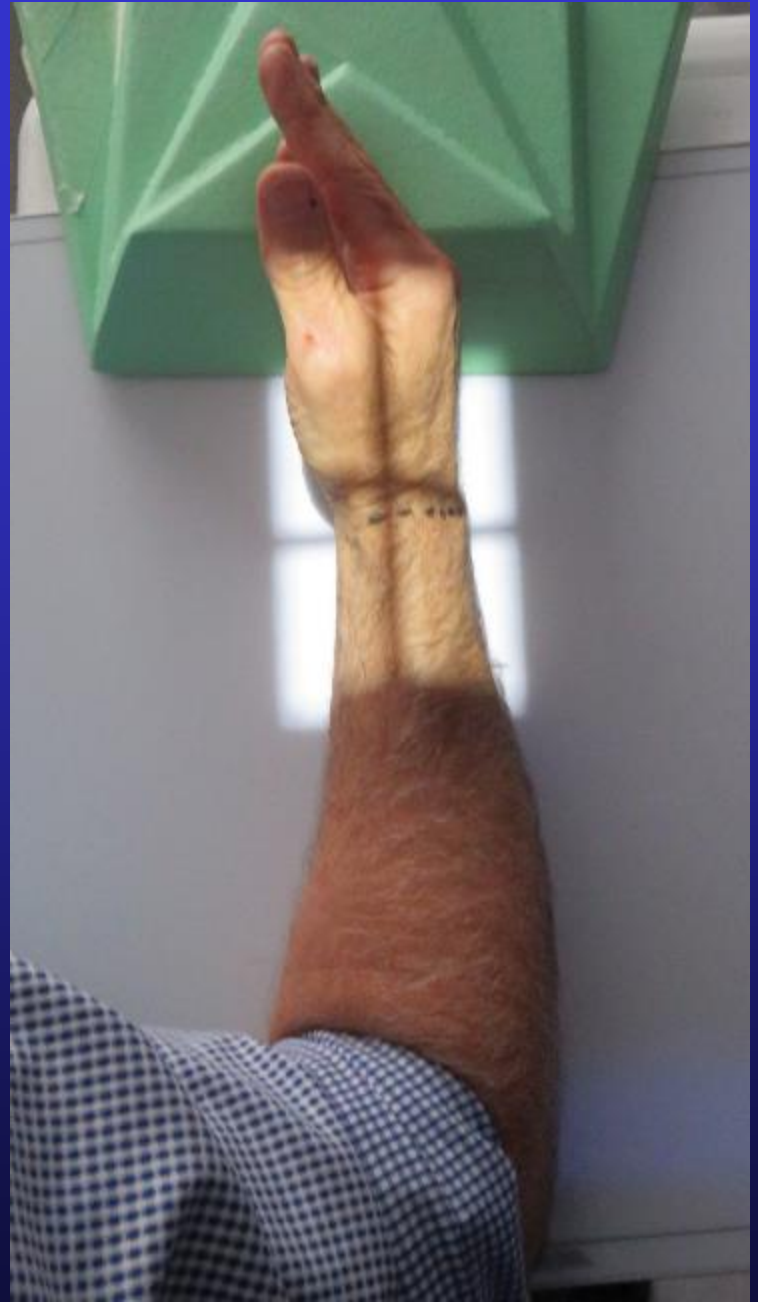
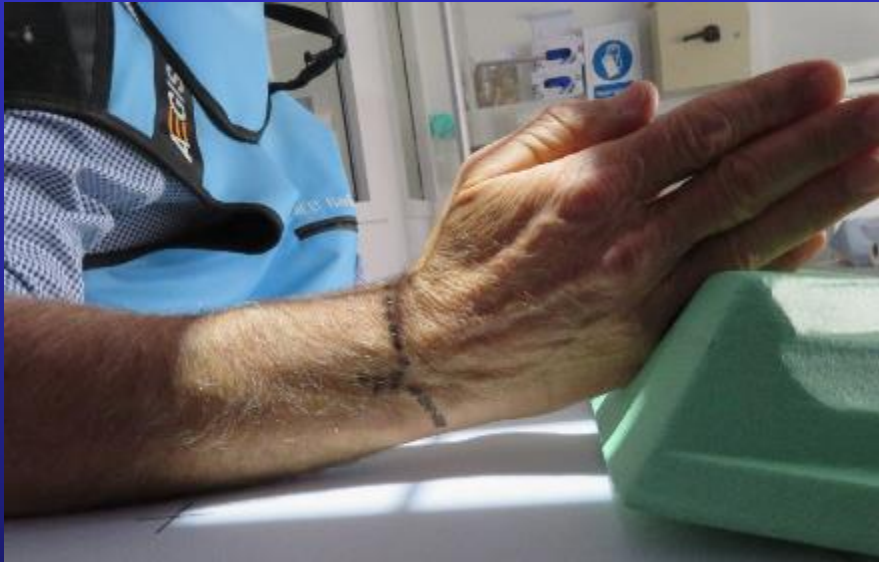


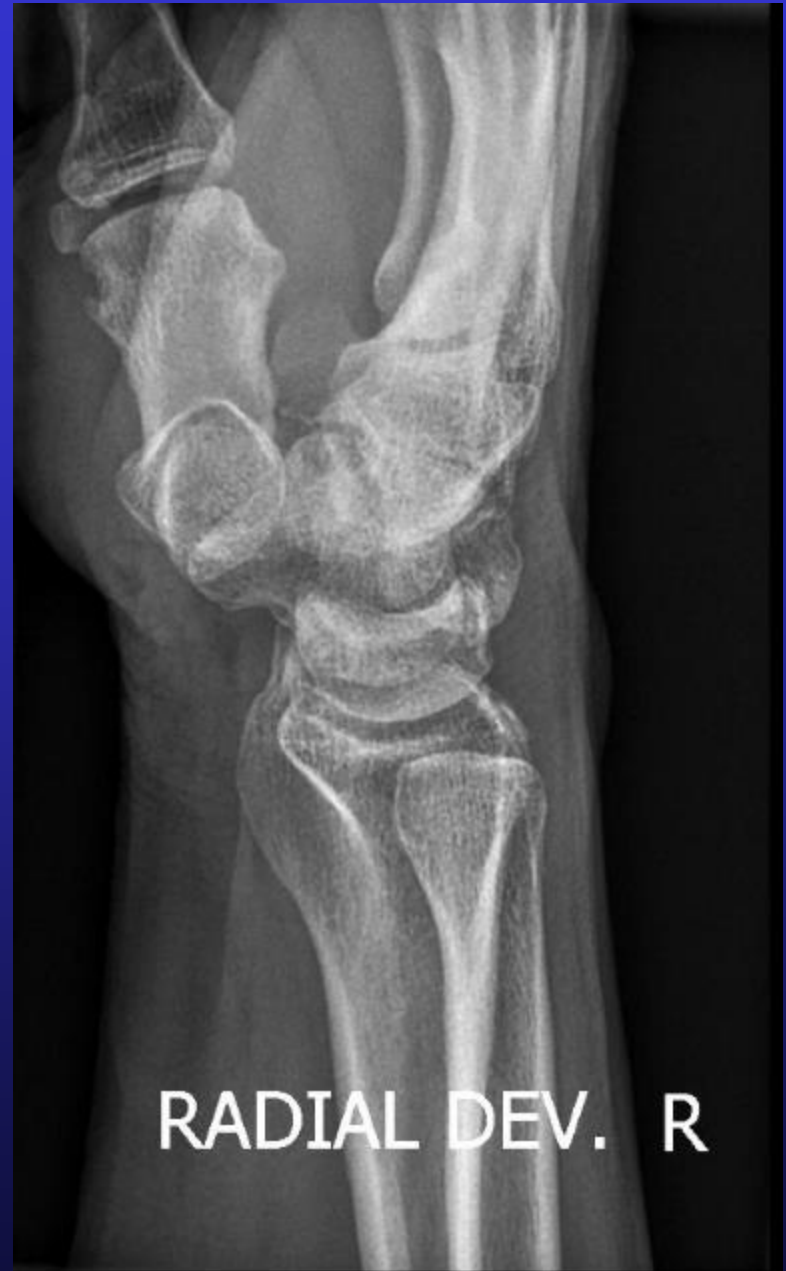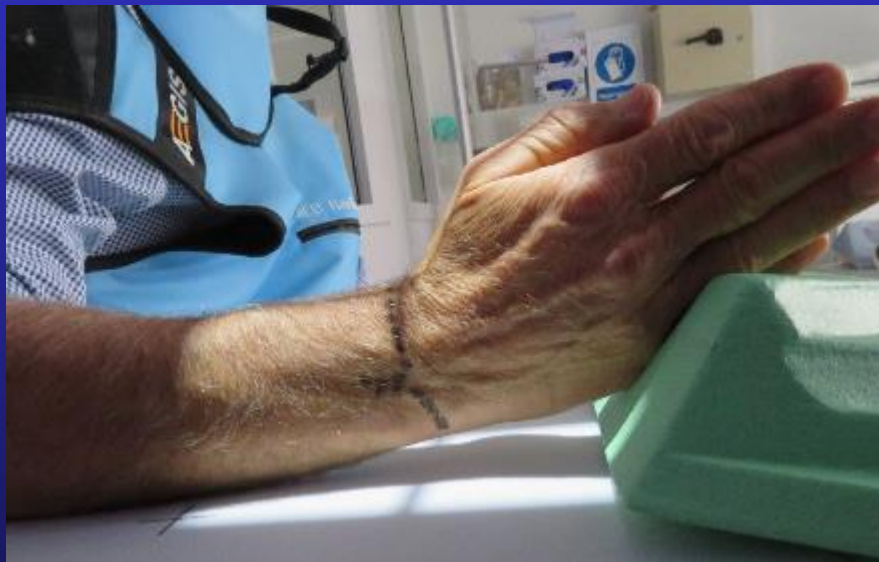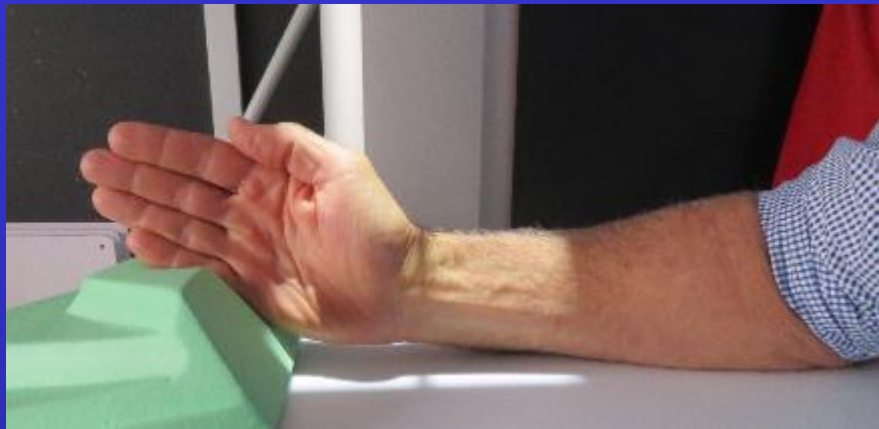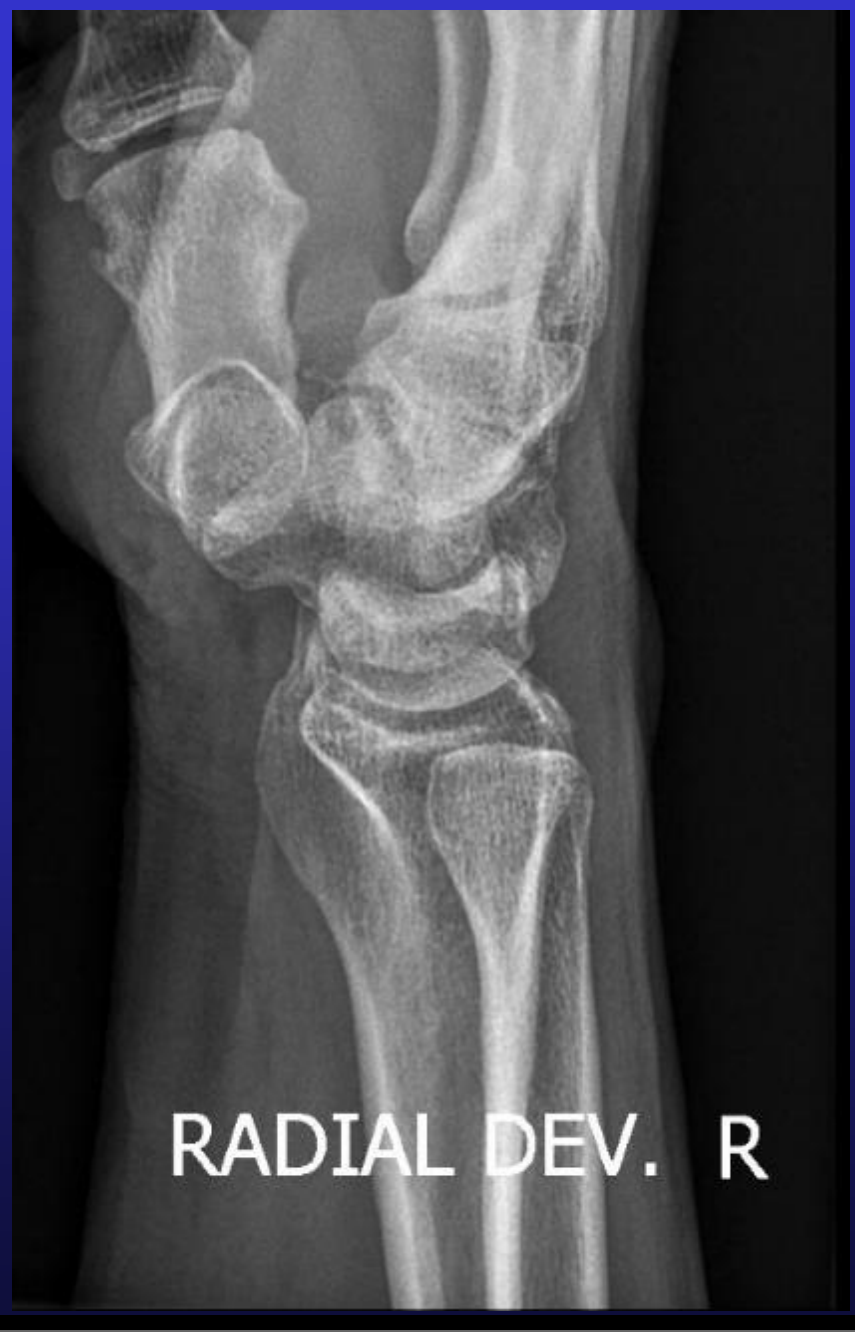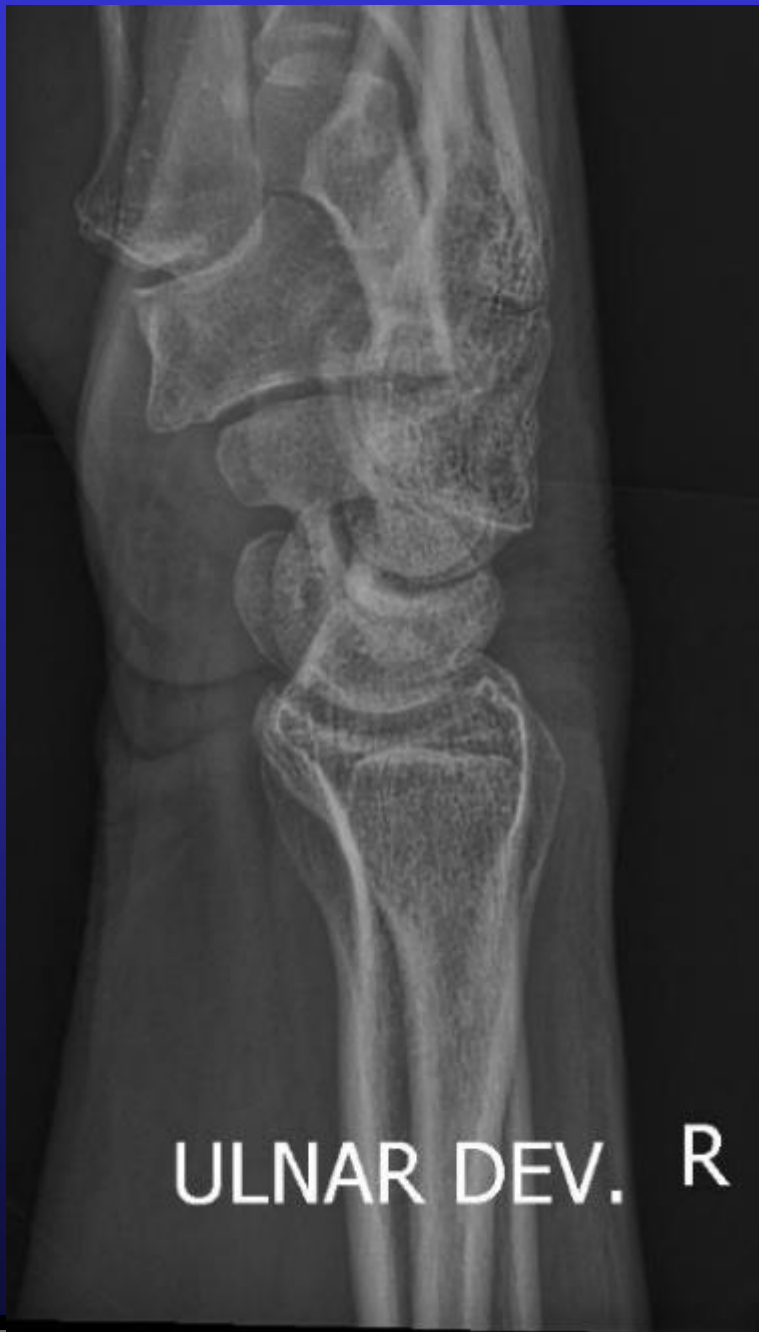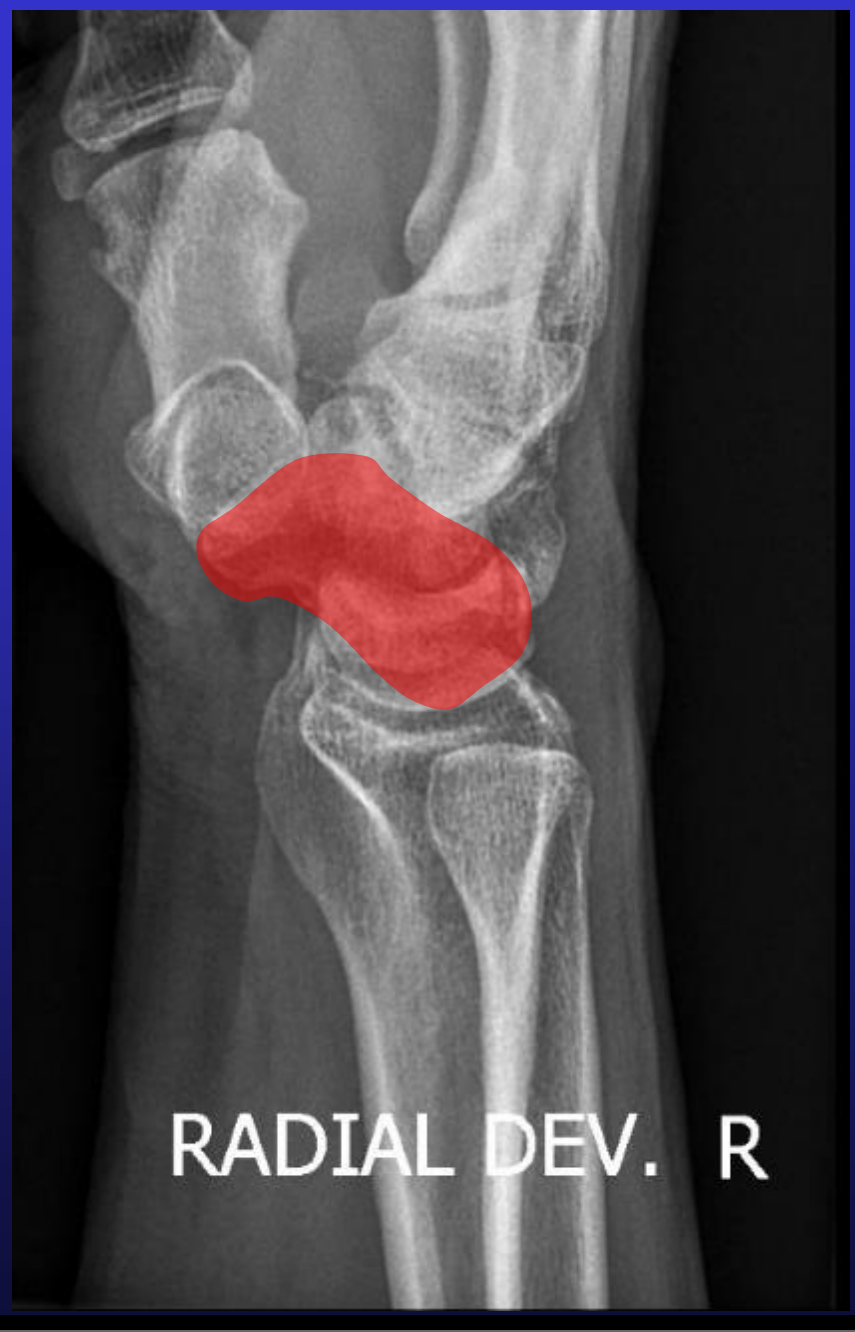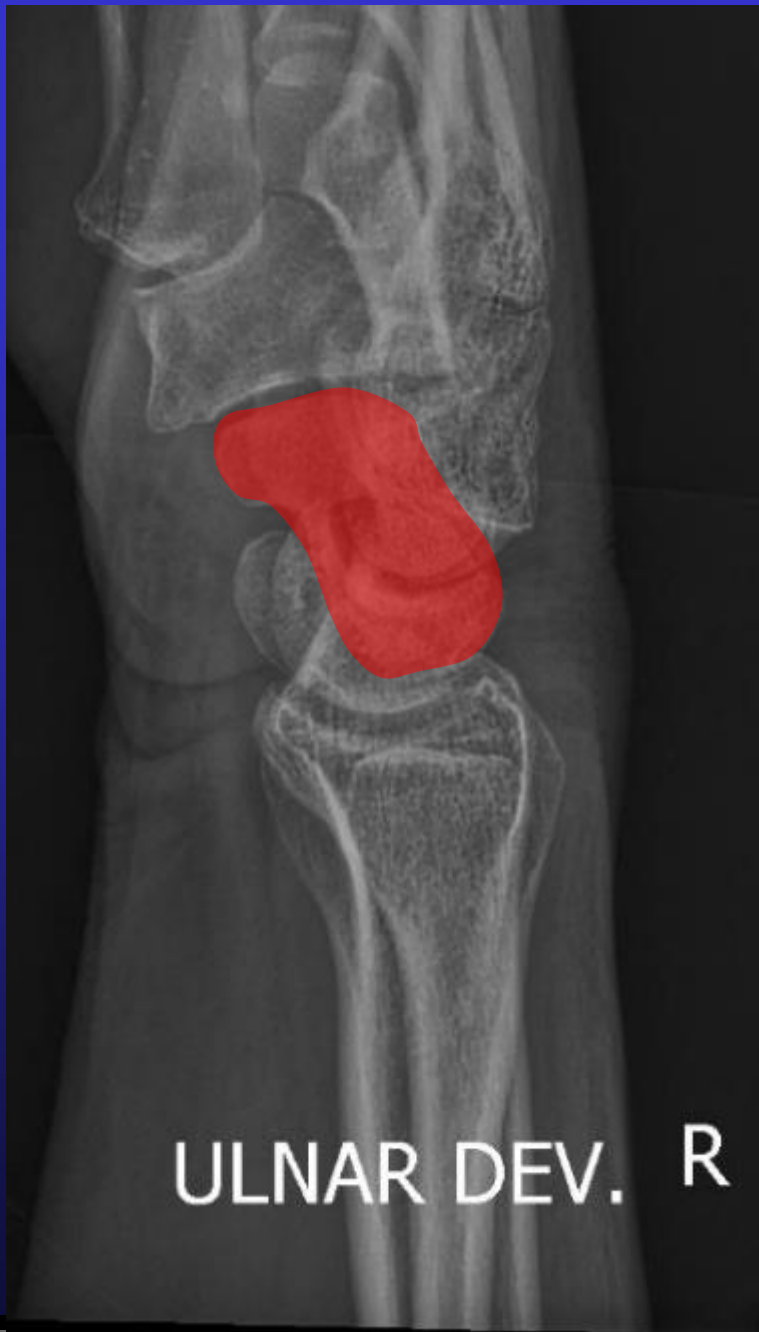ULNAR DEV. R

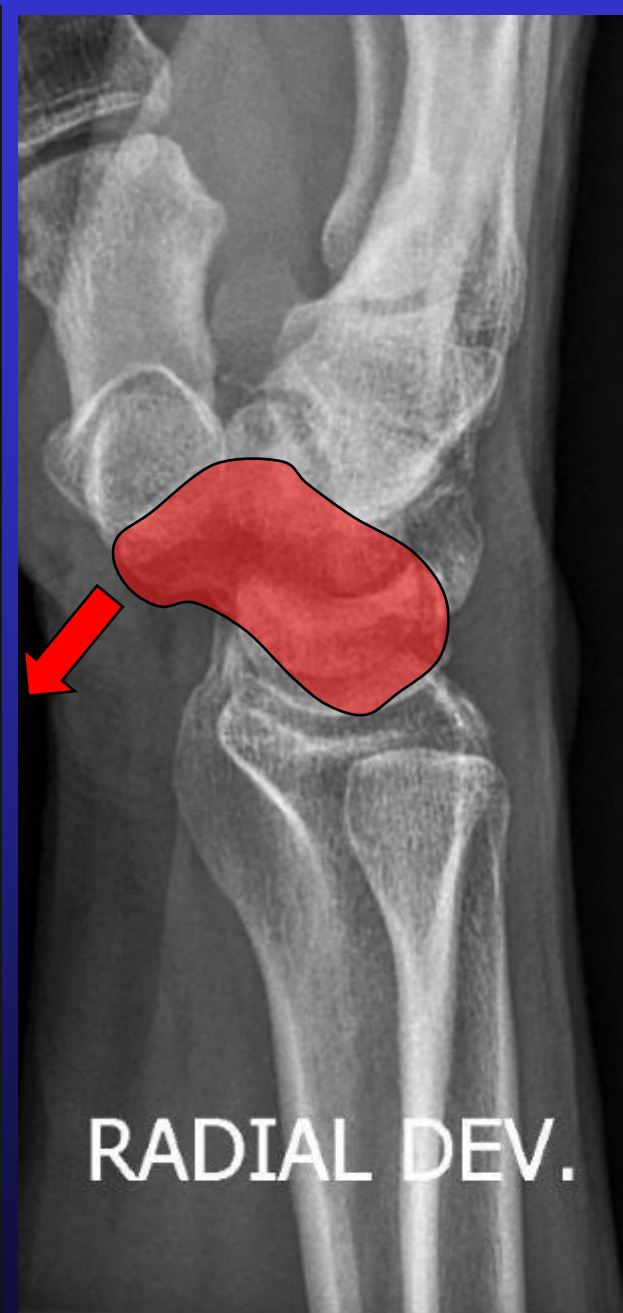
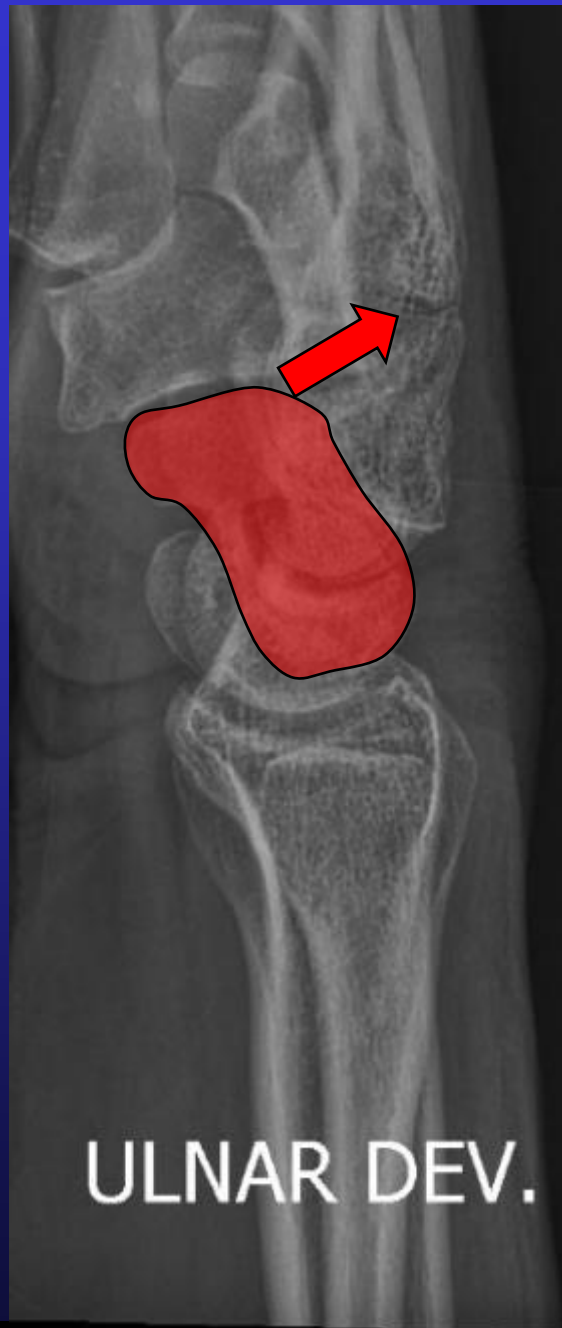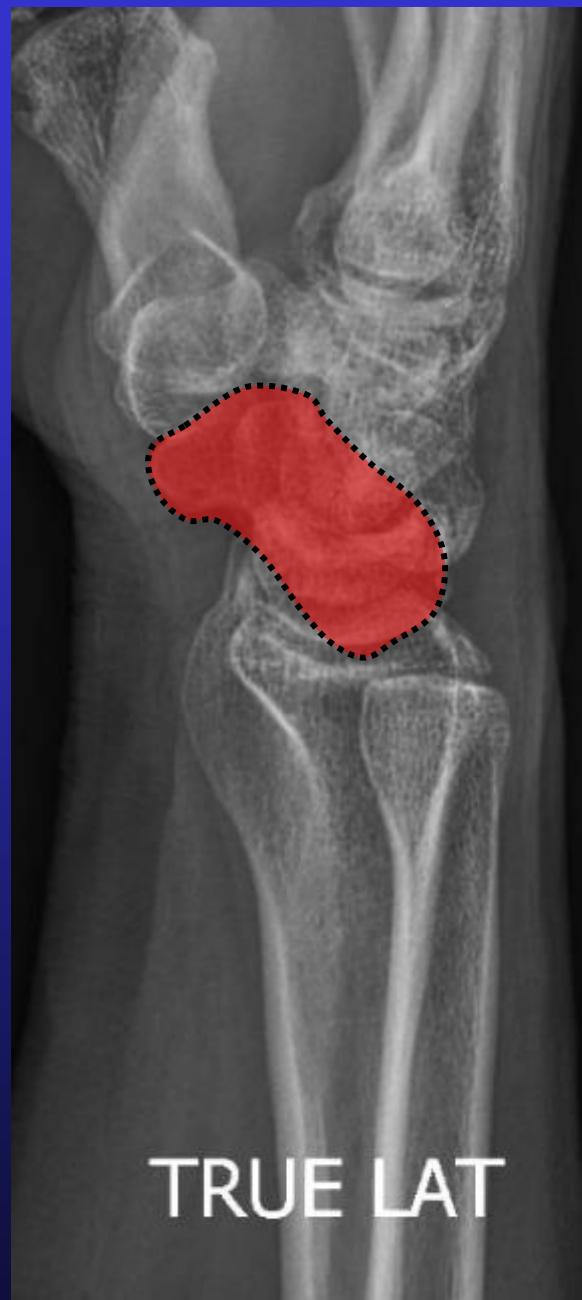


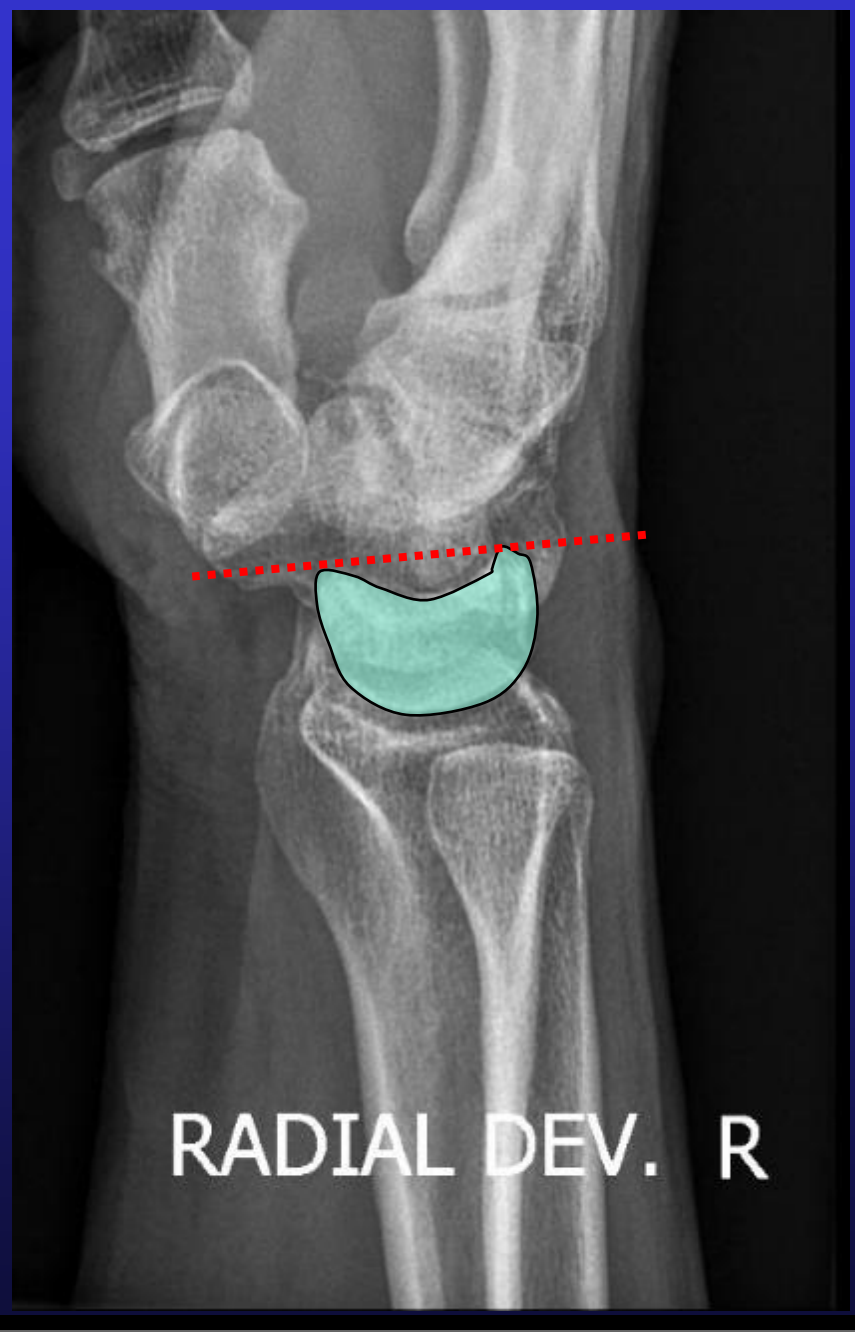
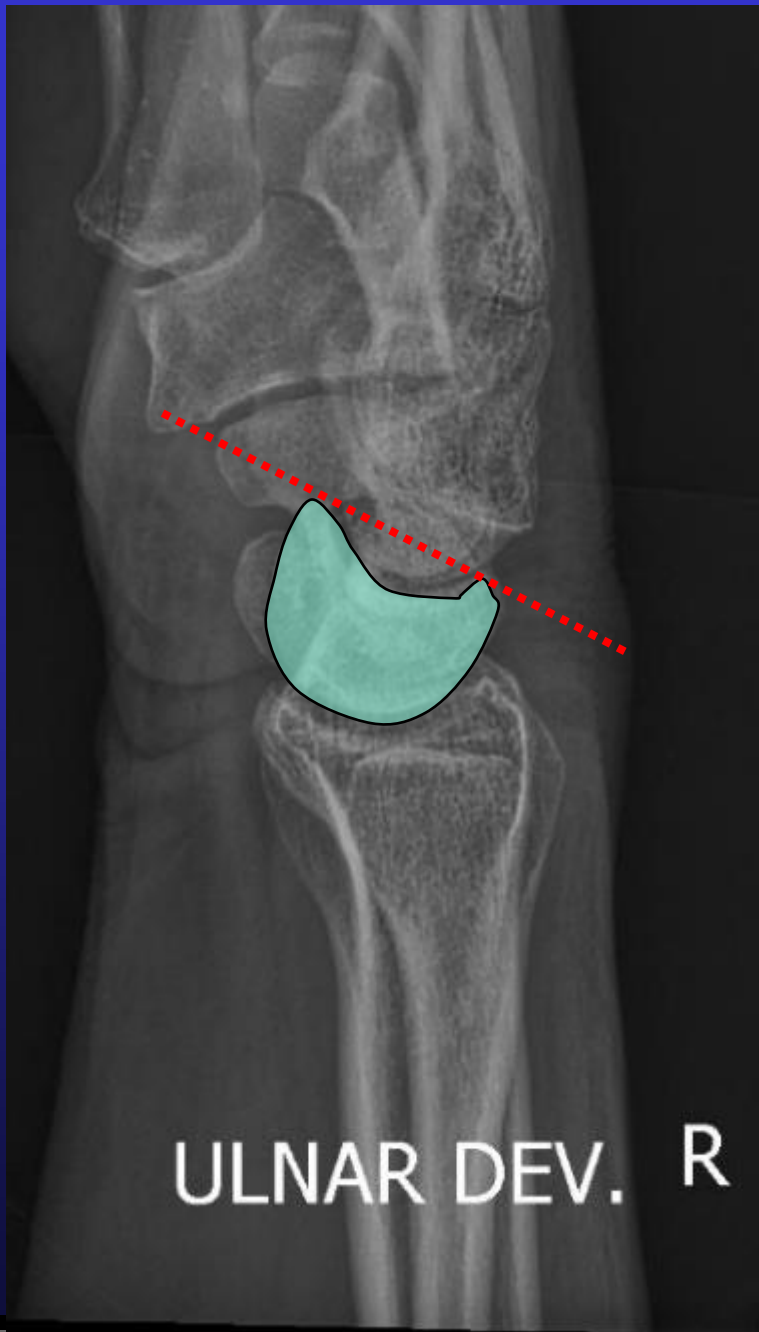


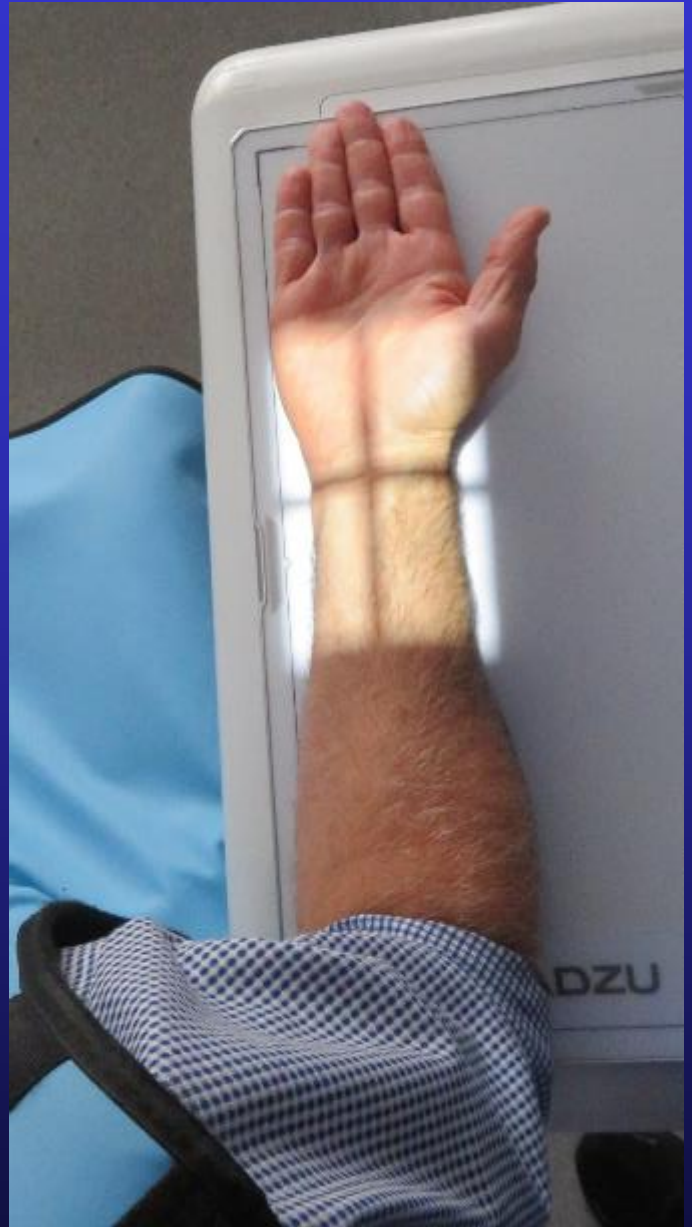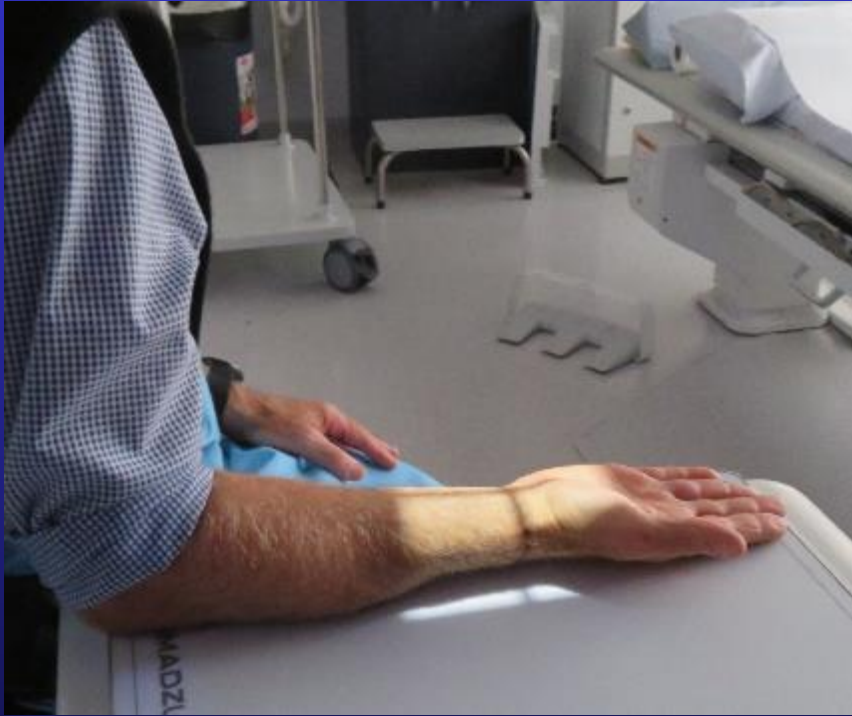RADIAL DEV. R

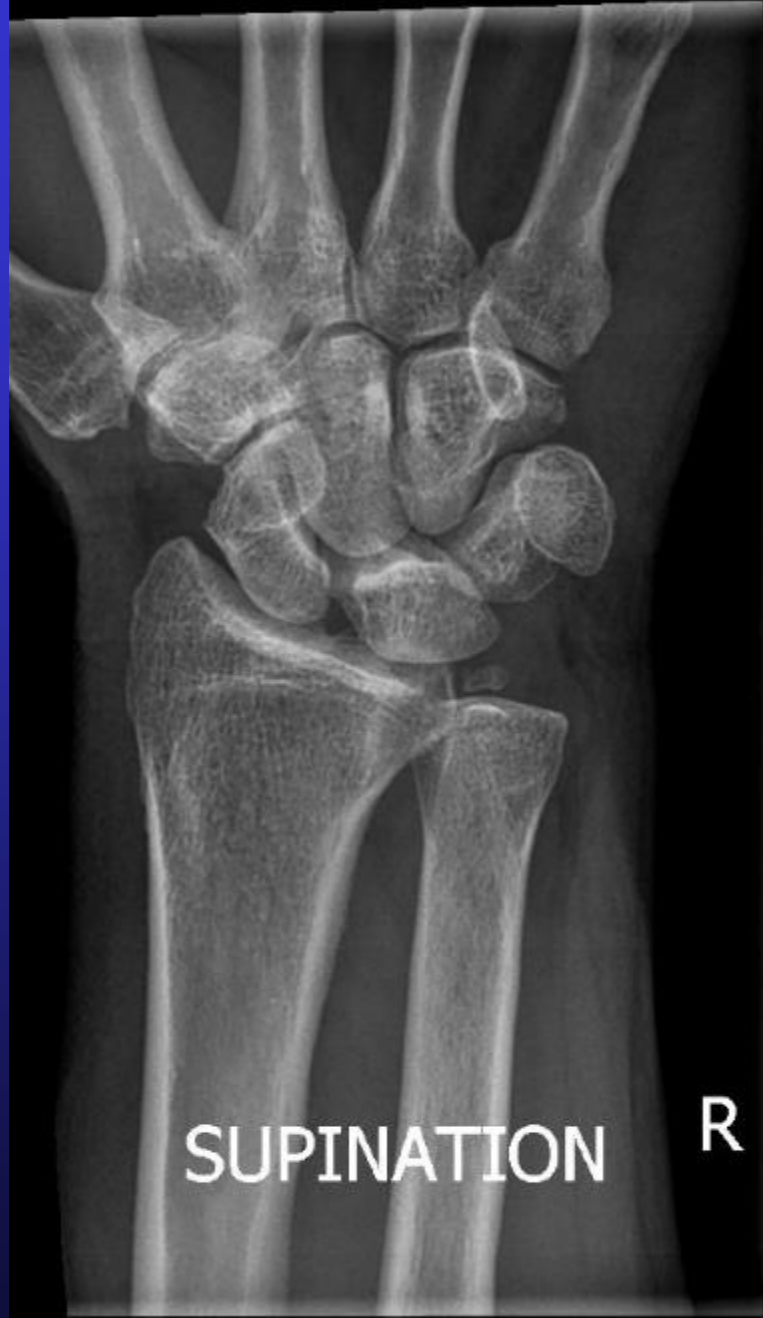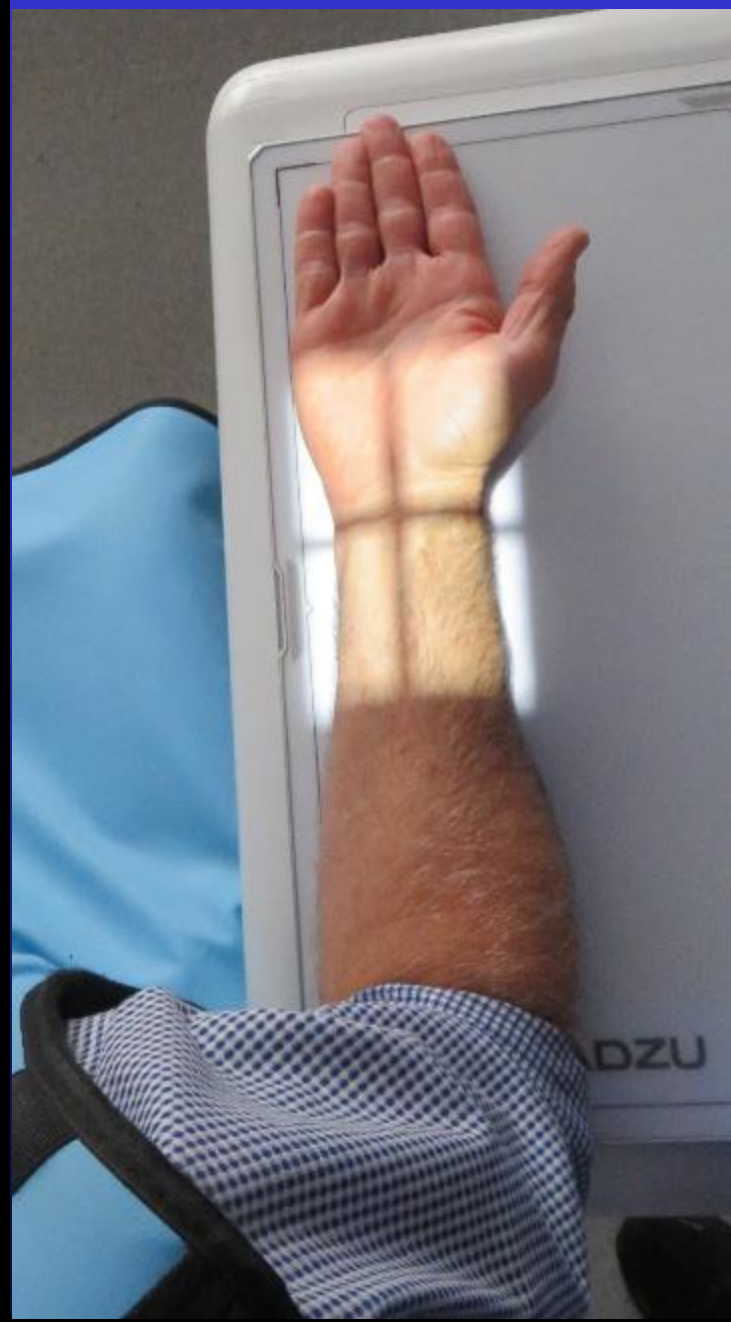



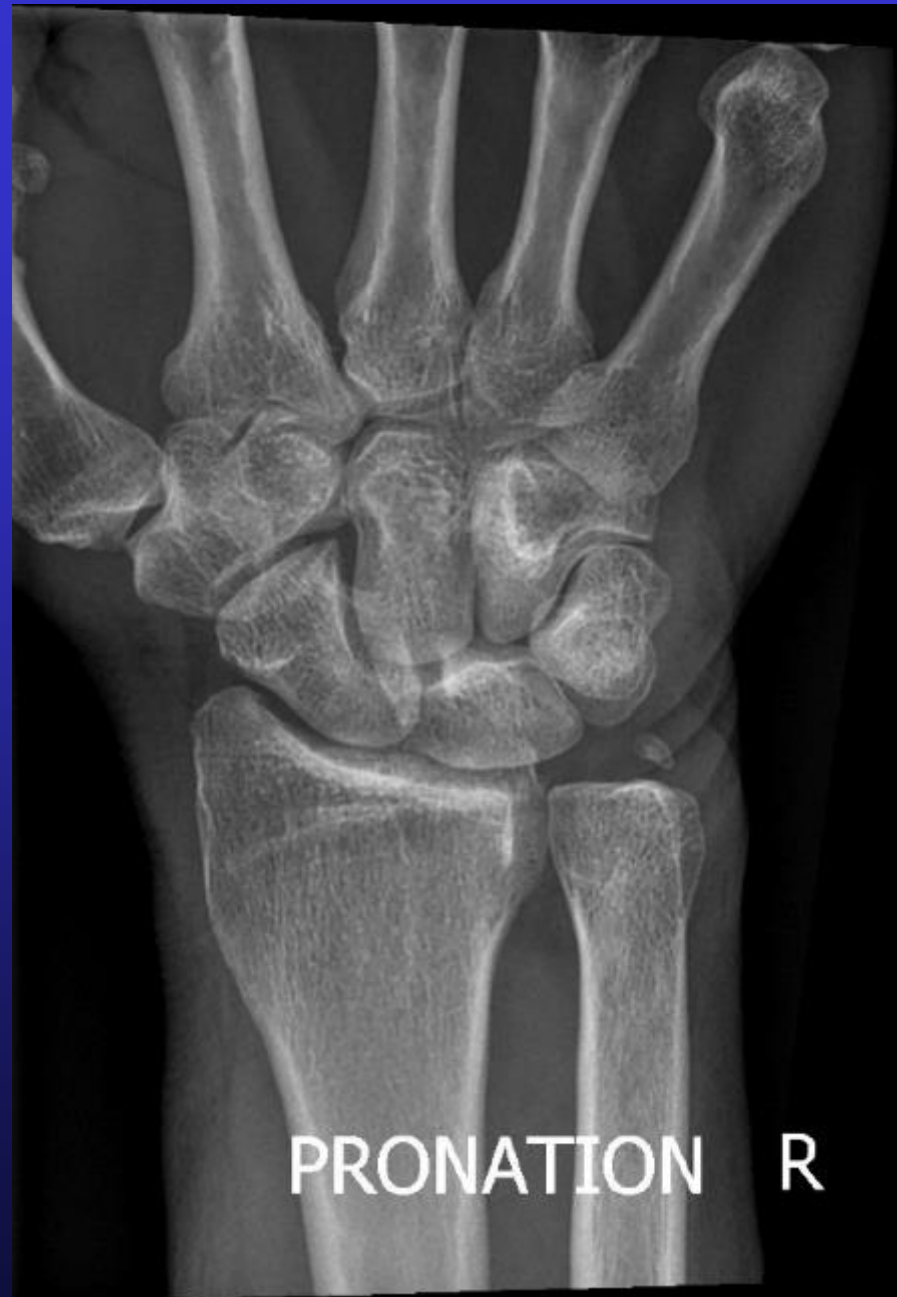
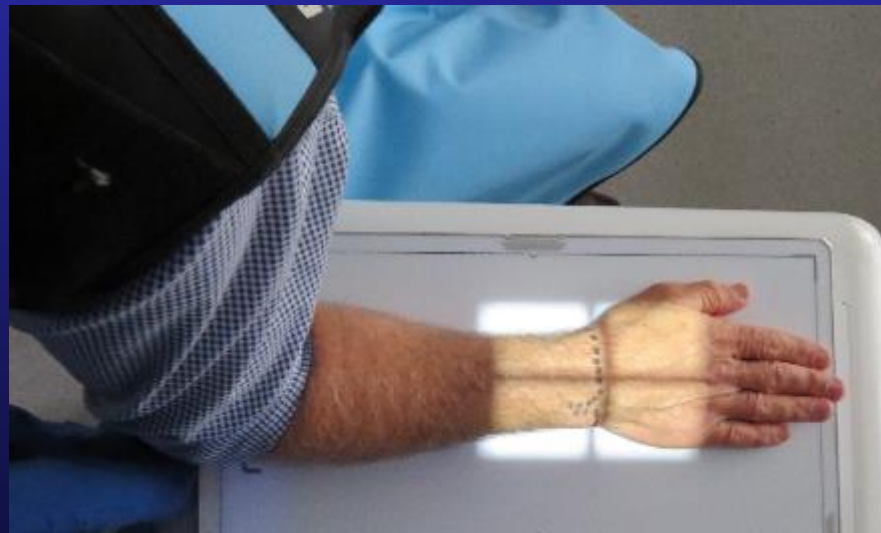
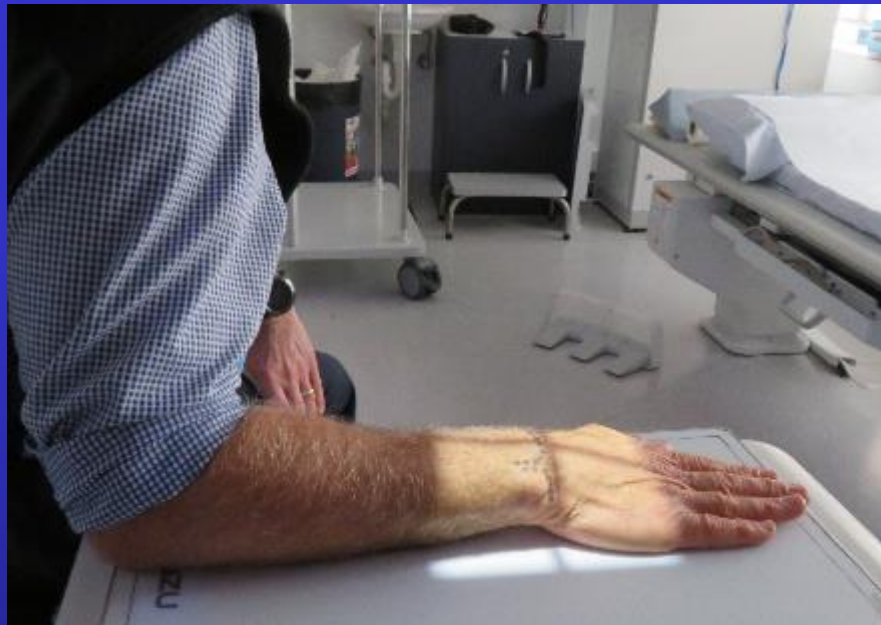




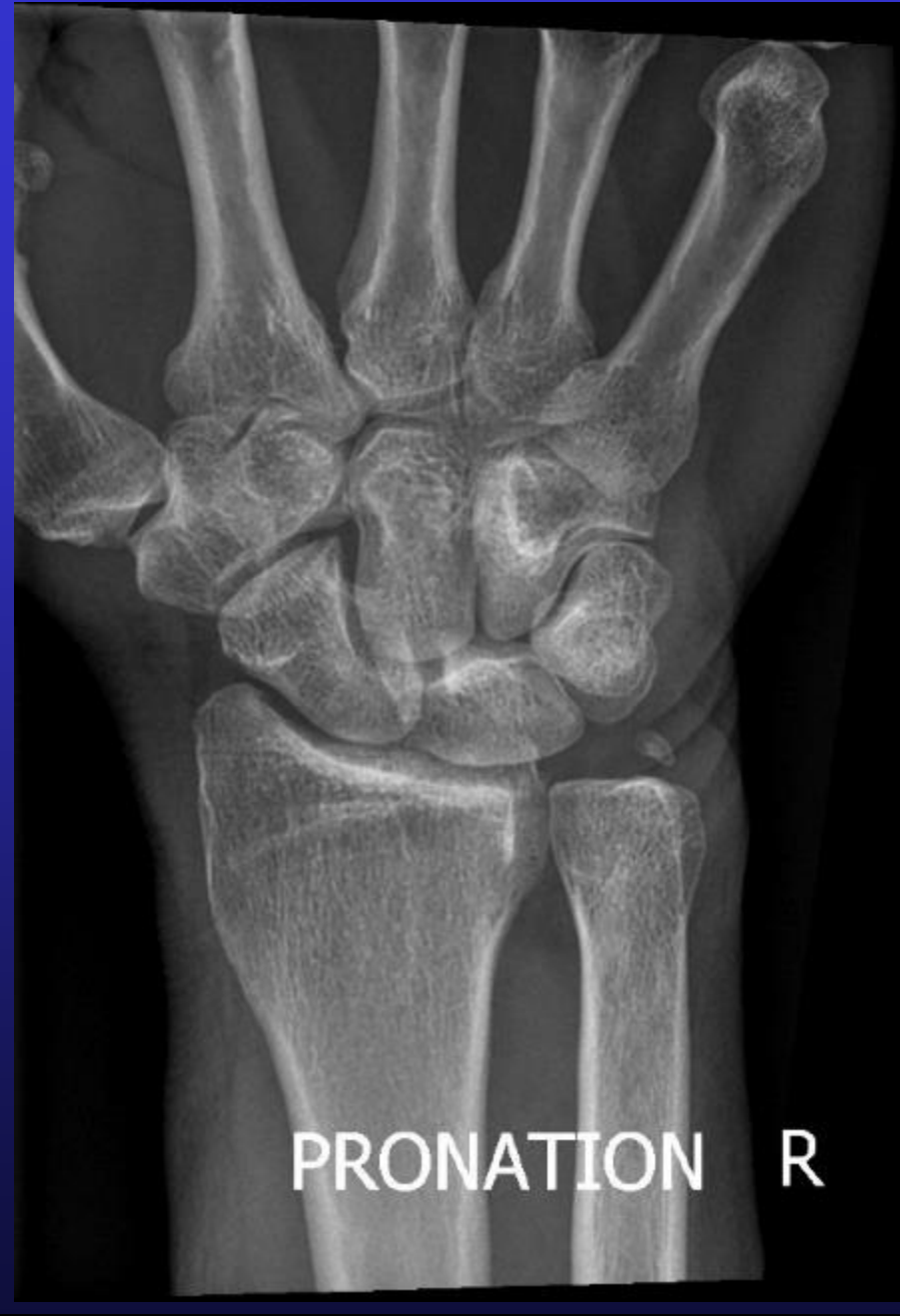
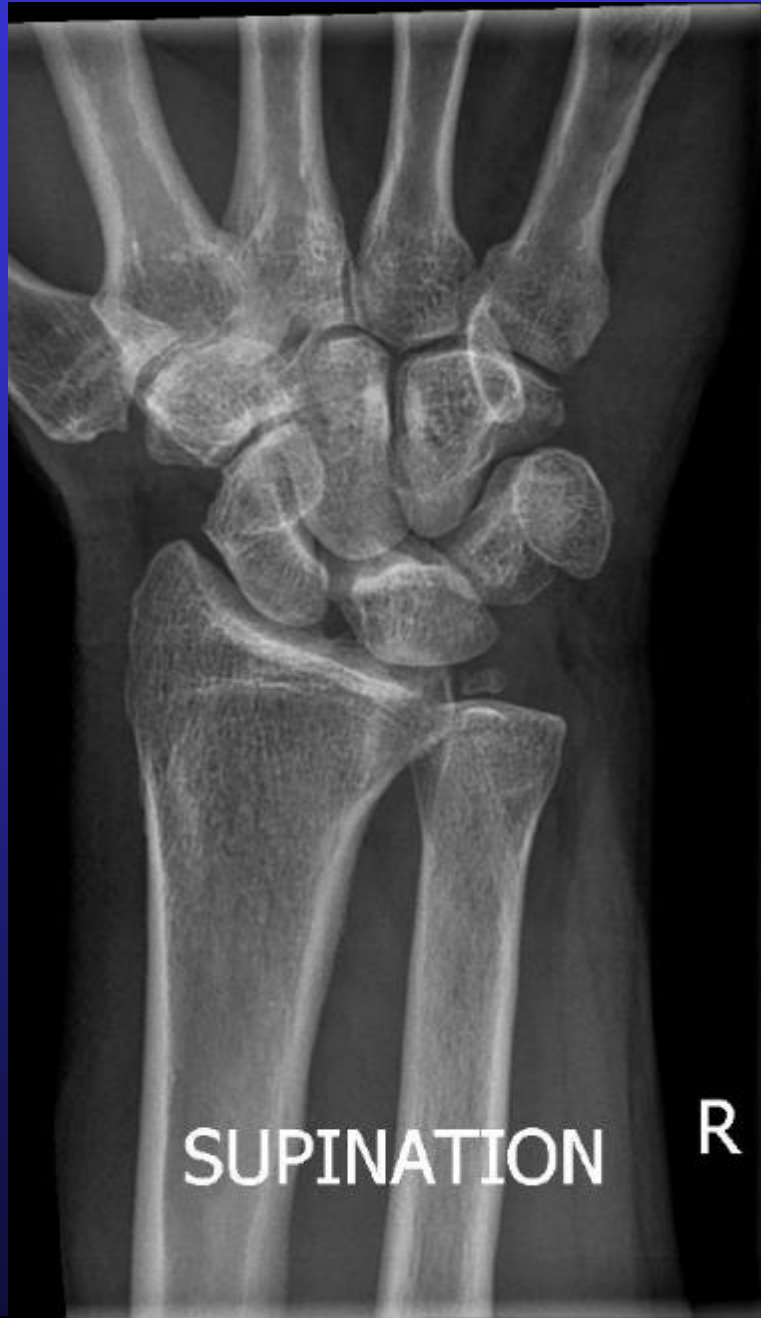


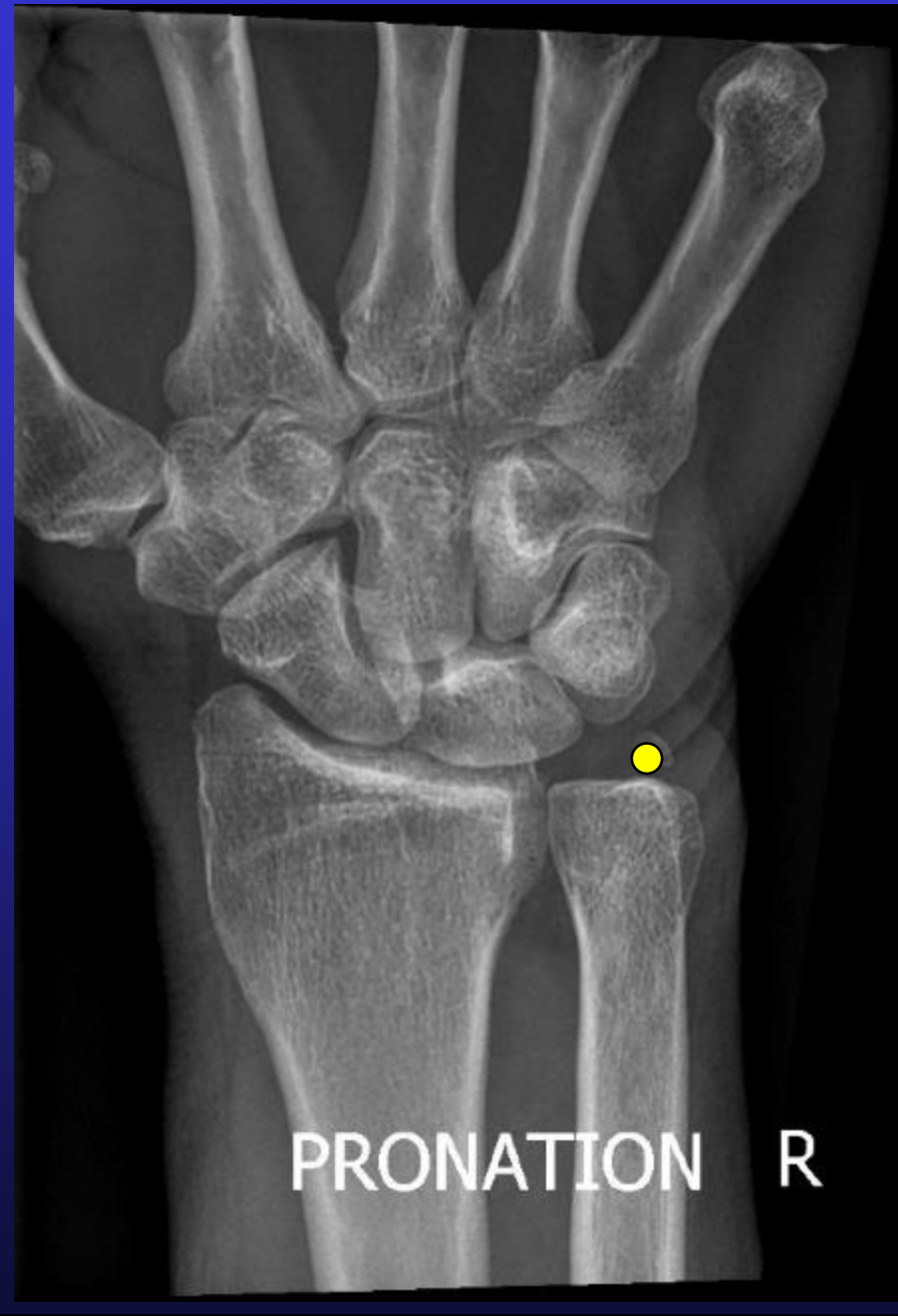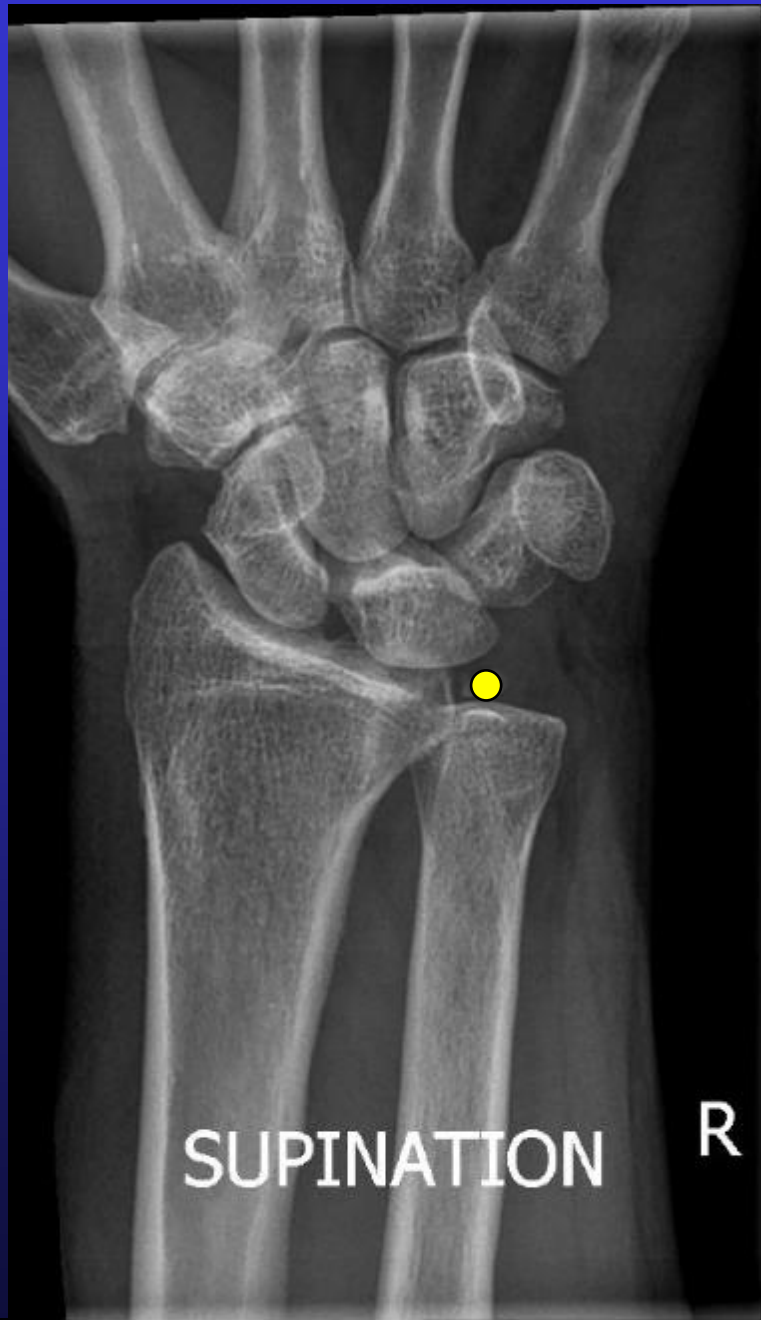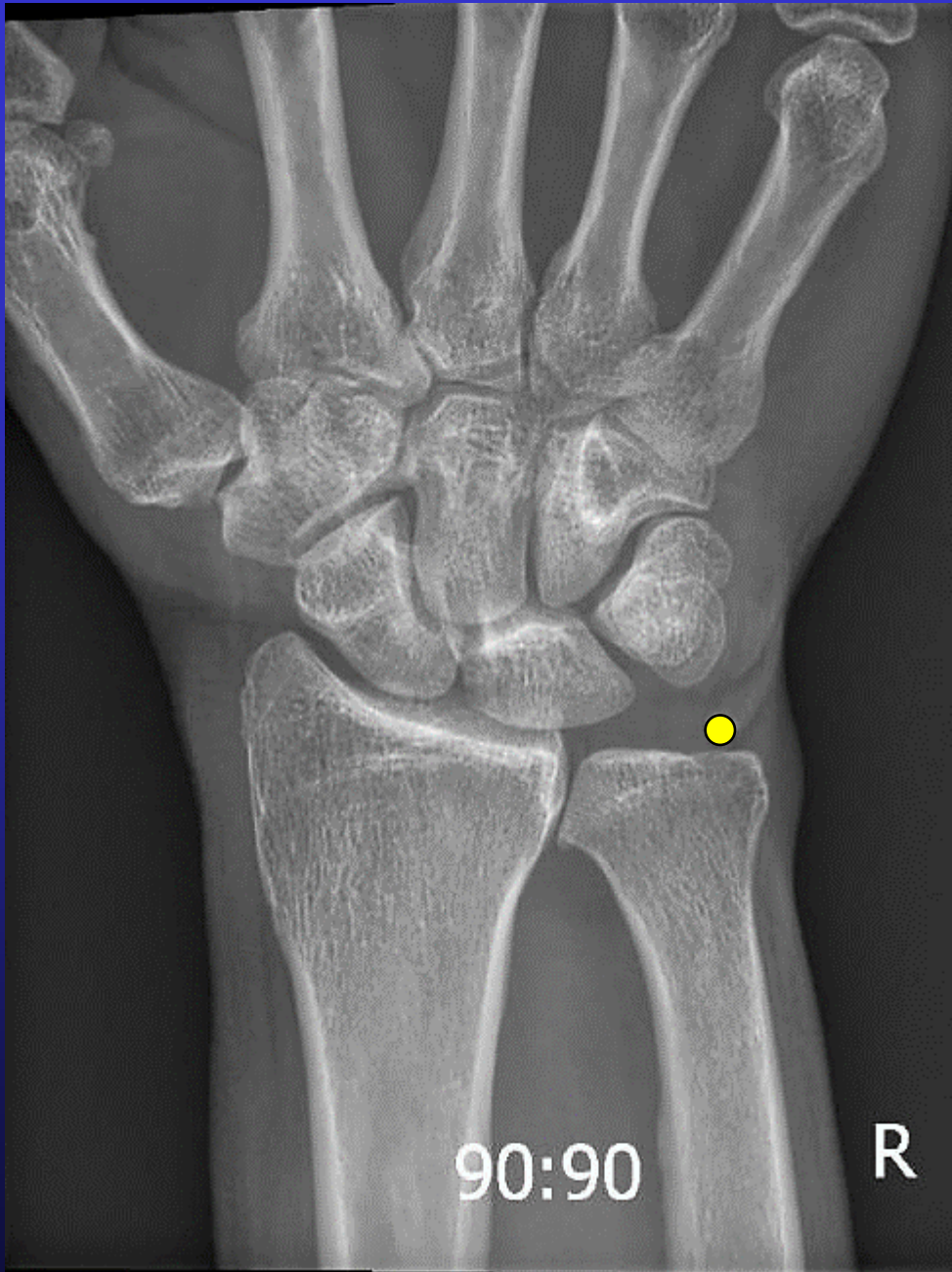PRONATION R







R

90:90