

Pisotriquetral Vxray Views

Dr Stuart Myers

Orthopaedic Hand Surgeon,
Prince of Wales Hospital, Sydney
Sydney Orthopaedic Specialists

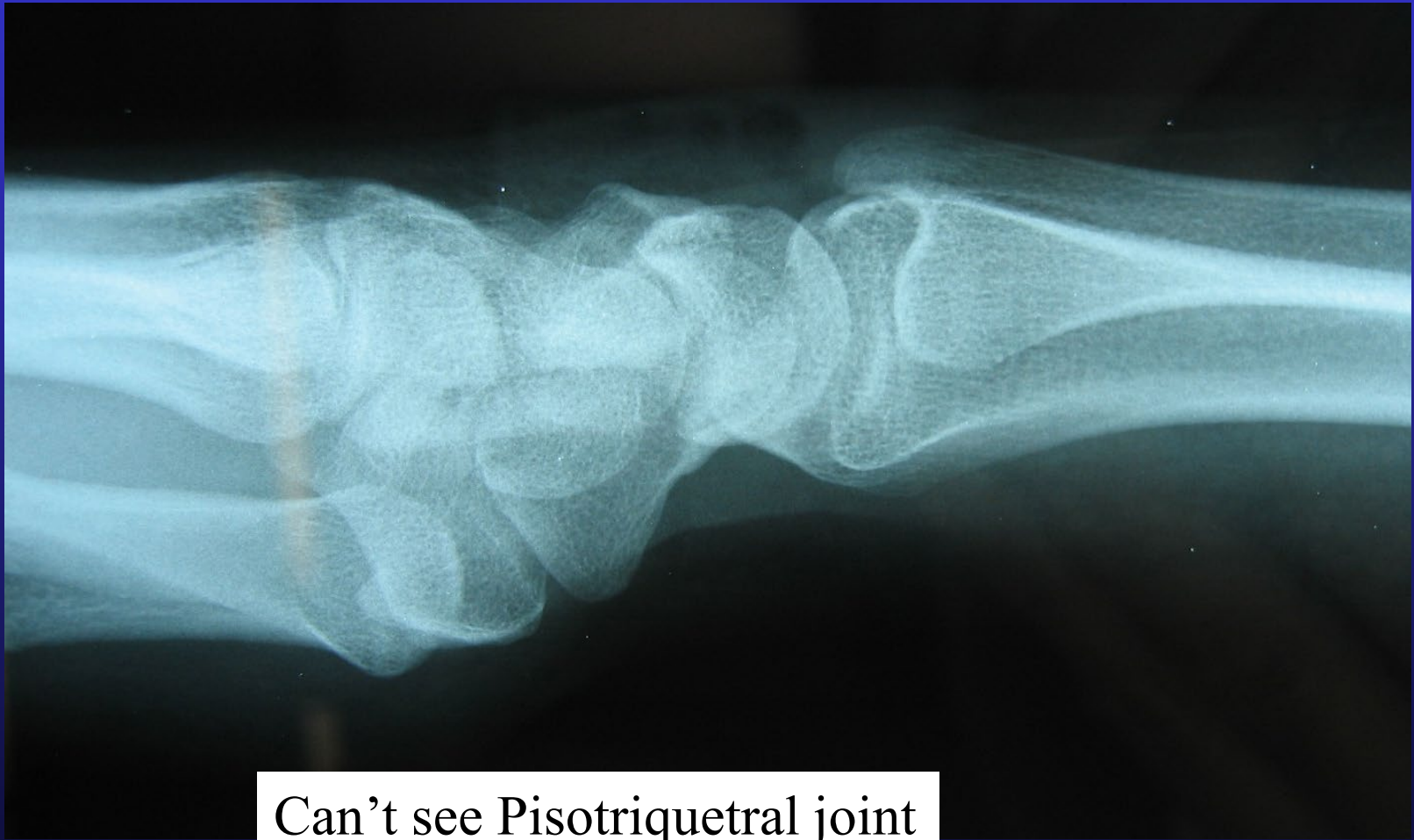www.myhand.com.au



Reason for Xray?????

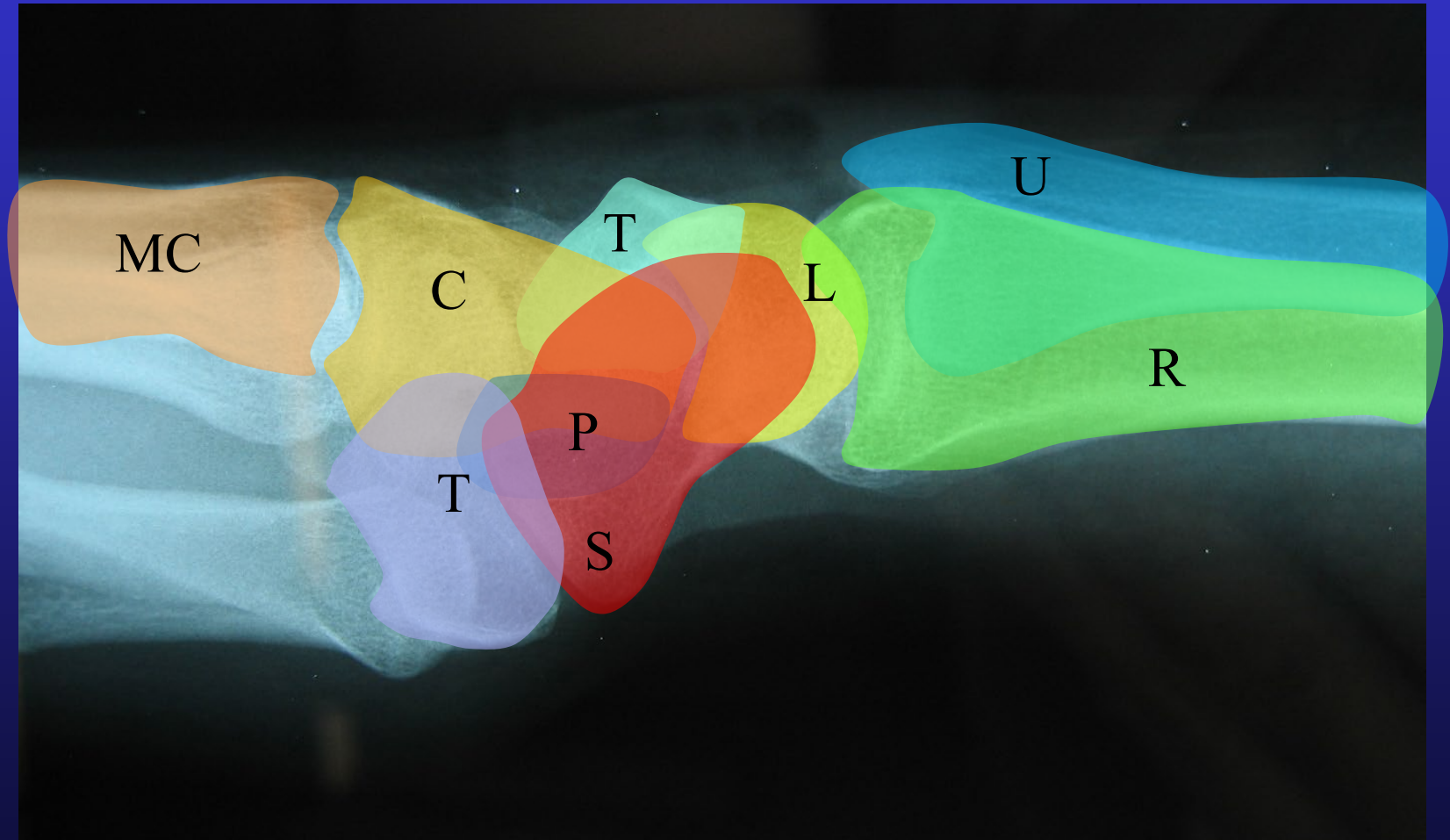
- Pisotriquetral arthritis
- Pisiform Fractures

Lateral Views

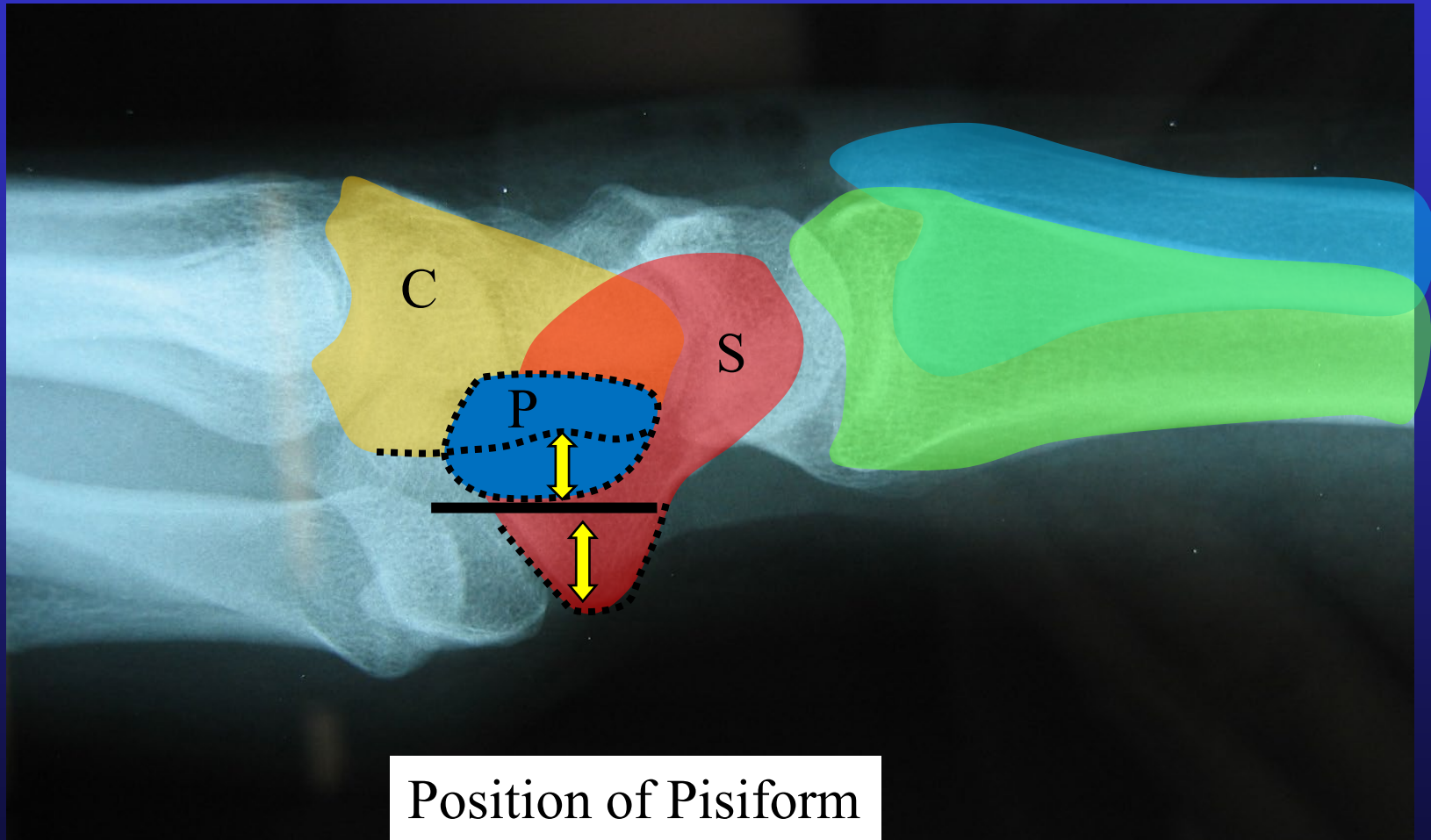


Can't see Pisotriquetral joint

Carpal bones

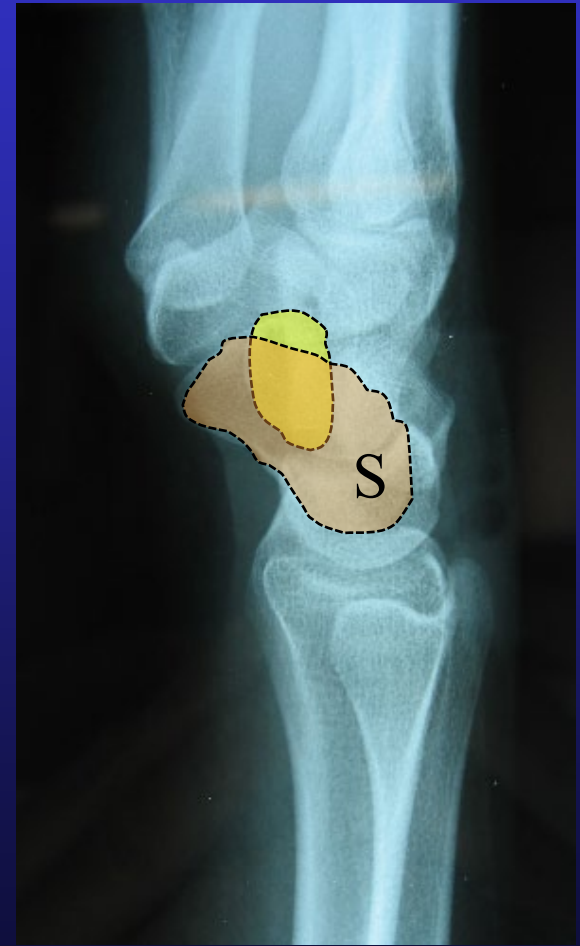
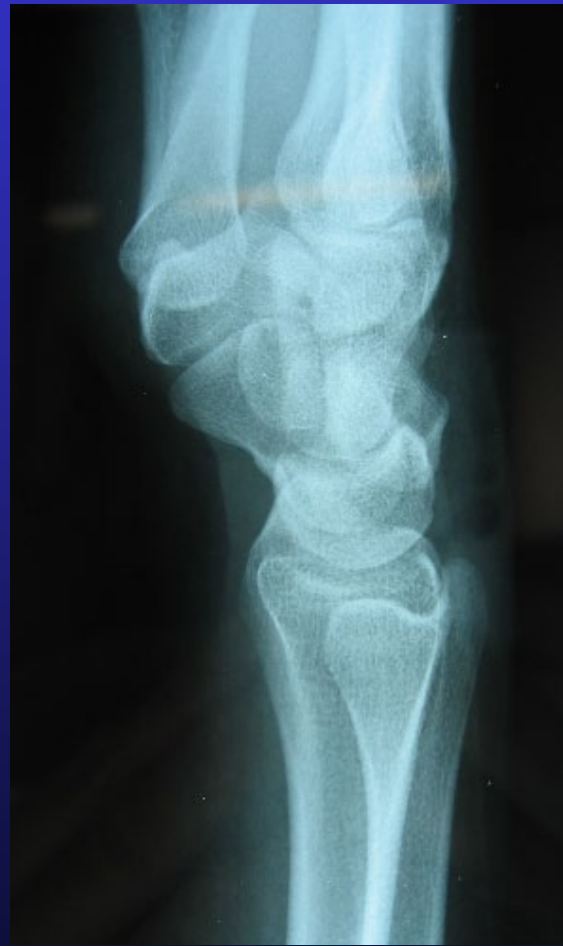
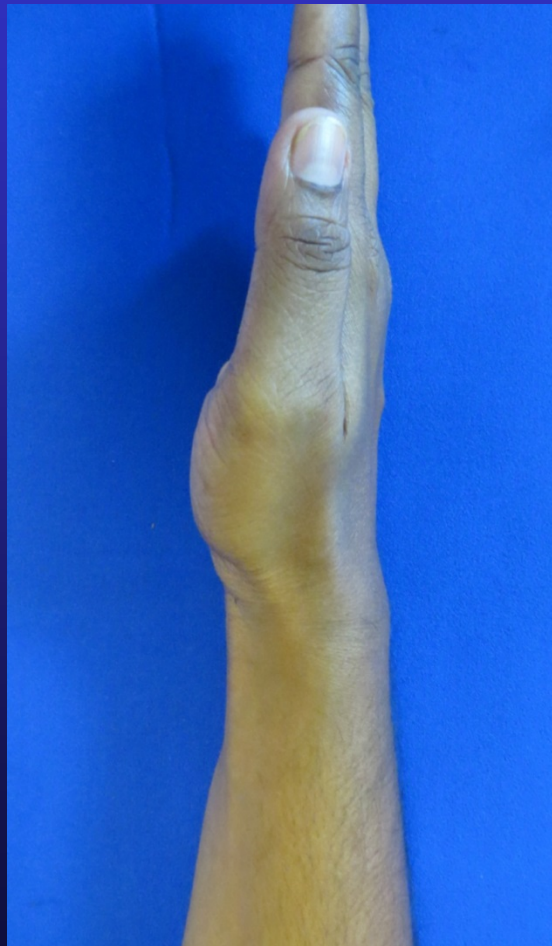“True Lateral”

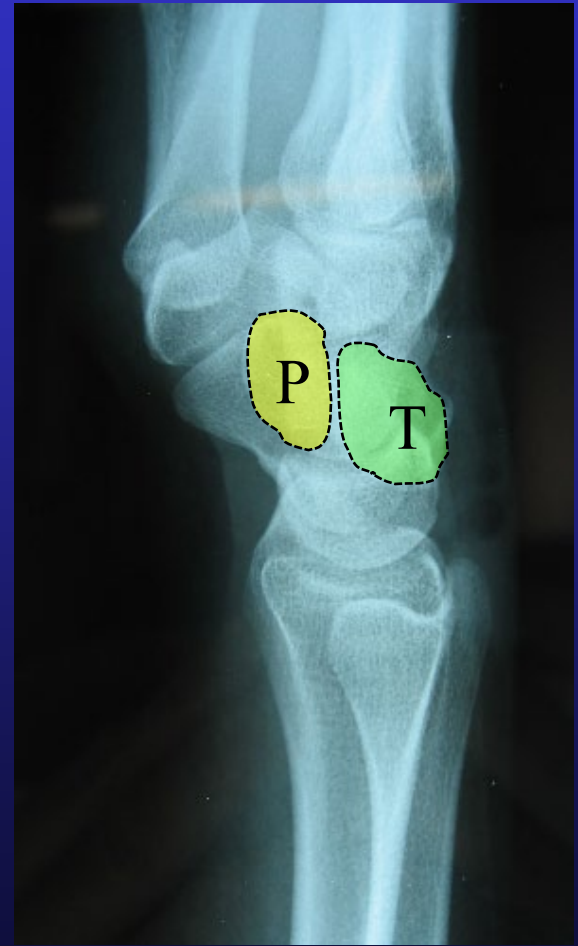

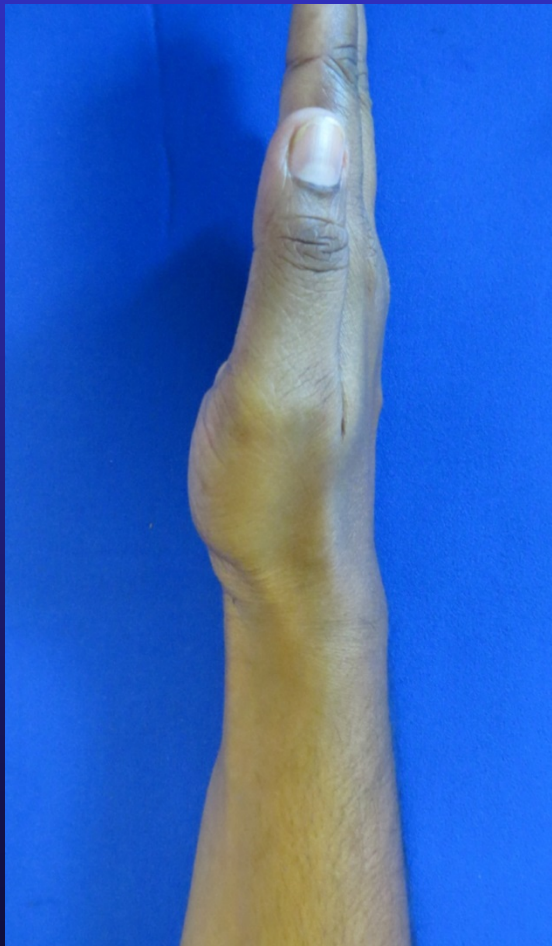Position of Pisiform

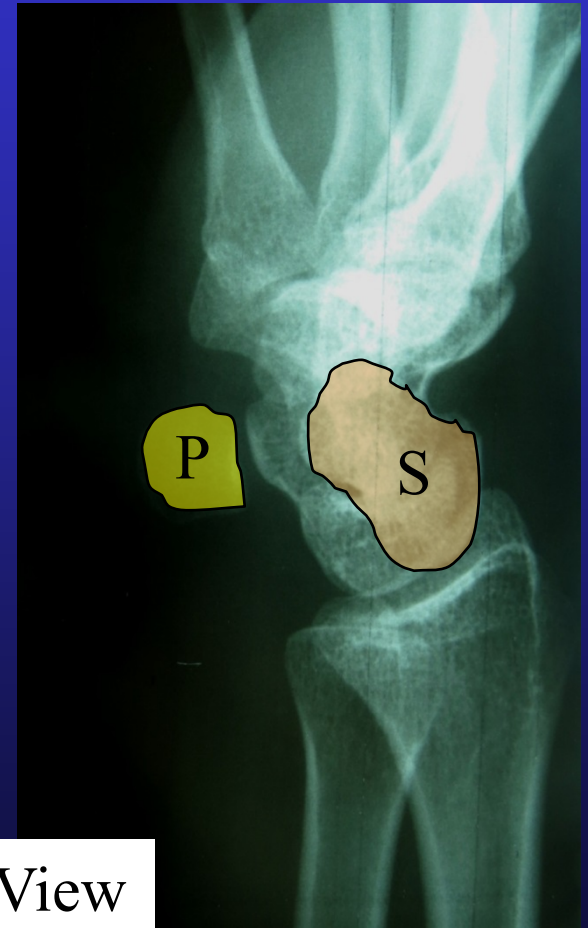
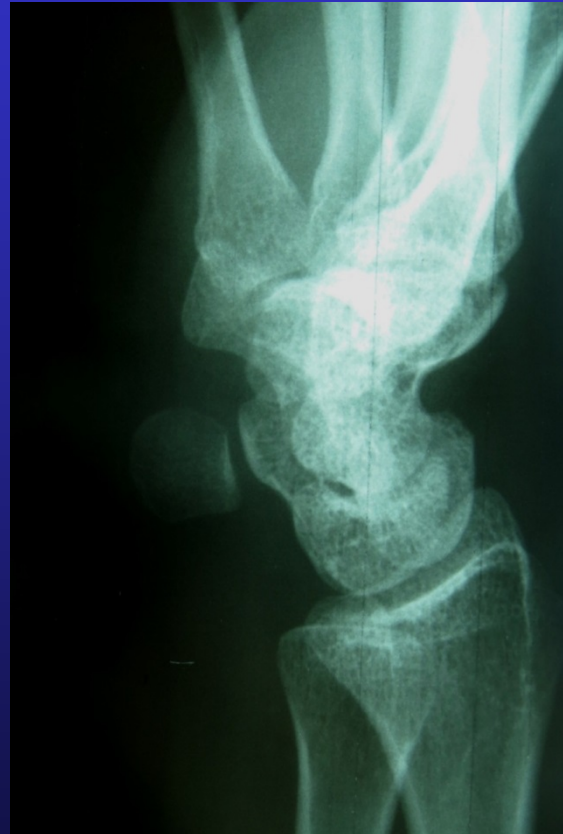
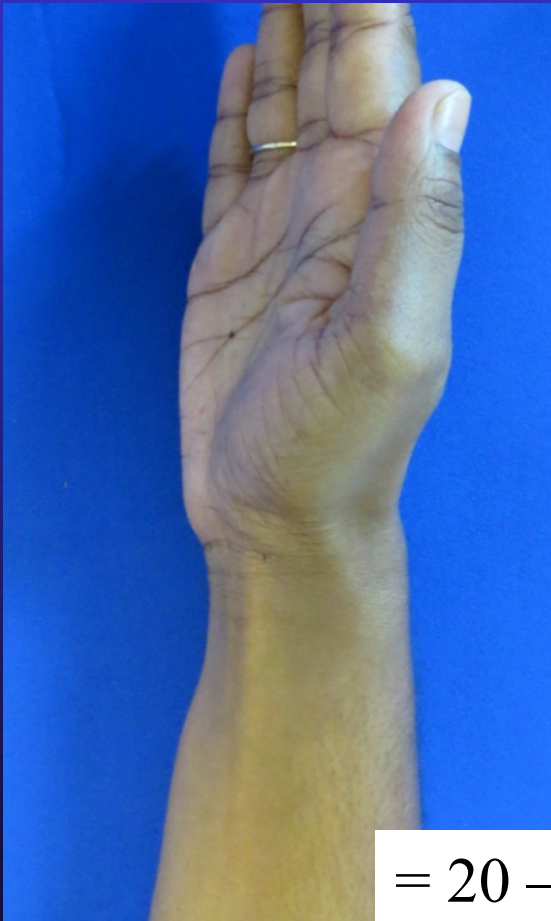Piso-Triquetral Views



Piso-Triquetral Views

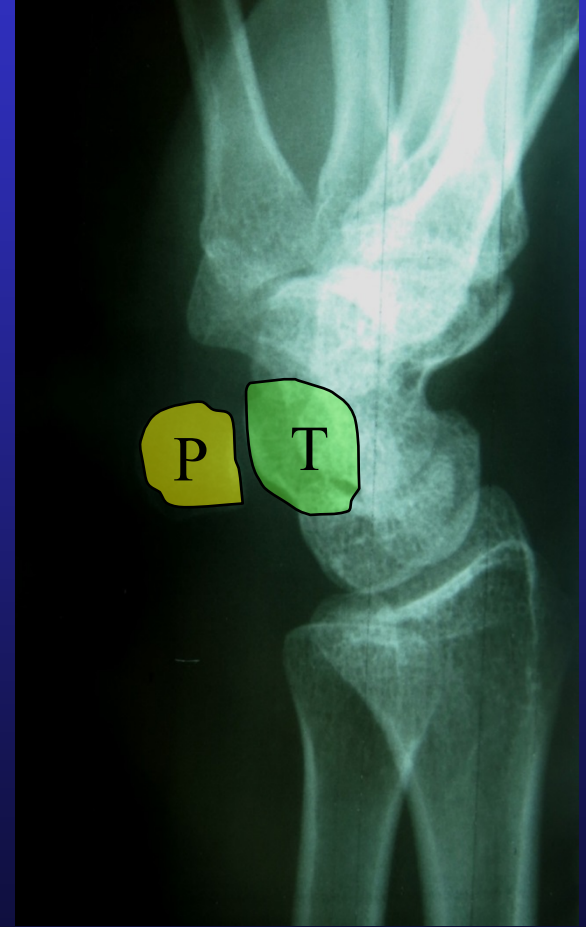
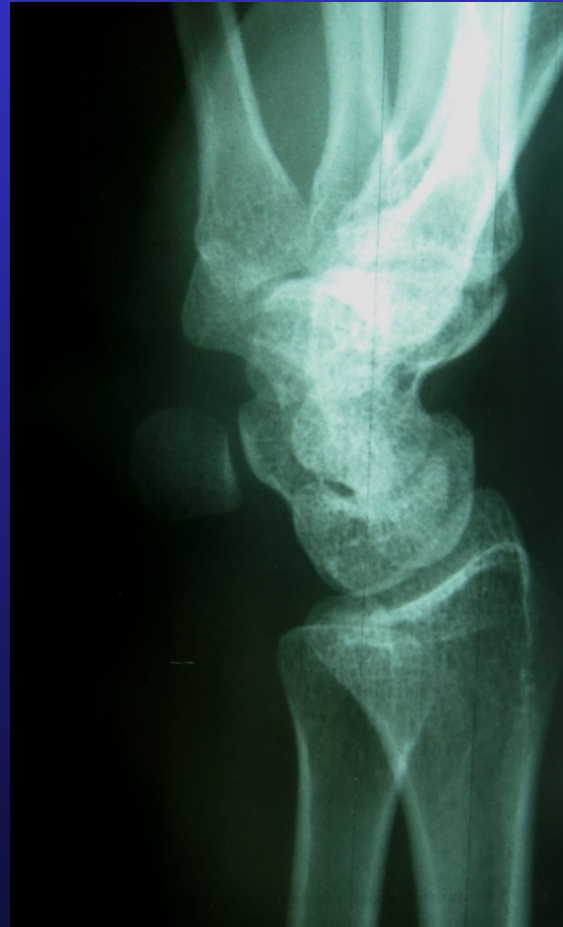
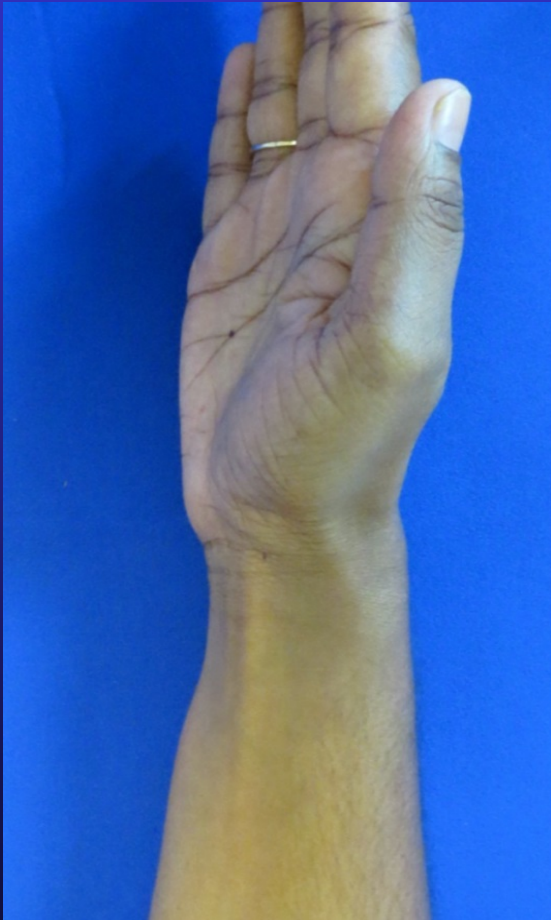

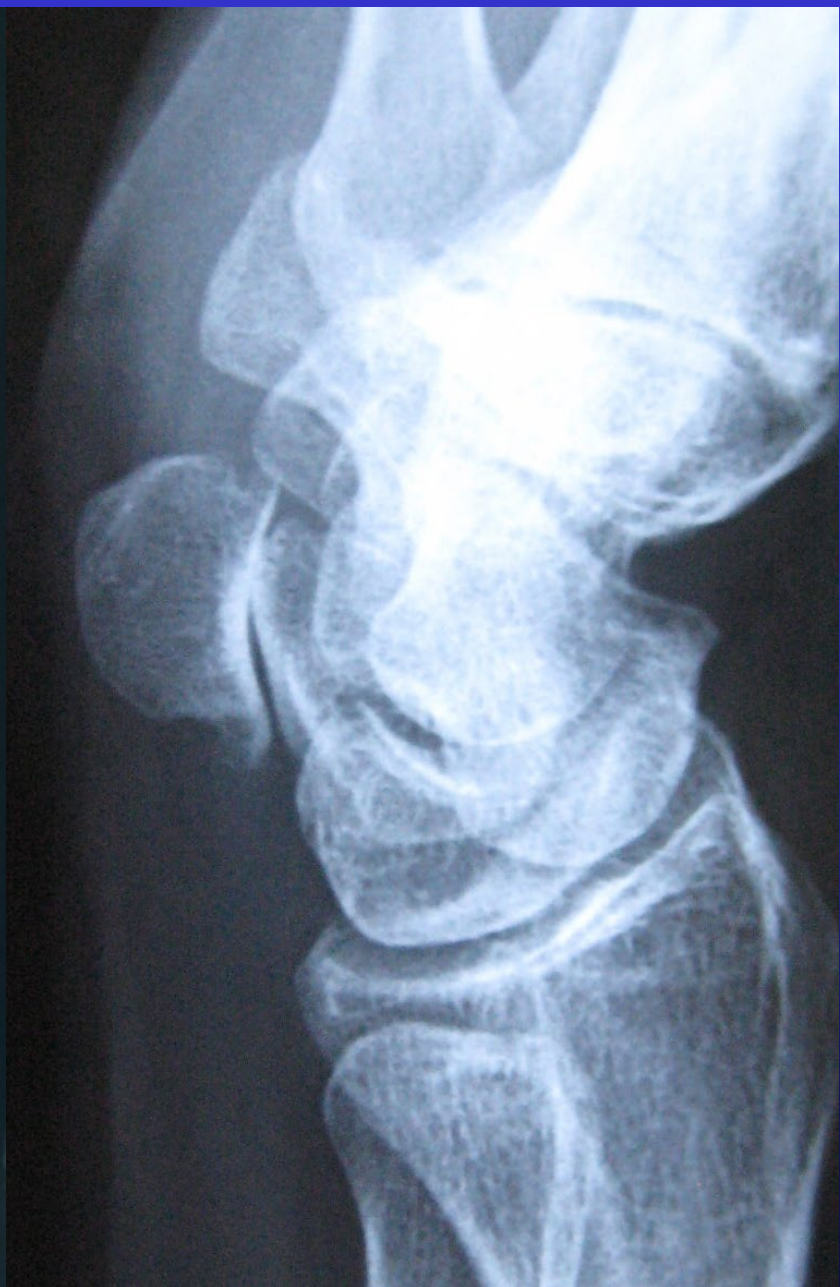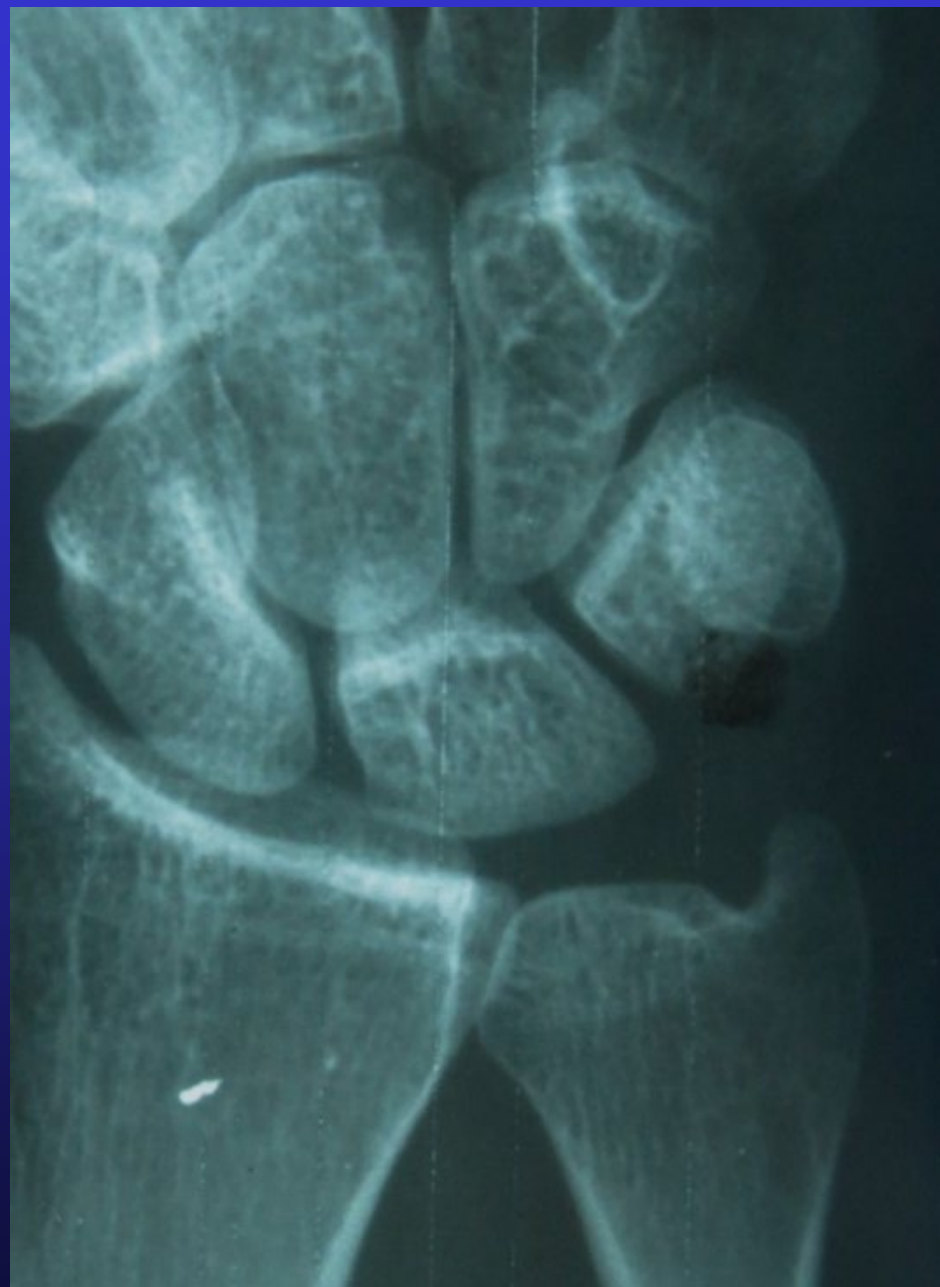
Piso-Triquetral Views

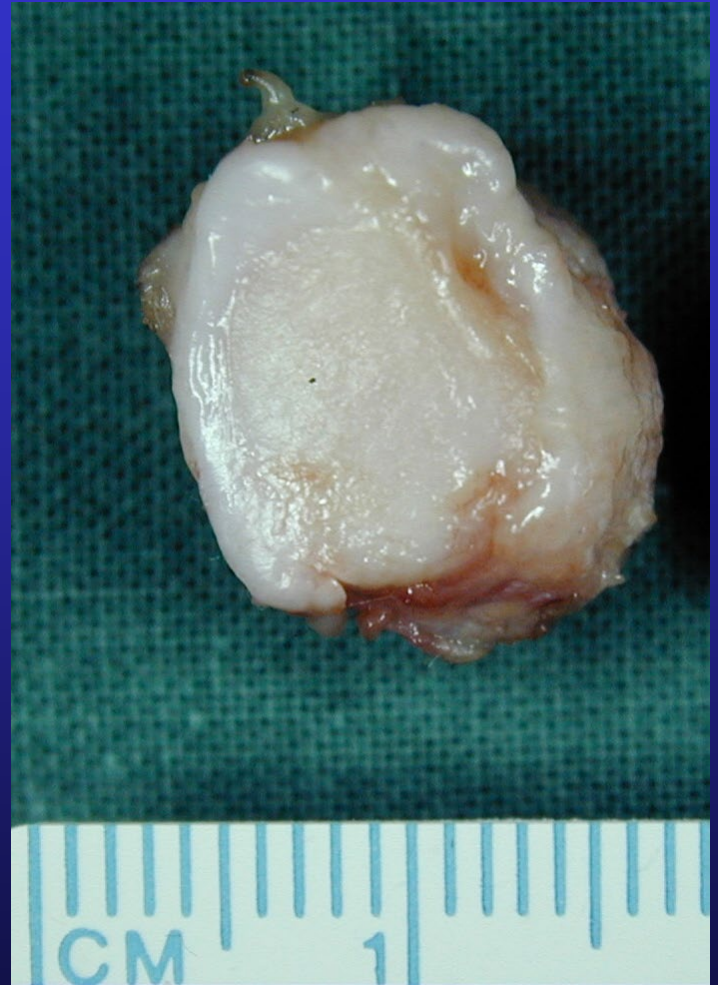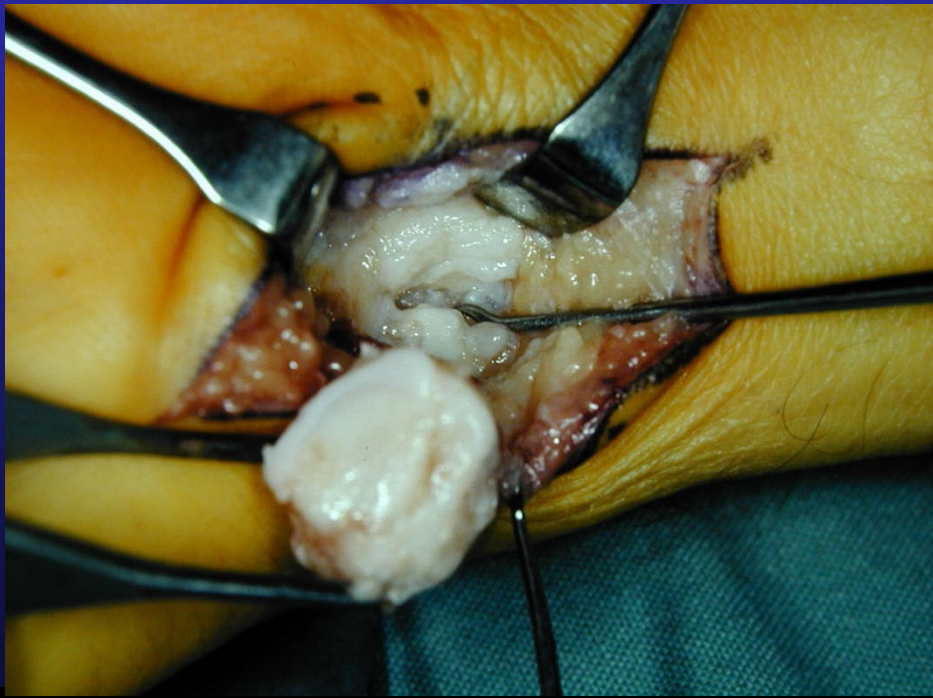

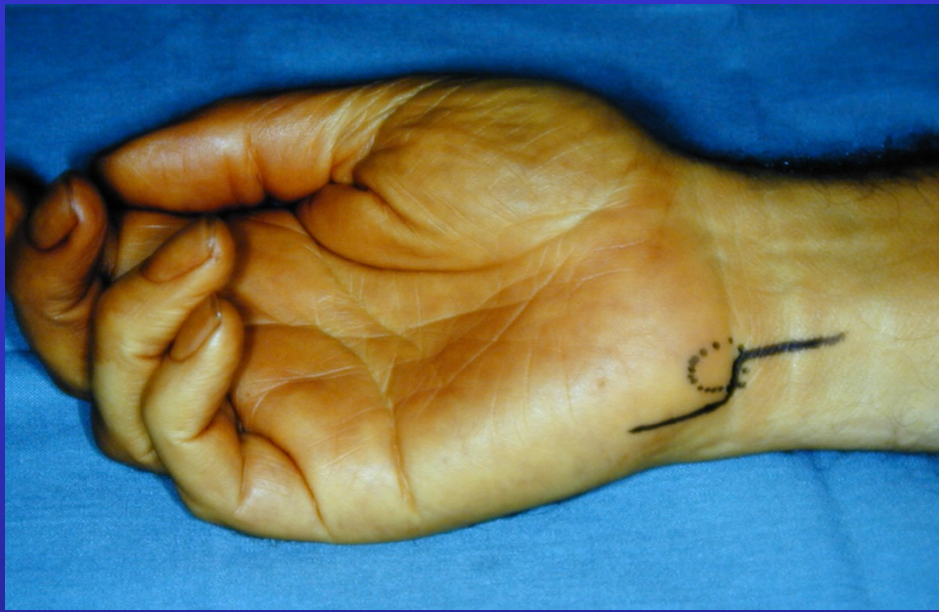
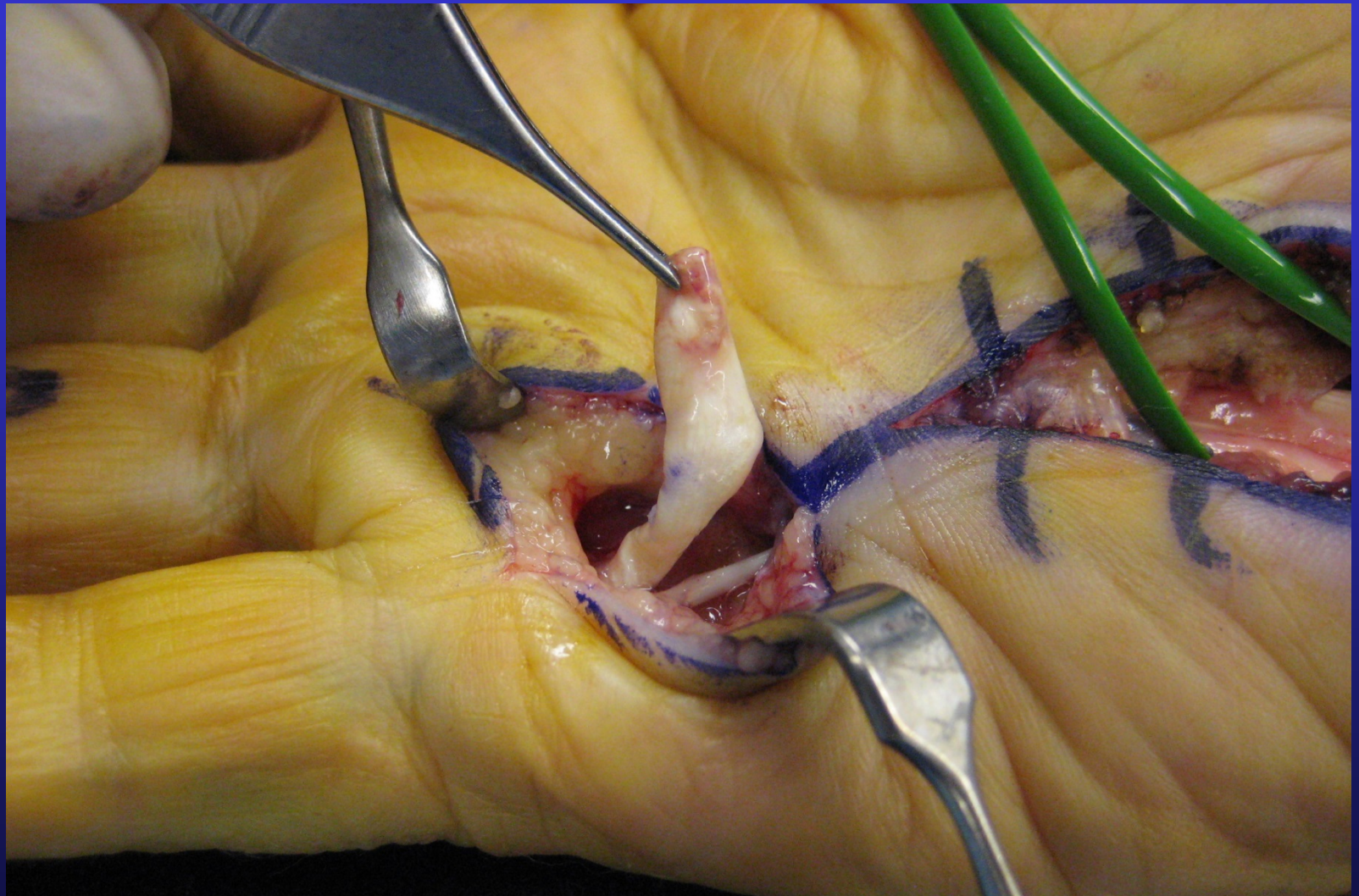
= 20 – 30* Supinated Lateral View

Piso-Triquetral Views









Spurs from Pisotriquetral arthritis cause Flexor tendon rupture